

Practical aspects of MRI of the prostate

Dragoş Cuzino¹, Oana M. Baston¹, Cătălin Blaj¹

Abstract: *The article presents the main aspects of sectional anatomy, lymph nodes and adjacent structures as well as MRI examination standard protocol for prostate cancer diagnosis. Using MRI multiparametric examination we succeed in classifying efficiently the malignant prostatic tumors using PI- RADS system.*

Also, using MRI multiparametric examination we can evaluate the effectiveness of prostate cancer treatment.

Keywords: *multiparametric MRI, prostate cancer, PIRADS, PSA, benign hypertrophic hyperplasia (BPH)*

ANATOMY OF THE PROSTATE GLAND

The prostate gland is the largest male accessory reproductive gland. The prostate gland looks like a flattened cone or inverted pyramid. The base of the prostate is in continuity with the bladder.

It ends at the apex at the urogenital diaphragm. It typically weights between 20-40 grams. The prostate normal size is 3 x 4 x 2cm. The prostate is comprised of 70% glandular tissue and 30% fibromuscular or stromal tissue. The prostate has four zones. The peripheral zone is located under the capsule and formed of glandular tissue. The central zone is deep to the peripheral zone and formed of stroma. The transitional zone surrounds the prostatic urethra.

The periureteral zone is formed of short ducts. The central and transitional zones are found more superiorly within the gland. The gland tapers inferiorly.

The central gland located anterior and superior, is the portion of the prostate most intimate to the urethra.

The peripheral gland comprises the posterior and inferior parts of the prostate. It is statistically proved that most of the cancers of the prostate are located in the peripheral gland, but cancer can occur in the central gland also. The cranial part of the gland is called the base and the more caudal portion is called the apex. (1)

Considering prostate a flattened cone, the tip of the cone represents the apex of the gland and is situated more caudally. The flattened portion of the cone is analogous to the base of the prostate and is situated more cranially. In young men, the peripheral zone occupies approximately 70% of the total volume of the prostate, the central part 24% and the transitional zone about 5% but the percentage is changing with age. (2) Using MRI we manage to see the described zonal anatomy with the four zones of the prostate. On CT we can do it only on occasion. (2)

¹ Carol Davila Central University Emergency Military Hospital, Bucharest

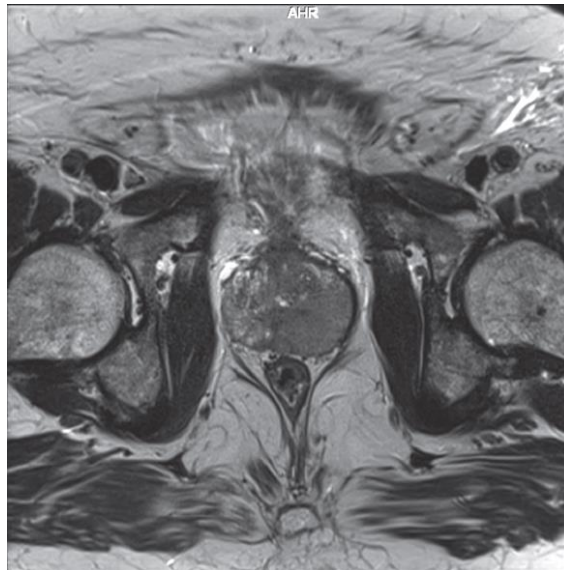In T2 we may see the peripheral zone with high signal intensity and the transitional zone with low signal intensity. In T1 we can assess to demonstrate areas of post-biopsy hemorrhage and the status of the neurovascular bundles.

The prostate capsule appears as a continuous dark

area around the prostate in T2. The DWI sequence may show restricted diffusion in prostate cancer.

T1 Dynamic contrast/DCE sequence could show enhancement but it is unsepcific because it may be difficult to distinguish from prostatitis or benign prostatic hyperplasia.

Figure 1. Axial T2 TSE high resolution. Peripheral lesion with intermediary irregular zone located inferior and posterior in the left zone.



LYMPH NODES

In assessing prostate anatomy it is very important to evaluate the lymphatic drainage. The main lymph nodes are obturator and internal iliac; secondary, the drainage is made into the external iliac, presacral and para-aortic nodes.

The lymphatic spread of the disease is unspecific and only the evaluation of the lymph nodes dimensions is a value indicator. The seminal vesicles appear with low signal intensity in T1 and high homogeneous intensity in T2.

The normal size of the prostate is compared with the one obtained when we measure the dimensions of the prostate, when we estimate the volume by multiplying antero-posterior, transverse and longitudinal measurements by one another and then multiplying that result by 0,52 which is $\pi/6$. The expected prostate volume increases with advancing age and a prostate with a volume greater than 40 ml is considered to be enlarged. The normal volume of

the prostate in milliliters is approximately equal to the weight of the prostate in grams. (2)

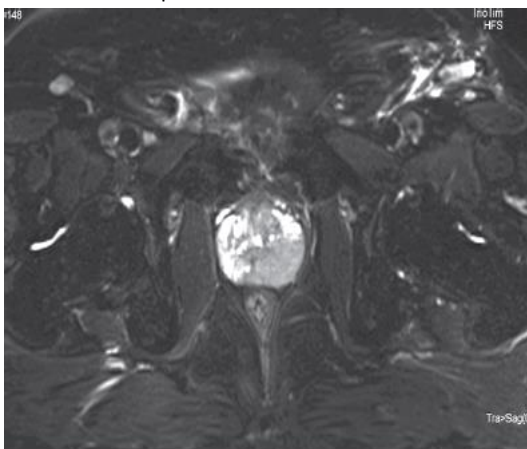
A normal PSA value is less than 4 and an abnormal value is greater than 10. Values vary between 4 and 10 which are considered boundaries.

Prostatitis, BPH, prostate infarcts and biopsy could cause elevated PSA levels.

Benign prostatic hyperplasia (BPH) usually starts in the transitional zone of the central gland and is more heterogeneous in T2 than the normal gland. When it grows, it can indent the bladder (1). Stromal BPH appears dark on T2 and glandular BPH appears bright. A low signal intensity rim may be seen surrounding these nodules. We see often a combination of these findings in BPH.

The diagnosis of prostate cancer is usually made by biopsy of the prostate which is often accomplished transrectally with ultrasound guidance.

Figure 2. Axial STIR. The zone is located subcapsular posterior and inferior.



The percentage of the prostate cancer arising within each of the three zones is: peripheral zone 70%, central zone 10% and transitional zone 20%.

Most of prostate cancers are adenocarcinomas which develop from the acini of the prostatic ducts. Pathologic specimens are graded using the Gleason score which is the sum of the most prevalent and second most prevalent types of dysplasia, each on a scale of 1 to 5, with 5 being the most dysplastic.

We also use a TNM staging system for classification of the prostate cancer and also the PI-RADS system (Prostate Imaging Reporting and Data System).

Figure 4. T1 axial FSE post-contrast examination. The lesion has unhomogenous enhancement.

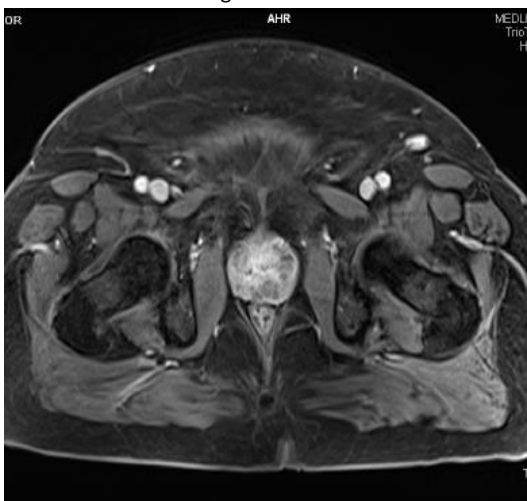
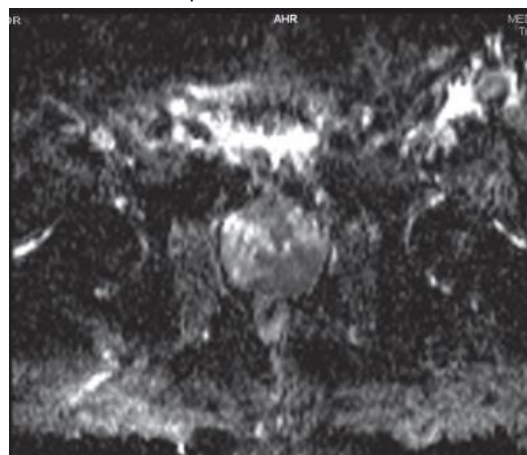


Figure 3. Axial DWI. Area of restriction of diffusion located inferior posterior on the left side.



There is no consensus about the use of imaging for evaluating prostate cancer. MRI is the method of choice for local staging, to demonstrate tumor location, extracapsular extension and seminal vesicle invasion. The most efficient method for evaluating prostate tumor and the aggressiveness of the tumor is multiparametric MRI.

Biopsy is essential for the diagnosis. MRI should be performed about 3 weeks after biopsy because at that time about 50% of patients have residual hemorrhage. Hemorrhage after about 3 weeks post biopsy is different from tumour to tumour. T1 hypertintense and T2 hypointense areas correspond to postbiopsy hemorrhage and T1 – izointense and T2 hyperintense areas are more likely to correspond with tumour. There is also disruption of the prostate capsule which may mimic the invasion into the prostatic fat.

Figure 5. Axial T2. Benign prostate hypertrophy and a prominent nodule.

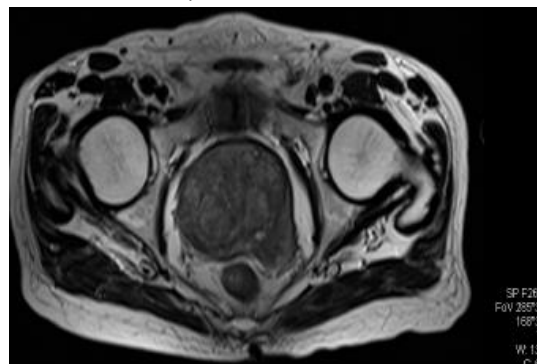
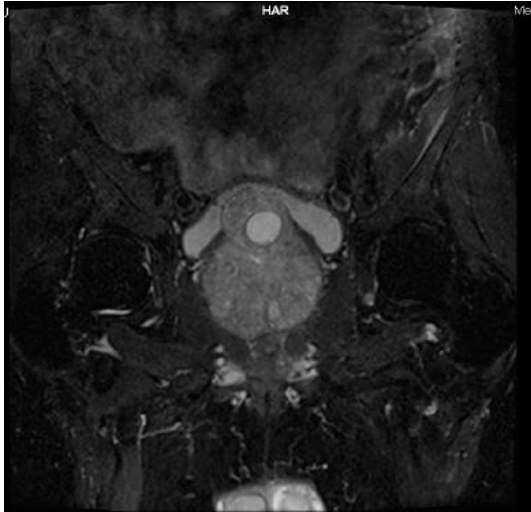


Figure 6. Coronal STIR. Protrusion of the cranial large nodule with extrinsic compression of the urinary vesicle.



Typically prostate cancer is isointense to gland in T1 and hypointense to the normally high intensity peripheral zone on T2. Central gland malignancy is difficult to be identified because of BPH which always distorts normal anatomy. There are other diseases that may cause low signal intensity areas within the peripheral zone on T2 weighted image like prostatitis, granulomatous disease stromal disease within the peripheral zone and postbiopsy blood or scars.

MRI is very important because it can reveal the real extent of the tumour and can show its spreading beyond the prostate capsule. The tumour can spread into periprostatic fat or neurovascular bundle, ejaculatory ducts, seminal vesicles, bladder, lymph nodes or we can assess the osseous metastatic disease. The capsular penetration occurs most commonly at the prostatic apex (1). We use multiple criteria to detect extracapsular extension of prostate cancer. We estimate the possible irregular bulge in capsule, changes of the rectoprostatic angle, asymmetry of the neurovascular bundle and capsular retraction or local scar. MRI must assess capsular tumour contact and visualize contiguous tumour local extension. Seminal vesicular extension has to evaluate direct tumour extension into the seminal vesicles. MRI should evaluate tumour extension in other direction. Contiguous spread of the tumour must also be assessed along the ejaculatory ducts.

The MRI semiology consists in seminal vesicles of

hypo- intensity in T2WI and non visualisation of the ejaculatory duct. Also, after dynamic T1 evaluation of the contrast enhancement we can predict malignant involvement of the tissue.

The lymphatic drainage of the prostate is made into the internal and external iliac lymph nodes including the obturator nodes (2). Lymph nodes with a diameter greater than 1 cm are suspicious for metastasis disease.

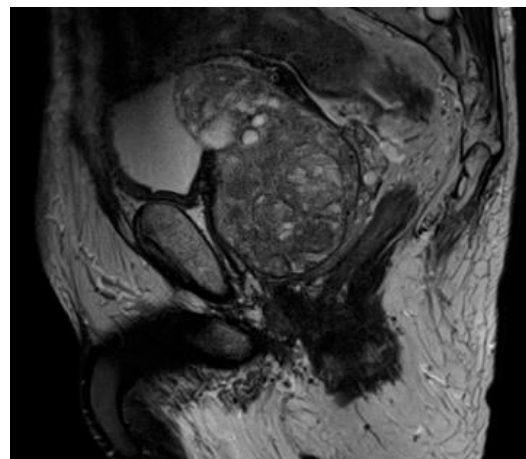
On T2-weighted images with low signal intensity areas within the seminal vesicles and asymmetry in size may indicate tumour invasion. However, blood, changes secondary to radiation therapy and other benign processes may appear as low intensity areas inside the seminal vesicles.

Key Points

Prostatic cancer usually occurs in the peripheral zone. Bone metastases are very unlikely to appear when the PSA is less than 10. The extracapsular spread indicates a nonsurgical treatment of the disease. (1)

MRI is the preferred imaging modality in evaluating prostate cancer and prostate lesions. The aspect of the normal prostate can be described as follows: in T1 the prostate tissue has homogenous intermediate signal intensity; in T2 the anterior fibromuscular stroma is low T1W and T2W signal.

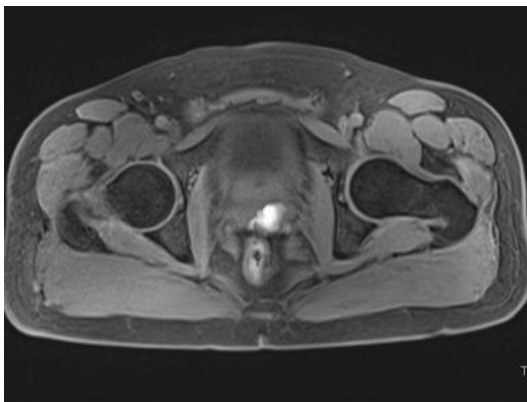
Figure 7. Sagittal T2 TSE. Multiple nodules but the prostate is still well delineated.



The peripheral zone has high T2W signal, similar to or greater than adjacent fat. The central and transitional

zones are lower T2W signals than peripheral zone. The true capsule is a thin rim of low signal intensity. The distal urethra is a low intensity ring in T1 and T2.

Figure 8. T1 TSE axial. Presence of blood at the seminal vesicles (hypersignal corresponding to methemoglobin inside seminal left vesicle)



In the last years, MRI became a common procedure in the detection of prostate cancer. The main indication is to evaluate patients with increased PSA and with prior negative biopsies. The best MRI procedure is multiparametric MRI. Multiparametric MRI consists of high resolution T2 axial sequence, as morphological study, T1 dynamic contrast examination and spectroscopy.

The standard MRI examination recommended was published in the interest of improving the quality of procedure and reporting. It was improved by a group of experts of the European Society of Urogenital Radiology (ESUR). In addition to the standard minimum examination protocol, the guideline describes also a structured reporting scheme. This scheme is called PI-RADS based on the BI-RADS. The score varies from 1-5. For a correct estimation of the score we have to choose the most adequate images and to add a scoring table that combines the aggregated multiparametric score with a total PI-RADS score.

In practical clinical activity, we also use Gleason score to determine the histological grading of the prostate malignant involvement. The name of the score is given after Donald Gleason – an US pathologist.

A score of 1 to 5 is assigned to each of the two largest areas of tumor involvement in the samples obtained,

based on the worst feature with 1 least aggressive and 5 most aggressive.

PI-RADS classification includes several criteria.

The 3 Tesla magnets is the hardware tool necessary for obtaining best images in prostate assessment but we can also use other variants.

In T2 with high resolution quality images we grade from I to V for the peripheral zone:

I – normal aspect with hyperintense homogenous peripheral zone

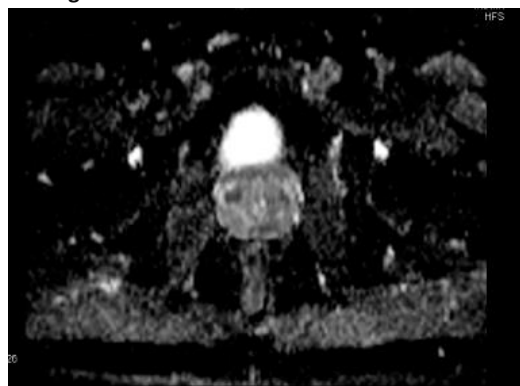
II – discrete hypointense focal lesion wedge or bandshaped ill defined

III – more advanced lesion and different from 1,2,4,5 classification

IV – severe hypointense lesion well defined without extracapsular extension

V – hypointense mass round and bulging with capsular involvement or seminal vesicle invasion.

Figure 9. DWI axial. Diffusion restriction area.



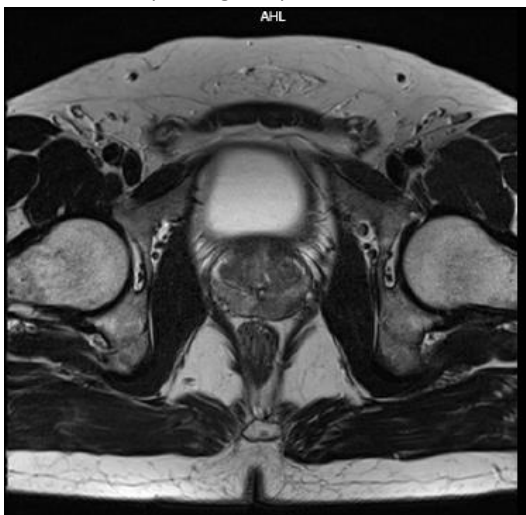
For example, according to the German interdisciplinary guideline of prostatic cancer for a correct imaging diagnosis we should perform MRI with a minimum strength of 1, 5 Tesla (T) using a combined endorectal body phased – array coil or a 3 Tesla machine and a combination of multiparametric sequences. When we use a 3 Tesla machine an endorectal coil is not mandatory.

Also in T2 for the central zone, we grade the lesion from I to V:

I – the central zone has stromal and glandular hyperplasia without focal hypointense nodular or oval – shaped

- II – round hypointense lesion with signs of well defined capsule or band shaped hypointense region.
- III – changes not falling into category 1,2 or 4,5
- IV – oval shaped anterior hypointense lesion without evidence of capsular involvement – homogenous hypointense lesions with loss of matrix ill defined margins
- V – oval shaped with compression, retraction, extension of the anterior capsule irregular infiltrating mass with architectural disintegration and invasion into adjacent structures.

Figure 10. T2 TSE axial. Low signal intensity area corresponding to a prostate tumour.



MRI is very efficient in differentiating lesions with almost similar morphological appearance like post-biopsy scars, atrophic changes, prostatitis, post-treatment lesions, and intraepithelial neoplasias.

In diffusion weighted imaging the analysis of the movement (diffusion) of the water molecules are expressed by the ADC parameter (apparent diffusion coefficient). The molecular diffusion in tissues is generally restricted by cell structures and membranes.

Intracellular edemas or higher cell densities lead to the reduction of the free molecular movement. In tissues with higher cell densities, like prostate carcinoma, ADC has reduced values. The diffusion sequence use upper values of 800-1000s/mm but there are studies that prove that there is a benefit in improving the diagnostic value of the sequence with a

value of 2000 and at 3 Tesla magnetic fields. The orientation of the sequence must be in the same plane like T2 axial and with same FOV for efficient multiparametric comparison. We can also grade prostate lesions using DWI:

- I – no reduction in ADC compared to normal tissues
- II – diffuse hyperintensity image with low ADC and no focal lesions
- III – unilateral hyperintensity with diffuse reduced ADC (no focal lesion)
- IV – focal area with reduced ADC and isointense on the diffusion sequence
- V – focal hyperintense mass or focal lesion with a reduced ADC.

T1 with dynamic contrast – DCE – MRI (dynamic contrast enhancement – MRI) is a very efficient method to obtain data about vascularisation and neoangiogenesis of the prostate. When we perform DCE – MRI, we evaluate the curves of enhancement after a bolus injection of a gadolinium based contrast medium (the injection rate for a correct evaluation must be 2.5 ml/sec and a we must use a subsequent injection of 20 ml of isotonic saline solution).

Dynamic contrast-enhanced magnetic resonance imaging strategies vary, but, in general, three types of imaging data are acquired. Initial images localise the tumour and provide anatomical information.

Sequences that allow calculation of baseline tissue T1-values before contrast agent administration are acquired to enable analysis of blood flow into the tumour. The dynamic data are acquired every few seconds in T1-weighted images over a period of around 5–10 min depending on the soft and power MRI machine gradients. We use T1-weighted spoiled gradient echo sequences are, as they allow good contrast medium sensitivity, high signal-to-noise ratio, adequate anatomical coverage and rapid data acquisition (Parker and Buckley, 2005). The Signal Intensity curves measured by DCE – MRI correspond to three maintypes of curves. Curve type I – the signal intensity continue to increase. Type II is characterized by a progression and a slight depression of the Signal Intensity. The type III curve is defined by the immediate wash out after reaching the peak enhancement. We add point to the scoring system if

there is a focal lesion, another one is added if there are asymmetric lesions or unusually located lesions (anterior parts of the transition zone and anterior horns of the peripheral zone).

Magnetic Resonance Spectroscopy Imaging (MRSI) allows the measurements of the relative concentration and distribution of the metabolites like citrate, creatine and choline in the prostate. The

metabolic information can increase the specificity of the morphological value of the MRI examination and evaluate the progression or the involution after different kind of therapy. The quality of the MRSI is dependent on the physical and technical support and also of the local and particular condition like post-biopsy hemorrhage, regional prosthetic or metal clips and artifacts.

PI-RADS Classification	Definition	Protocol T2, DWI, DCE	Protocol T2, DWI, DCE, MRS
1	most probably benign	3, 4	4, 5
2	probably benign	5, 6	6 – 8
3	indeterminate	7 – 9	9 – 12
4	probably malignant	10 – 12	13 – 16
5	highly suspicious of malignancy	13 – 15	17 – 20

Citrate (C) is synthesized, secreted and stored in large quantities in normal glandular tissue of the prostate and is therefore used as an organmarker for healthy prostate tissue.

Creatine plays an important role in the cells' energy metabolism and serves as an internal reference of intensity. Choline (Cho) refers to the sum of choline-containing compounds, which includes various free choline compounds such as phosphocholine, glycerophosphocholine, free choline, CDPcholine, acetylcholine and choline plasmalogen. The intensity of the choline resonance reflects the extent of membrane turnover and is significantly elevated in cancerous tissue.

- Type 1: Cho is significantly lower than citrate.
- Type 2: Cho is elevated but still lower than citrate .
- Type 3: Cho is approx- imately on the same level as citrate.
- Type 4: Cho is elevated compared to citrate.
- Type 5: Cho is significantly elevated compared to citrate.

In analogy to the BI-RADS, the PI-RADS system offers the advantage of a standardized and easy communication of findings to other professional colleagues. Every lesion should be evaluated using a standardized graphic prostate scheme with at least 16, better 27, sectors. For each lesion, a point score

between 1 and 5 is to be assigned per method. This is used to calculate the total score, which reflects the probability of the presence of clinically relevant cancer.

The total score is then converted to the relevant PI-RADS score, providing the advantage that the final PI-RADS score is independent of the number of techniques used and can, thus, be easily communicated.

Since the conversion of point scores is not explicitly explained in the ESUR guidelines, the authors recommend using the algorithm given in. For routine clinical work, the authors further suggest that a diagnosis of suspected prostate cancer should be made if the PI-RADS score is 4.

CONCLUSION

In summary, structured reporting of a lesion, using the multi-parametric approach, increase the quality and diagnostic value of prostate MRI.

Therefore, application of the PI-RADS scheme based on the representative images provided here is recommended for clinical routine. The standardized graphic reporting scheme facilitates the communication with referring colleagues. Moreover, a standardized reporting system not only contributes to quality assurance, but also promotes widespread

use of the method and implementation of large-scale multicenter studies, which are needed for further evaluation of the PI-RADS system, in analogy to the BI-RADS system used in breast imaging.

The therapeutic approach varies widely and includes also the watchful waiting, androgen ablation, hormone therapy radical surgery, various forms of

radiation therapy.

Multiparametric MRI is the most efficient method in providing information about the size, location and extent of the prostate cancer. These useful information allow the surgeon to choose the best way to resect the tumor, to perform optimal resection and also, to plan radiation therapy.

References:

1. PI-RADS Classification: Structured Reporting for MRI of the Prostate M. Röthke¹; D. Blondin²; H.-P. Schlemmer¹; T. Franiel. *Magnetom FLASH- Nr.3 / 2013*.
2. Schlemmer HP. Multiparametric MRI of the prostate: method for early detection of prostate cancer? *Fortschr Röntgenstr* 2010; 182: 1067–1075. DOI: 10.1055/s-0029-1245786.
3. Franiel T. Multiparametric magnetic resonance imaging of the prostate – technique and clinical applications. *Fortschr Röntgenstr* 2011; 183: 607–617. DOI: 10.1055/s-0029-1246055.
4. Barentsz JO, Richenberg J, Clements R et al. ESUR prostateMR guidelines 2012. *Eur radiol* 2012; 22: 746–757. DOI: 10.1007/s00330-011-2377-y.
5. Dickinson L, Ahmed HU, Allen C et al. Magnetic resonance imaging for the detection, localisation, and characterisation of prostate cancer: recommendations from a European consensus meeting. *European urology* 2011; 59: 477–494. DOI: 10.1016/j.eururo.2010.1.2009