

## Penile fracture – clinical case presentation

C. Farcaș<sup>1</sup>, V. Botea<sup>1</sup>, R. Popescu<sup>1</sup>, Marius Dinu<sup>1</sup>, Ovidiu Bratu<sup>1,2</sup>, D. Spînu<sup>1</sup>, Dan Mischianu<sup>1,2</sup>

### INTRODUCTION

Fracture of the penis is a rupture of the tunica albuginea of the corpus cavernosum, usually while the penis is rigid and erect. When erect, the albuginea layer stretches so far until its thickness reaches approximately 0.25 – 0.5 mm, compared with a 2 mm thick when flaccid. Thus the erect penis is much more vulnerable to serious damage from blunt trauma than the pendulous, flaccid penis. The most common cause of penile fracture is vigorous vaginal intercourse, more likely when woman is on top, but it can also occur during masturbation, forced bending of the erect penis or any mechanical trauma to the erect penis. The classic presentation described by the patient cracking or popping sound, followed by rapid detumescence, severe pain, ecchymosis of the penile skin, and swelling of the affected side with deviation of the penis shaft away from the affected side. In most cases, the penile fracture is a transverse corporeal tear close to the corpus spongiosum on the ventral aspect of penis shaft or on the lateral aspect and the tunical tear is usually 1 to 2 cm in length. The rupture can involve one or both corpora cavernosa as well as corpus spongiosum with the contained urethra therefore urethral rupture can also occur in. Most urethral injuries are associated with gross hematuria, blood at the meatus or inability to void, although the absence of these findings does not definitively rule out urethral injury.

### DIAGNOSIS AND IMAGING

The penile fracture is considered by the most to be a clinical diagnosis, with little need for imaging if the patient presents with a convincing history and physical examination. However given that urethral injury occurs not infrequently, preoperative exploration of the urethra should be considered when urethral injury is suspected (urethrography or flexible/rigid cystoscopy). There are numerous reports of the accuracy of cavernosography and magnetic resonance imaging (MRI), in spite of their accurate results, they are sometimes too invasive, time consuming or costly to justify, particularly when the diagnosis can be established by clinical examination. Ultrasonography although noninvasive and easy to perform is also associated with significant false-negative studies. Another condition that may mimic penile fracture is rupture of the dorsal penile artery or vein during sexual intercourse, in these circumstances physical examination may not be adequate for definitive diagnosis of a corporeal tear and further investigations should be performed like MRI, ultrasonography or even surgical exploration.

### MANAGEMENT OF PENILE FRACTURE

Multiple publications indicate that suspected penile fractures should be promptly investigated and surgically repaired. Many reports show low complication rate and good outcomes as a result of

immediate surgical repair, (less than 5% penile curvature after immediate surgical repair – El Atat et al, 2008) as the favorite approach for treatment of this urological emergency. Conservative management can also be an option in patients with uncomplicated albugineal tears, without extensive hematoma or urethral injury, but most untreated fractures usually develop delayed and persistent penile pain or curvature with erection. Conservative management of penile fracture has been associated with penile curvature in more than 10% of patients, abscess or debilitating plaques in 25% to 30%, and significantly longer hospitalization times and recovery (Meares,1971; Nicolaisen et al, 1983; Kalash and Young, 1984; Orvis and McAninch, 1989).

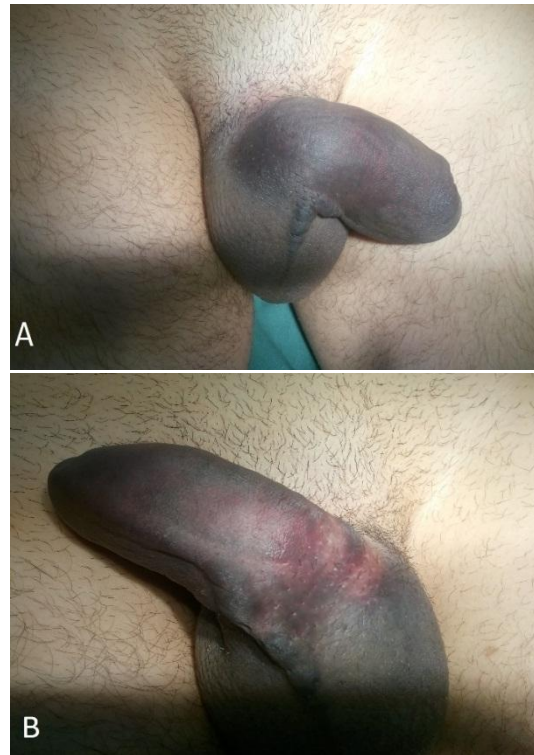
Although small lateral incisions may be used for localized hematomas or palpable tunical defects, a distal circumcising incision is the best option in most cases thus providing exposure to all three penile compartments. For the closing of the tunical defect is recommended to use interrupted absorbable suture 2-0 or 3-0. Deep corporeal vascular ligation or extensive debridement of the underlying erectile delicate tissue should be avoided. Timing of the intervention may also influence the long-term outcome of erectile function or postoperative complications in the way that the patient undergoing surgical repair intervention in the first 8 h after injury has significantly better long-term results than those having surgery delayed 24-36 h after fracture occurrence (Asgari et al, 1996; Karadeniz et al, 1996).

### PATIENT, METHOD AND RESULTS

A 31 years old patient presents in the emergency department in our hospital at approximately 03:15 a.m., this being the third medical unit he was attending that day, accusing pain in the external genital area associated with extended hematoma of the penis and scrotum with the deviation of the penis on the left side (Figure 1A). Further anamnesis discovers posttraumatic injury of the penis while sexual intercourse that happened at approximately 01:00 a.m. The patient describes powerful bending of the penile shaft, and at the same time strong local pain, accompanied by a snapping sound and after

that immediate detumescence of the penis with decrease in pain intensity. Patient describes urine voiding normal and no bleeding out of the urethra.

**Figure 1.** Extended hematoma of the penis and scrotum and pathological deviation of the penis shaft on the left side (A)



The patient is admitted in our department and undergoes a soft tissue ultrasound that reveals a local hematoma of the penis and a small breach of approximately 3-4 mm in diameter which is situated on the ventral aspect of the right cavernous body, of the proximal third of penis shaft.

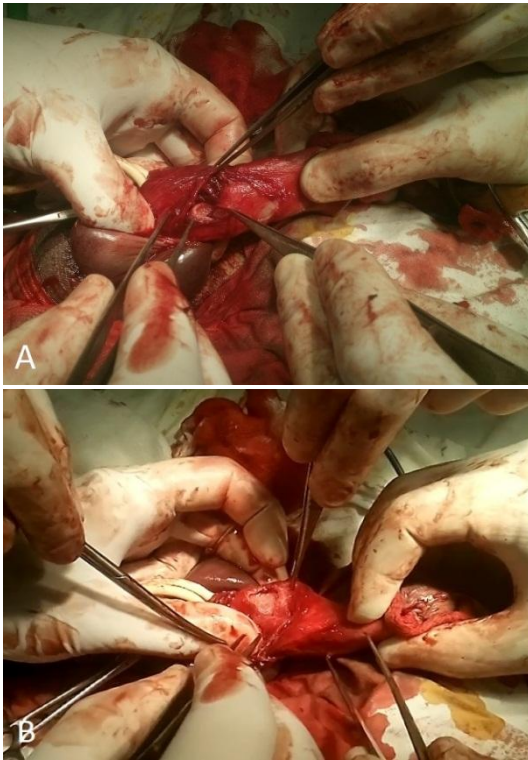
Emergency surgery is decided, with spinal anesthesia at 08:00 in the morning (7 hours after the injury occurrence).

After local antiseptic measures, a 14 Fr. Foley catheter was placed before the beginning of the intervention. A distal circumcising incision is made at approximately one cm proximal of the coronal sulcus, followed by degloving the penis, and exposing the tunical fracture site in the albuginea.

The tunical tear was found on the ventral aspect of the corpora cavernosum at a distance of 3-4 cm from the

base of the penis.

**Figure 2.** A: albugineal tear on the left cavernous body.  
B: albugineal tear on the right cavernous body.



The rupture site was much greater than the one observed on the ultrasound scan. The real size of the tear was about 3 cm and involved both cavernous body on their anterior aspect, as well as the septum of the albuginea underneath the spongy body (Figure 2, A and B).

The spongy body was carefully dissected from the corpora cavernosa and so the entire length of the transversal rupture was individualized.

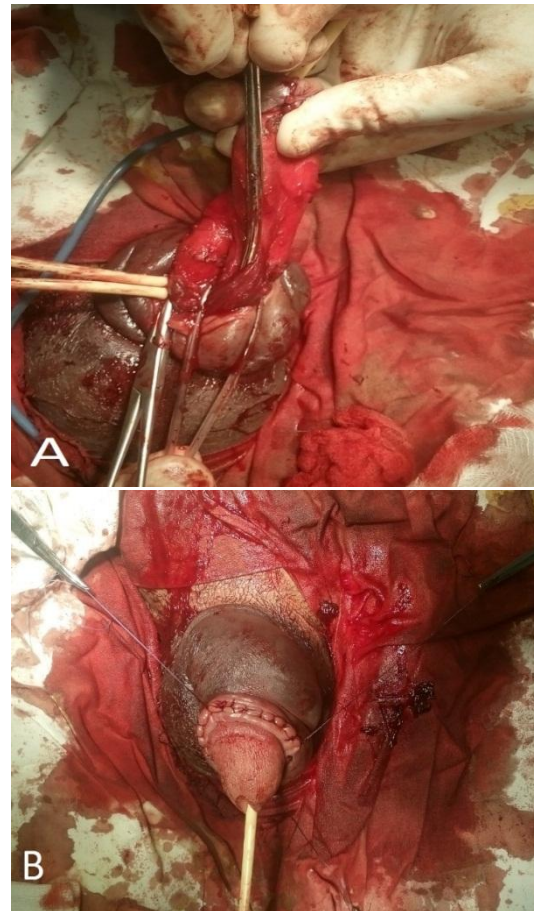
A temporary elastic Tourniquet at the base of the penis was necessary for local control of bleeding.

Defect repair was performed with separate absorbable 3-0 USP sutures. For the full length of the breach 14 to 15 separate sutures were needed. Final aspect of the repaired defect of the tunica albuginea can be seen in both pictures below (Figure 3, A-B).

The patient's evolution was favorable under antibiotic therapy for 5 days with no infectious complications. Second day postop he mentioned a

mild morning erection although he was under treatment with Cyproterone acetate 50 mg twice a day and Diazepamum 10 mg a day in two doses.

**Figure 3.** A: ventral aspect of penis with the spongy body mounted on a lasso and the albugineal suture.  
B: final aspect after suture of the skin.



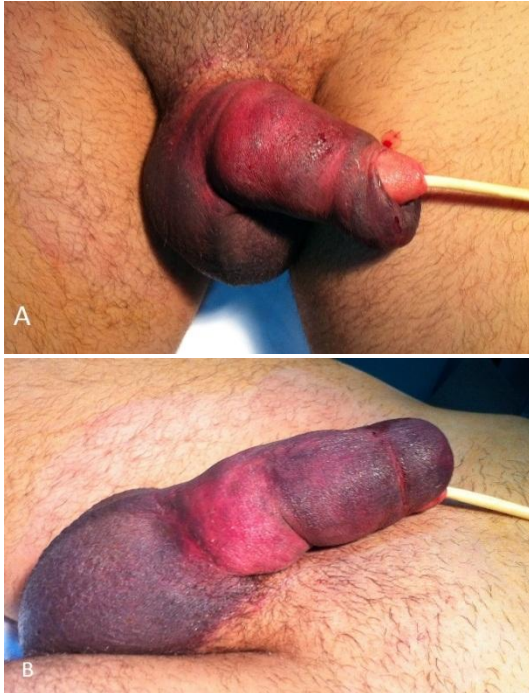## DISCUSSION AND CONCLUSION

Penile fracture is a rare case of urological emergency that should undergo in most of cases emergency surgical treatment.

The immediate surgical repair attitude (<8 h) is the preferred approach for treatment of penile fracture as reported in numerous centers around the world due to their low complication rates.

While the conservative approach is described in patients with small and uncomplicated tears, most unrepaired fractures develop late penile curvature or pain with erection.

**Figure 4.** Aspect of the penis and scrotum the second day postoperatively while patient still carries a Foley catheter.



The urgency of surgical exploration justified in our case the discrepancy between imaging findings and the reality found during the surgical exploration.

Albugineal tear that involves the both corpora cavernosum is extremely rare and also usually is associated with urethral injury, which in this patient, the last one, was not the case.

The incidence of concomitant urethral injury is approximately 20 % in Europe and the USA. Most urethral injuries are associated with urethral bleeding or gross hematuria or even inability to void, but also, the absence of these signs does not exclude a potential urethral injury.

## References:

1. Allen F. Morey, MD, FACS - Daniel D. Dugi III, MD – Injuries Of The External Genitalia – Genital And Lower Urinary Tract Trauma – Campbell-Walsh Urology, Tenth Edition, International Edition.
2. Genoa G Ferguson, Steven B Brandes – Reconstruction for genital trauma – Penile Fracture – Drago Montague, Inderbir Gill, Kenneth Angermaier, Jonathan H Ross – Textbook of Reconstructive Urologic Surgery.
3. E. Plas, I. Berger – Genital Trauma – M. Hohenfellner, R.A. Santucci – Emergencies in Urology.
4. John Reynard – Traumatic Urological Emergencies – Penile Fracture – Hashim Hashim, John Reynard and Nigel C. Cowan – Urological Emergencies in Clinical Practice.
5. Petrisor Geavlete, Dr Dragos Georgescu – Traumatismele Aparatului Urogenital – I. Sinescu, G. Gluck – Tratat de Urologie.
6. Al Ansari; R. A. Talib; A. Shamsodini; A. Hayati; O. Canguven; A. Al. Naimi - Which Is Guilty in Self-Induced Penile Fractures: Marital Status, Culture or Geographic Region? - Int J Impot Res. 2013;25(6):221-223 – Medscape – Urology.