Journal of Coastal Life Medicine

journal homepage: www.jclmm.com

Original article doi: 10.12980/jclm.4.2016J6-127 ©2016 by the Journal of Coastal Life Medicine. All rights reserved.

Partridge embryo pathology in relation to gentamicin-induced lesions

Hadi Tavakkoli[1*], Amin Derakhshanfar[2]

[1]*Department of Avian Medicine, School of Veterinary Medicine, Shahid Bahonar University of Kerman, Kerman, Iran*

[2]*Diagnostic Laboratory Sciences and Technology Research Center, Center of Comparative and Experimental Medicine, Shiraz University of Medical Sciences, Shiraz, Iran*

ARTICLE INFO

Article history:
Received 21 Jul 2016
Received in revised form 6 Aug 2016
Accepted 15 Aug 2016
Available online 23 Aug 2016

Keywords:
Aminoglycosides
Embryo
Gentamicin
Pathology

ABSTRACT

Objective: To determine the macroscopic and microscopic lesions of various dosages of gentamicin in the partridge embryo.
Methods: Fertile chukar partridge eggs were allocated into four groups. Group 1: saline-injected group whose individuals were administered by sterile physiological saline solution of 0.2 mL/egg inserted into yolk sac. Groups 2, 3 and 4 whose individuals were similarly administered by gentamicin sulfate at a dosage of 80 mg/kg egg-weight once, twice and three times, respectively.
Results: Results showed that the embryos were congested and stunted in the gentamicin-injected groups. Defects in feet, wings and feather development were accompanied by microscopic lesions in brain, meninges, heart, lungs, liver and kidneys. Histopathological lesions were noticed as edema, undeveloped tissues, necrosis and degeneration in the affected organs.
Conclusions: Based on acquired results, it is concluded that gentamicin at above-described dosages causes toxicopathological effects to the partridge embryo in a dose dependent manner.

1. Introduction

Gentamicin is an antimicrobial agents which is effective against most infectious bacterial diseases in birds *e.g.*, colibacillosis, salmonelosis, mycoplasmosis, *etc*. In breeder farms, injecting of antibiotic into egg, result in a decrease in mortality rate. In man, following injection, gentamicin enter into the fetal circulation from the placenta[1]. In this regard, neonates toxicity due to antibiotic administration is reported[2]. In addition, side effects such as nephrotoxicity, ototoxicity and neurotoxicity have limited the therapeutic use of antibiotics such as gentamicin[3,4].

Up to now, gentamicin toxicity has been examined and described in different animal models such as rat[5], rabbits[6,7] and human[8,9]. The results of these studies shown that the possible teratogenicity and toxicity would be as determining factor minimizing potential therapeutic effects of gentamicin during pregnancy. On the other hand, little researches are available in the literature about adverse effects of gentamicin in game birds embryo. Therefore, in the current investigation, we evaluated the macroscopic and microscopic lesions of different dosages of gentamicin experimentally injected into the partridge embryos.

2. Materials and methods

2.1. Fertile eggs

Forty-eight fertile chukar partridge eggs with an average egg-weight of (21.50 ± 1.20) g were purchased from the Karimi Breeder Company, Fars, Iran. In this company, the partridges were breeding

*Corresponding author: Hadi Tavakkoli, Department of Avian Medicine, School of Veterinary Medicine, Shahid Bahonar University of Kerman, Kerman, Iran.
Tel: +98 (341)3222900
Fax: +98 (341)3222047
E-mail: Tavakkoli@uk.ac.ir

All experimental procedures involving animals were conducted in accordance to the suggested European ethical guidelines and approved by the suggested European ethical guidelines.

Foundation Project: Supported by part of a grant (No. 488) from the University of Shahid Bahonar Research Foundation.

The journal implements double-blind peer review practiced by specially invited international editorial board members.

according to the standard procedures.

2.2. Experimental protocol

The experiment was performed according to the suggested European ethical guidelines for the care of animals in experimental investigations. Eggs were incubated at 37.6 ˚C and 60% relative humidity. Then, embryonated eggs were separated and randomly allocated to four groups of 12 eggs each: Group 1: saline-injected group (control group). Fertile eggs were administered with sterile physiological saline solution of 0.2 mL/egg into yolk sac. Groups 2, 3 and 4: eggs were treated with gentamicin sulfate (Gentafar 10%®, Farvet, city? Netherlands) at dosage of 80 mg/kg egg-weight once (at day 4 of incubation), twice (at days 4 and 5 of incubation) and three times (at days 4, 5 and 6 of incubation), respectively. Embryos received gentamicin directly into their yolk sacs, according to the standard method of injection of drugs into eggs[10,11]. Fertile eggs were re-incubated until day 21 post-treatment. At the end of this period, eggs were collected and examined for any macroscopic and microscopic changes of gentamicin toxicity. All experimental procedures were conducted in accordance to the suggested European ethical guidelines for the care of animals in experimental investigations and approved by the Animal Ethics Committee of the Research Council of Shahid Bahonar University, Iran.

2.3. Pathological examination

At the end of the study, embryos were euthanized by cooling[12]. Then, embryos were removed and evaluated under stereomicroscope to investigate any macroscopic alterations. Then, the tissues of embryos including brain, heart, lungs, liver and kidneys were dissected out and fixed in 10% neutral buffered formalin. Standard training of tissues was done and serial sections of paraffin embedded tissues were made and stained with hemotoxylin and eosin to investigate microscopic alterations.

2.4. Statistical analysis

The SPSS program version 20 and Fisher's exact test was applied to statistical analysis. Kruskal-Wallis test was also applied to establish whether there were differences between dosage of gentamicin and pathological findings. A *P*-value of less than 0.05 indicated statistically significant.

3. Results

3.1. Gross findings

Macroscopic observation of eggs in Groups 3 and 4 demonstrated moderate and severe anasarca in embryos, respectively, but not in other groups. The embryos were stunted in all gentamicin-injected groups (Groups 2, 3 and 4), however the worth condition was seen in Group 4 (injected with gentamicin sulfate at days 4, 5 and 6 of incubation). The feet and wings of embryos were hypoplastic in Group 3, and aplastic in Group 4. The feather formation was affected in all gentamicin-injected groups, orderly, so feather growth was impaired in Group 4 much more than other groups. Embryos in gentamicin-injected groups were suffered from congestion, resulted in red-dark color appearance. The embryos were normal in Group 1 (control group) (Figure 1). Moderate and severe lack of organogenesis was observed in Groups 3 and 4, respectively (Figures 2 to 4).

Figure 1. Photograph of a partridge embryo treated with sterile physiological saline solution (Group 1). The embryo was normal with no gross abnormality.

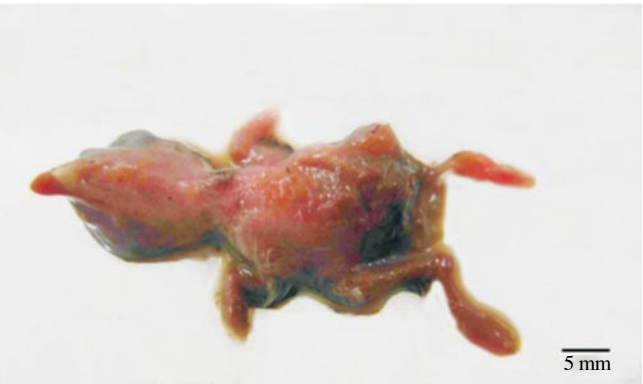

Figure 2. Photograph of a partridge embryo treated with 80 mg gentamicin/kg egg-weight once (Group 2) showing stunted and congested embryo. Note to abnormal feather formation.

Figure 3. Photograph of a partridge embryo treated with 80 mg gentamicin/kg egg-weight twice (Group 3) showing stunted and dark embryo. Note to the hypoplastic feet and wings and also to no feather formation.

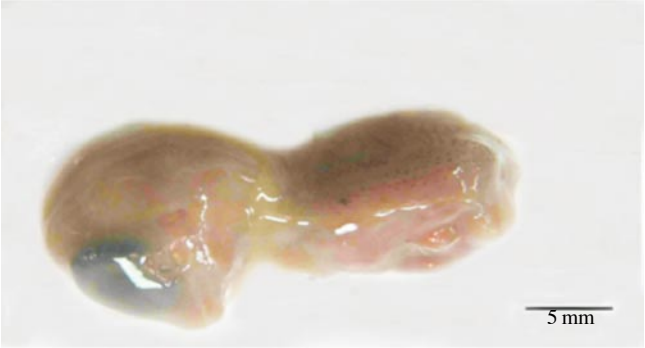

Figure 4. Photograph of a partridge embryo treated with 80 mg gentamicin/kg egg-weight three times (Group 4) showing malformed embryo with lack of feet, wing and feather.

3.2. Microscopic findings

All embryos in Group 1 (control group) had normal brain structures. In Group 2 (treated with gentamicin, one time), the brain's tissues and meninges were edematous and the neuronal cells were still undeveloped. In addition, the separation between cardiac myocytes was visible and no sign of necrosis was seen. However, necrosis was noticed in hepatocytes of the liver and glomeruli as well as tubules of the kidneys. The lungs were distorted and only remnants of the airways were observed. In Group 3 (treated with gentamicin, two times), brain was edematous and under developed. The lesions of the heart, in this group, were similar to Group 2. In the liver, dilation of the central vein and hepatocellular degeneration and necrosis were observed. In this group, only the ghost of the lung was remained and the kidneys were severely destructed with no characteristic structure. In Group 4 (treated with gentamicin, three times), intensive hepatocellular necrosis with sinusoidal dilatation, distortion of tubules and glomeruli in the kidneys, myxomatous degeneration of the cardiac myocytes, edema in brain tissue and meningeal thickening were seen. In this group, lung was not developed normally and only remnants of its structure were seen (Figures 5 to 9).

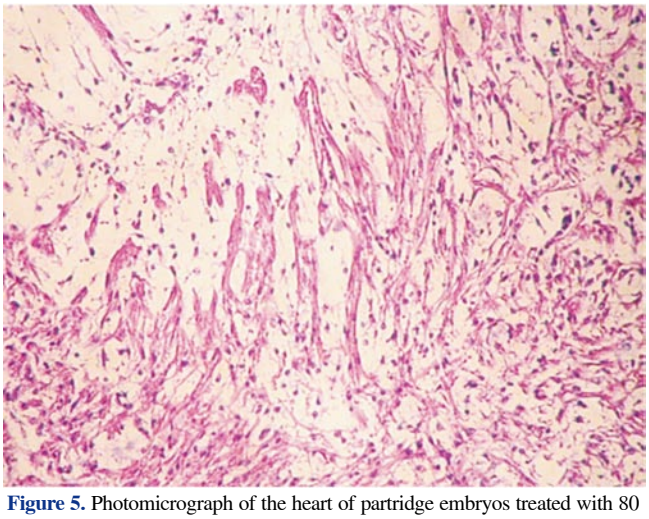

Figure 5. Photomicrograph of the heart of partridge embryos treated with 80 mg gentamicin/kg egg-weight one and two times (Groups 2 and 3). Cardiac myocytes were separated from each other (×100 hematoxylin and eosin staining).

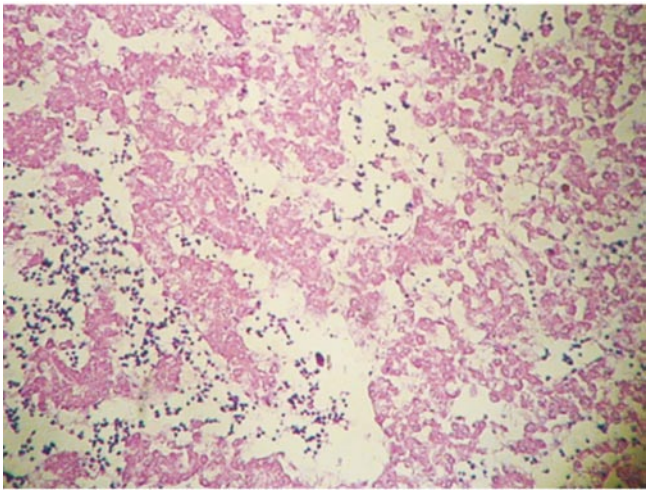

Figure 6. Photomicrograph of the liver of partridge embryos treated with 80 mg gentamicin/kg egg-weight two and three times (Groups 3 and 4). Hepatocellular degeneration and necrosis with sinusoidal dilation are seen (×100 hematoxylin and eosin staining).

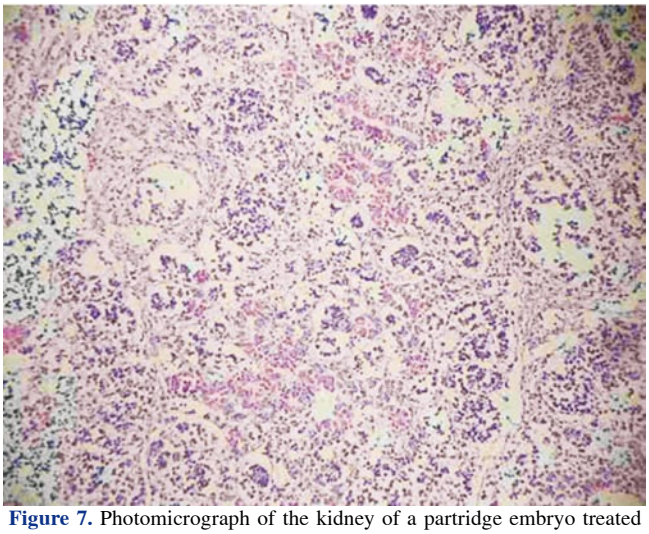

Figure 7. Photomicrograph of the kidney of a partridge embryo treated with 80 mg gentamicin/kg egg-weight three times (Group 4). Distorted kidney with no characteristic tubules and glumeruli are seen (×100 hematoxylin and eosin staining).

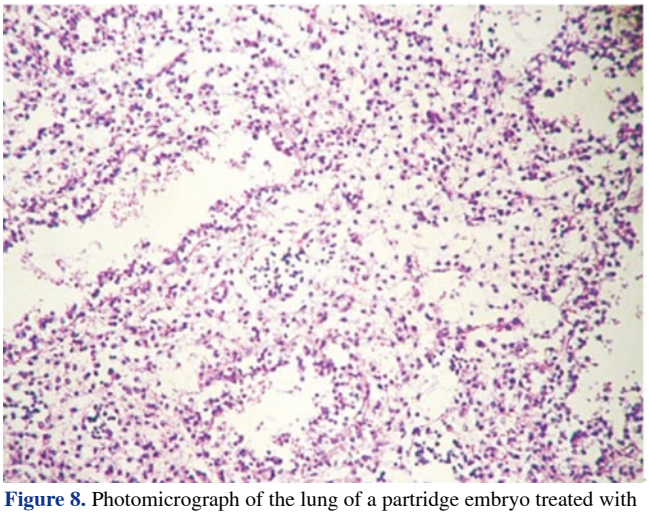

Figure 8. Photomicrograph of the lung of a partridge embryo treated with 80 mg gentamicin/kg egg-weight three times (Group 4). The lung was not developed normally. Normal structural elements are not seen (×200 hematoxylin and eosin staining).

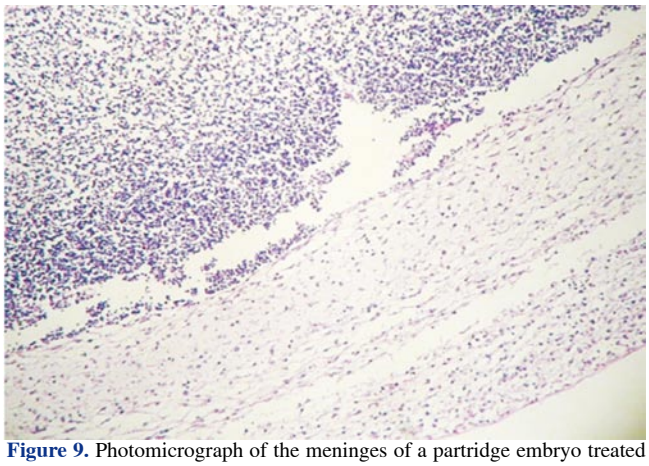

Figure 9. Photomicrograph of the meninges of a partridge embryo treated with 80 mg gentamicin/kg egg-weight three times (Group 4). Meningeal thickening was seen (×100 hematoxylin and eosin staining).

4. Discussion

There are few researches in the literature about histopathological alteration of gentamicin in game birds embryo. Therefore, in this study, we investigated lesions and organ injuries following one, two and three times administration of gentamicin in partridge embryo.

Our results obviously showed macroscopic and microscopic alterations in partridge embryos exposed to various dosages of gentamicin. The macroscopic alterations showed a dose-dependent relationship in the gentamicin-injected groups. The worth condition and sever signs were seen in the embryos that belong to the high dosage group (80 mg gentamicin/kg, three times) and characterized by anasarca, stunting, impaired feather formation, aplasia of the feet and wings, congestion and lack of organogenesis. This study showed that gentamicin can affect the organogenesis in partridge embryos at dosage of 80/kg egg-weight if injected two and three times into egg. These alterations may be due to cytotoxic and anti-proliferative properties of gentamicin. For example, some authors have previously described that *in vitro* administration of gentamicin and various aminoglycosides (neomycin B, paromomycin, tobramycin) decrease the proliferation of some human cells, such as epidermal keratinocytes, supposedly by inhibiting tRNA processing[13]. Moreover, gentamicin has been shown to reduce cell proliferation in corti cell line[14] and high concentrations of it inhibited cell proliferation in human osteoblast like cells[15]. There is no comparable study in the literature determining the effect of gentamicin on the game birds embryo, and additional researches require to be done to evaluate the toxic effects of gentamicin in avian embryos.

To the best of our knowledge, we are the first to report the toxicopathological effect of gentamicin in partridge embryo. Despite, many investigations are available in the literature about adverse effects of gentamicin in various species[16-19].

In the present study, two novel findings were structural consistent lesions in the brain and meninges. No similar alterations have been described in avian embryo by previous researchers. In the brain, edema was seen. Lesions such as edema, hyperemia and thickening of the meninges were also seen in embryos. The mechanisms of these lesions are not certain and further attempts are therefore required to elucidate the underlying mechanisms.

Myxomatous degeneration of cardiac myocytes was seen in embryos that received the highest dosage of gentamicin (80 mg/kg, three times) but in other groups, myocytes were observed normal with no sign of necrosis. No similar alterations described in birds embryo, but hemorrhagic lesions on epicardial surface in layer[20] and broiler chickens[21], which, injected with gentamicin sulfate, were reported.

The pathological defects observed in the liver tissue were prominent in embryos given 80 mg/kg gentamicin three times at days 4, 5 and 6 of incubation. Hepatotoxic activity of gentamicin such as swelling, congestion, vascular degeneration and necrosis have been reported by others[21,22].

In the kidneys, gentamicin produced histopathological alterations ranging from necrosis of the tubules and glomeruli to complete destruction and distortion of the kidneys. Similar to our findings, the damage of the kidneys has been reported by reserchers in various species including chicken[23], rat[24,25], human[26], dog[27] and farm animals[28,29].

Aminoglycosides are not metabolized in the liver and excreted by glomerular filtration[30]. Administration of the gentamicin in animals causes tubular cell apoptosis and necrosis in the kidneys. The toxicity of gentamicin is believed due to the production of reactive oxygen species in the kidneys. In addition, gentamicin accelerates the production of reactive oxygen species in association with an elavate in the lipid peroxidation and hence, decreases in the antioxidant enzyme activity in the intestine and kidney[31,32]. The drug mainly accumulates in the lysosomes. Furthermore, gentamicin produces membrane destabilization, lysosomal aggregation, alteration of lipid metabolism, and phospholipidosis which have been shown to result in cell death.

In conclusion, the results of the present study described various lesions induced by the administration of gentamicin at different dosage in partridge embryos. Macroscopic lesions in embryos were accompanied by histopathological changes in brain, meninges, heart, lung, liver and kidney. These alterations occurred in a dose-dependent manner. In addition, the present investigation advises concern in the use of aminoglycosid in game birds embryonated eggs.

Conflict of interest statement

We declare that we have no conflict of interest.

Acknowledgments

This work was supported in part by a grant (No.488) from the University of Shahid Bahonar Research Foundation. Authors wish to thank Dr. A. Bidadkosh for improving the use of English in the manuscript.

References

[1] Lehne RA, Rosenthal L. Pharmacology for nursing care: Elsevier Health Sciences; 2014, p.

[2] Musiime GM, Seale AC, Moxon SG, Lawn JE. Risk of gentamicin toxicity in neonates treated for possible severe bacterial infection in low- and middle-income countries: systematic review. *Trop Med Int Health* 2015; **20**: 1593-606.

[3] Paquette F, Bernier-Jean A, Brunette V, Ammann H, Lavergne V, Pichette V, et al. Acute kidney injury and renal recovery with the use of aminoglycosides: a large retrospective study. *Nephron* 2015; **131**: 153-60.

[4] Picard W, Bazin F, Clouzeau B, Bui HN, Soulat M, Guilhon E, et al. Propensity-based study of aminoglycoside nephrotoxicity in patients with severe sepsis or septic shock. *Antimicrob Agents Chemother* 2014; **58**: 7468-74.

[5] Quirós Y, Blanco-Gozalo V, Sanchez-Gallego JI, López-Hernandez FJ, Ruiz J, de Obanos MP, et al. Cardiotrophin-1 therapy prevents gentamicin-induced nephrotoxicity in rats. *Pharmacol Res* 2016; **107**: 137-46.

[6] Salih NA. Effect of nettle (*Urtica dioica*) extract on gentamicin induced nephrotoxicity in male rabbits. *Asian Pac J Trop Biomed* 2015; **5**: 756-60.

[7] Khaliq T, Mumtaz F, Rahman Z, Javed I, Iftikhar A. Nephroprotective potential of Rosa damascena mill flowers, Cichorium intybus linn roots and their mixtures on gentamicin-induced toxicity in albino rabbits. *Pak Vet J* 2015; **35**: 43-7.

[8] Bellmann R. [Pharmacokinetic and pharmacodynamic aspects in antibiotic treatment]. *Med Klin Intensivmed Notfmed* 2014; **109**: 162-6. German.

[9] Wrzesniok D, Beberok A, Otreba M, Buszman E. Impact of gentamicin on antioxidant enzymes activity in hemn-dp cells. *Acta Pol Pharm* 2015; **72**: 447-53.

[10] Hirst CE, Marcelle C. The avian embryo as a model system for skeletal myogenesis. *Results Probl Cell Differ* 2015; **56**: 99-122.

[11] Tavakkoli H, Derakhshanfar A, Gooshki NS. The effect of florfenicol egg-injection on embryonated chicken egg. *Int J Adv Biol Biom Res* 2014; **2**: 496-503.

[12] Jacobsen ID, Grosse K, Hube B. Embryonated chicken eggs as alternative infection model for pathogenic fungi. *Methods Mol Biol* 2012; **845**: 487-96.

[13] Tekos A, Prodromaki E, Papadimou E, Pavlidou D, Tsambaos D, Drainas D. Aminoglycosides suppress tRNA processing in human epidermal keratinocytes *in vitro*. *Skin Pharmacol Appl Skin Physiol* 2003; **16**: 252-8.

[14] Bertolaso L, Bindini D, Previati M, Falgione D, Lanzoni I, Parmeggiani A, et al. Gentamicin-induced cytotoxicity involves protein kinase C activation, glutathione extrusion and malondialdehyde production in an immortalized cell line from the organ of corti. *Audiol Neurotol* 2003; **8**: 38-48.

[15] Isefuku S, Joyner CJ, Simpson AH. Gentamicin may have an adverse effect on osteogenesis. *J Orthop Trauma* 2003; **17**: 212-6.

[16] Nale LP, More PR, Ghumare BC, Shendre SB. Experimental induction of gentamicin nephrotoxicity and its deterrence by concomitant treatment with *Carica papaya* Linn aqueous seed extract in wistar rats. *Anim Sci Rep* 2013; **7**: 13-9.

[17] Sagit M, Korkmaz F, Gurgen SG, Gundogdu R, Akcadag A, Ozcan I. Quercetine attenuates the gentamicin-induced ototoxicity in a rat model. *Int J Pediatr Otorhinolaryngol* 2015; **79**: 2109-14.

[18] Kranzer K, Elamin WF, Cox H, Seddon JA, Ford N, Drobniewski F. A systematic review and meta-analysis of the efficacy and safety of N-acetylcysteine in preventing aminoglycoside-induced ototoxicity: implications for the treatment of multidrug-resistant TB. *Thorax* 2015; **70**: 1070-7.

[19] Sagit M, Korkmaz F, Gurgen SG, Kaya M, Akcadag A, Ozcan I. The protective role of thymoquinone in the prevention of gentamicin ototoxicity. *Am J Otolaryngol* 2014; **35**: 603-9.

[20] Khan I, Khan MZ, Saleemi MK, Javed I, Khan A. Pathological and biochemical effects of intramuscular gentamicin administration in chickens. *Turk J Vet Anim Sci* 2008; **32**: 345-51.

[21] Saleemi MK, Khan MZ, Javed I, Khan A. Pathological effects of gentamicin administered intramuscularly to day-old broiler chicks. *Exp Toxicol Pathol* 2009; **61**: 425-32.

[22] Beger RD, Sun J, Schnackenberg LK. Metabolomics approaches for discovering biomarkers of drug-induced hepatotoxicity and nephrotoxicity. *Toxicol Appl Pharmacol* 2010; **243**: 154-66.

[23] Singroha R, Srivastava SK, Chhikara P. Effect of gentamicin on kidney in developing chicks. *Eur J Anat* 2012; **16**: 119-26.

[24] Veljkovic M, Pavlovic DR, Stojiljkovic N, Ilic S, Petrovic A, Jovanovic I, et al. Morphological and morphometric study of protective effect of green tea in gentamicin-induced nephrotoxicity in rats. *Life Sci* 2016; **147**: 85-91.

[25] Abdelsameea AA, Mohamed AM, Amer MG, Attia SM. Cilostazol attenuates gentamicin-induced nephrotoxicity in rats. *Exp Toxicol Pathol* 2016; **68**: 247-53.

[26] Kim S, LesherPerez SC, Kim BC, Yamanishi C, Labuz JM, Leung B, et al. Pharmacokinetic profile that reduces nephrotoxicity of gentamicin in a perfused kidney-on-a-chip. *Biofabrication* 2016; **8**: 8-15.

[27] Kai K, Yamaguchi T, Yoshimatsu Y, Kinoshita J, Teranishi M, Takasaki W. Neutrophil gelatinase-associated lipocalin, a sensitive urinary biomarker of acute kidney injury in dogs receiving gentamicin. *J Toxicol Sci* 2013; **38**: 269-77.

[28] Bauquier JR, Boston RC, Sweeney RW, Wilkins PA, Nolen-Walston RD. Plasma peak and trough gentamicin concentrations in hospitalized horses receiving intravenously administered gentamicin. *J Vet Intern Med* 2015; **29**: 1660-6.

[29] Burton AJ, Giguère S, Arnold RD. Pharmacokinetics, pulmonary disposition and tolerability of liposomal gentamicin and free gentamicin in foals. *Equine Vet J* 2015; **47**: 467-72.

[30] LeBras M, Chow I, Mabasa VH, Ensom MH. Systematic review of efficacy, pharmacokinetics, and administration of intraventricular aminoglycosides in adults. *Neurocrit Care* 2016; doi: 10.1007/s12028-016-0269-3.

[31] Quiros Y, Vicente-Vicente L, Morales AI, Lopez-Novoa JM, Lopez-Hernandez FJ. An integrative overview on the mechanisms underlying the renal tubular cytotoxicity of gentamicin. *Toxicol Sci* 2011; **119**: 245-56.

[32] Zhao X, Hong Y, Drlica K. Moving forward with reactive oxygen species involvement in antimicrobial lethality. *J Antimicrob Chemother* 2015; **70**: 639-42.