

## Case Report

# Thrombotic thrombocytopenia purpura in a Nigerian girl

Kaladada I. Korubo, *MB.BS, FMCPath*

Department of Haematology & Blood Transfusion, University of Port Harcourt Teaching Hospital, PMB 6173, Rivers, Nigeria.

Corresponding email: [dadakorubo@yahoo.com](mailto:dadakorubo@yahoo.com); Tel: +234 803 7492400

Received 29 March, 2016; Accepted 5 April, 2016

**Thrombotic thrombocytopenic purpura is a rare congenital or acquired disorder either due to mutations in the ADAMTS13 gene or development of antibodies to the ADAMTS13 protein. TTP causes a life-threatening form of thrombotic microangiopathy that is characterized by thrombocytopenia, microangiopathic haemolytic anaemia, fever, neurological symptoms and renal impairment. ADAMTS13 functions to cleave large von Willebrand factor multimers and in its absence there is unregulated VWF-dependent platelet thrombosis. A nineteen year old female presented with a history of menorrhagia, petechiae and purpural haemorrhages, painful right jaw, anaemia of 8.1g/dL and thrombocytopenia of  $31 \times 10^9/L$ . Her blood film showed numerous schistocytes with thrombocytopenia on film. Bone marrow aspirate revealed increased megakaryocytic and erythroid activity. The uric acid and lactate dehydrogenase parameters were elevated but her renal functions and other investigations were essentially normal. At presentation she was initially commenced on high dose prednisolone, however on review of the peripheral blood schistocytes and thrombocytopenia a provisional diagnosis of thrombotic thrombocytopenia was made and ADAMTS13 was done which revealed low ADAMTS13 levels. This is a case report to document this rare disorder for the first time in our environment which was successfully treated without the use of plasma exchange, plasma infusion or blood transfusion but rather with high dose prednisolone.**

**Keywords:** Thrombotic thrombocytopenic purpura, ADAMTS13, TTP.

## INTRODUCTION

Thrombotic thrombocytopenic purpura (TTP) is a rare, life-threatening form of thrombotic microangiopathy which are diseases characterized by thrombocytopenia, microangiopathic haemolytic anaemia (intravascular haemolysis with peripheral blood schistocytes) and microvascular occlusion (George and Nester, 2014). Thrombotic thrombocytopenic purpura is a rare disease with a reported incidence of 3-10 cases per million people (Blombery and Scully, 2014; Zheng and Sadler, 2008). This disease was first described in 1924 by Moschcowitz who reported a 16 year old female with anaemia, fever, leukocytosis, petechiae, heart failure and stroke who died within two weeks. An autopsy done on the case revealed widespread hyaline thrombi in the terminal arterioles and capillaries of the heart and kidney (Zheng and Sadler, 2008; Sadler and Mortimer, 2010). It was not until 1947 that the name TTP was proposed and

adopted (Sadler and Mortimer, 2010; Hovinga and Lammle, 2012).

TTP may be congenital or acquired and arises due to severe deficiency or reduced activity of a disintegrin and metalloprotease with thrombospondin type 1 repeats, member 13 (ADAMTS13) which is a metalloprotease that acts to cleave active ultralarge von Willebrand Factor (vWF) multimers into smaller protein fragments (Blombery and Scully, 2014). The congenital form of TTP is due to mutations in the ADAMTS13 gene causing a deficiency, while the acquired form is as a result of autoantibodies to the ADAMTS13 protein. Risk factors for developing TTP include females, age between 10 – 39 years and black race (George and Al-Nouri, 2012; Sadler and Mortimer, 2010).

vWF is an important large adhesive protein released by the endothelial cells and involved in haemostasis. It

acts as a bridge that is necessary for platelet attachment to the subendothelium, induces platelet aggregation with subsequent thrombus formation at sites of endothelial injury. vWF is released from the endothelium as large multimers and under physiologic conditions, these large multimers are cleaved by ADAMTS13 thereby inhibiting and controlling platelet adhesion and aggregation. In TTP however, ADAMTS13 is lacking and therefore there is unregulated VWF-dependent platelet thrombosis. This leads to formation of widespread micro-thrombi usually involving the myocardium, pancreas, kidney, adrenal gland, and brain while sparing the liver and lungs. Histologically, these micro-thrombi are shown to consist mainly of platelets and vWF with little fibrin. Formation of these widespread micro-thrombi consumes platelets leading to thrombocytopenia, while passage of the red cells through the circulation where these thrombi are shears then, producing the classical feature of schistocytes (red cell fragmentation) in the peripheral blood (Sadler and Mortimer, 2010).

Initially, TTP was diagnosed as a pentad of thrombocytopenia, microangiopathic haemolytic anaemia (MAHA), fever, neurological symptoms and renal impairment. However the classic triad is not always present at diagnosis because about a third of patients do not present with neurological signs while renal impairment and fever are not prominent features of TTP (Scully *et al.*, 2012; Sarode 2014). Although TTP is rare, early diagnosis is essential because it is associated with a high mortality rate of up to 90% which can be reduced dramatically (to about 29%) by timely intervention with plasma exchange therapy (Scully *et al.*, 2012; Blombery and Scully, 2014; Rock *et al.*, 1991). Survival of cases without plasma exchange is said to be only around 10% (George and Al-Nouri, 2012). Other forms of therapy for TTP involve the use of high dose steroids or rituximab and less frequently vincristine, cyclophosphamide, cyclosporine and splenectomy (Barbour *et al.*, 2012).

This is a report of a nineteen year old girl presented with thrombocytopenia, anaemia, neurological symptoms and features of MAHA who was diagnosed with TTP.

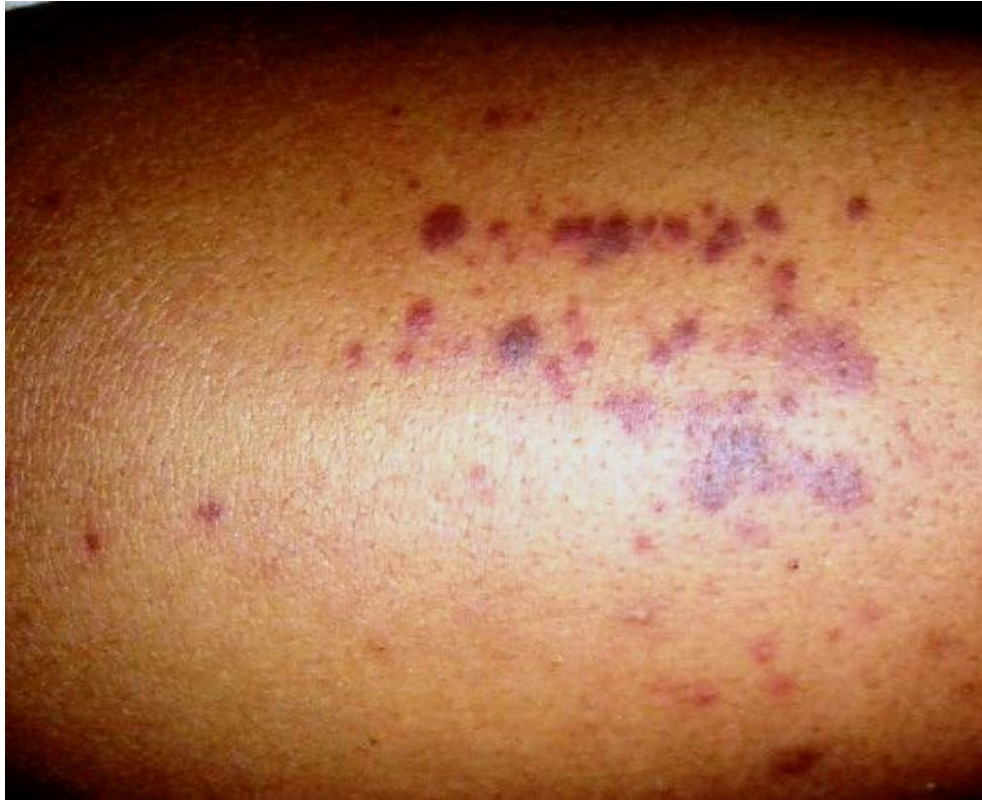## Case report

Miss MN was referred to the haematology clinic due to severe menorrhagia and a low platelet count. She was presented with a history of recurrent dark reddish coloured skin lesions for the previous two months and pain on the right side of her jaw, face and lips; both without any preceding history of trauma. The skin lesions were of varying sizes, not specific to any part of her body. The skin lesions were followed by a history of heavy menstrual blood flow which started about ten days prior to presentation. Patient noticed that the skin lesions seemed to increase in number during her last menstrual cycle about 2 weeks prior to presentation. The pain on the right side of the jaw, face and lips was exacerbated

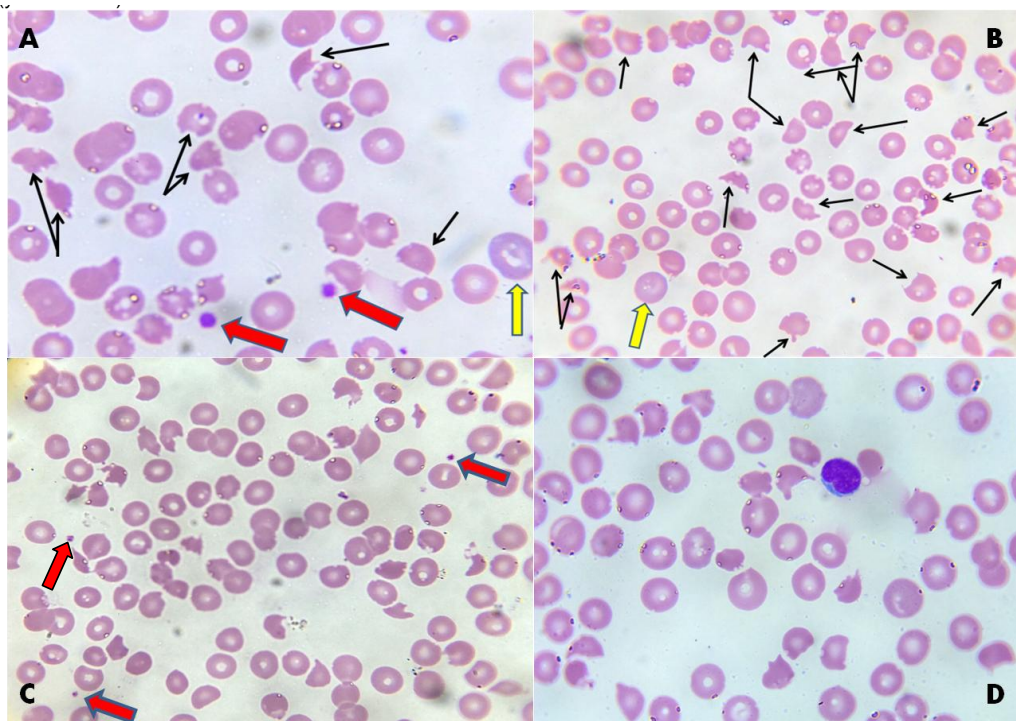
by opening the mouth to swallow and temporarily relieved by paracetamol. The facial pain was not associated with any swelling, lesion or trauma. There was no history of fever, weight loss, night sweats or dysuria. No one in her family had a history of similar illness. Her review of systems was essentially normal. She had never received blood transfusion neither was she a known sickle cell, hypertensive or diabetic patient. She was not on any medication for any medical condition at the time of presentation. On examination, she was moderately pale, anicteric, afebrile (temperature 36.9°C), no pedal edema nor peripheral lymphadenopathy and her weight was 71kg. Her respiratory rate was 27 cycles per minute while pulse rate was 106 beats per minute with a blood pressure of 100/70mmHg. She had multiple petechia and purpura haemorrhages on the back of the neck, anterior and posterior chest wall, abdomen and limbs (*Figure 1*). The examination of the other systems was essentially normal. An impression of bicytopenia (severe thrombocytopenia and anaemia) was made; immune thrombocytopenic purpura (ITP) and acute lymphoblastic leukaemia with central nervous system involvement were listed as possible causes. Investigations ordered for included full blood count (FBC), peripheral blood film, bone marrow aspirate, direct antiglobulin test (DAT) viral screening (for HIV, hepatitis B and hepatitis C), uric acid, lactate dehydrogenase (LDH), serum electrolytes, urea and creatinine, liver functions tests, urine and stool culture. Based on the preliminary diagnosis of ITP, she was immediately placed on high dose steroids (prednisolone 60mg daily) while awaiting the results of ordered investigations.

The results of the investigations when available were as follows; the full blood count showed anaemia (haemoglobin concentration of 8.1g/dL), a normal white cell count of  $6.3 \times 10^9/L$  with a low platelet count of  $31 \times 10^9/L$  (normal reference range for Africans  $100 - 450 \times 10^9/L$ ). The peripheral blood film showed anisopoikilocytosis with numerous schistocytes, some polychromasia and severe thrombocytopenia (*Figure 2*). The white cells were not remarkable. Bone marrow aspirate done revealed a hypercellular marrow, with erythroid hyperplasia, normal granulopoiesis and increased number of megakaryocytes (*Figure 3*). The DAT was negative. Screening for HIV, hepatitis B and C were all negative. The uric acid and LDH parameters were significantly elevated (512  $\mu\text{mol/L}$  and 844 U/L respectively). She had a normal renal functions test; sodium 136mmol/L, potassium 3.7mmol/L, bicarbonate 24mmol/L, urea 4.8mmol/L and creatinine 69 $\mu\text{mol/L}$ . Her liver functions test parameters were all normal. The urine and stool culture did not yield growth of any microorganism.

On review with the above results, the preliminary diagnosis was changed to thrombotic microangiopathy and by exclusion a working diagnosis of thrombotic thrombocytopenic purpura was made at 5 days post

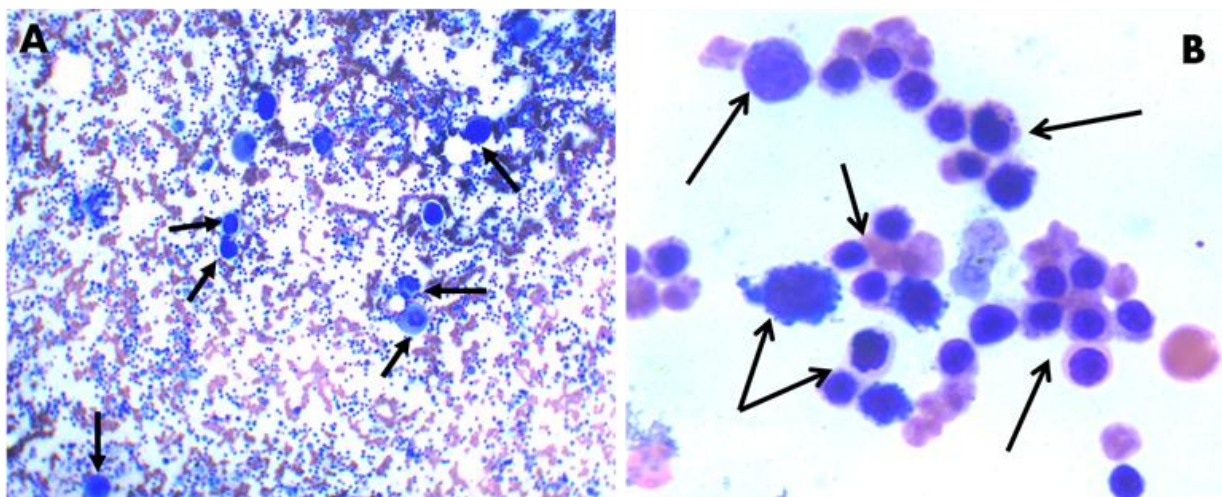


**Figure 1.** A picture of both pin-point petechiae and larger purpura haemorrhages on the lower limb



**Figure 2.** Peripheral Blood Film: **(A)** Several fragmented red cells or schistocytes (black arrows), polychromasia (yellow arrow) and a couple of platelets (red arrows). **(B)** Numerous schistocytes with a polychromatic cell (yellow arrow), there are no platelets on this field. **(C)** Widespread schistocytes with only three platelets on this field. **(D)** Also shows schistocytes; there is a lymphocyte a bit off-centre to the top right, platelets are not present here.





**Figure 3.** Bone Marrow Aspirate (A) Black arrows pointing to several megakaryocytes (both young and mature) which produce platelets (B) Erythroid hyperplasia: a group of erythroid cells at different stages of maturation.

presentation, and ADAMTS13 assay requested for. However, the blood sample for this assay was not taken until 39 days post presentation. In the meantime, it was noted that the petechiae and purpura had resolved while on prednisolone and her next menstrual cycle was not associated with menorrhagia. Serial FBC showed sequentially increasing haemoglobin concentration and platelet counts (*Table 1*). By the 11<sup>th</sup> day on prednisolone, she had achieved a low-normal platelet count ( $130 \times 10^9/L$ ) and her haemoglobin concentration had risen to 11.8g/dL by the 18<sup>th</sup> day. Blood film by day 20 showed a marked reduction in the number of schistocytes and adequate number of platelets on film (*Figure 4*). The result for the ADAMTS13 assay (for which sample was collected on the 39<sup>th</sup> day) was not available until about 9 weeks after (102 days after presentation). The ADAMTS13 value was 14% (normal >50%). This confirmed the diagnosis of TTP. The patient and her relatives were counseled on her diagnosis, treatment options, risk for relapse and the need for long-term follow up.

From 6 weeks on prednisolone, the dose was gradually tapered off for a period of 4 weeks and thereafter prednisolone was stopped. As of the time of this report, patient has been on routine follow up for over 9 months and has been clinically stable, with normal laboratory parameters.

## DISCUSSION

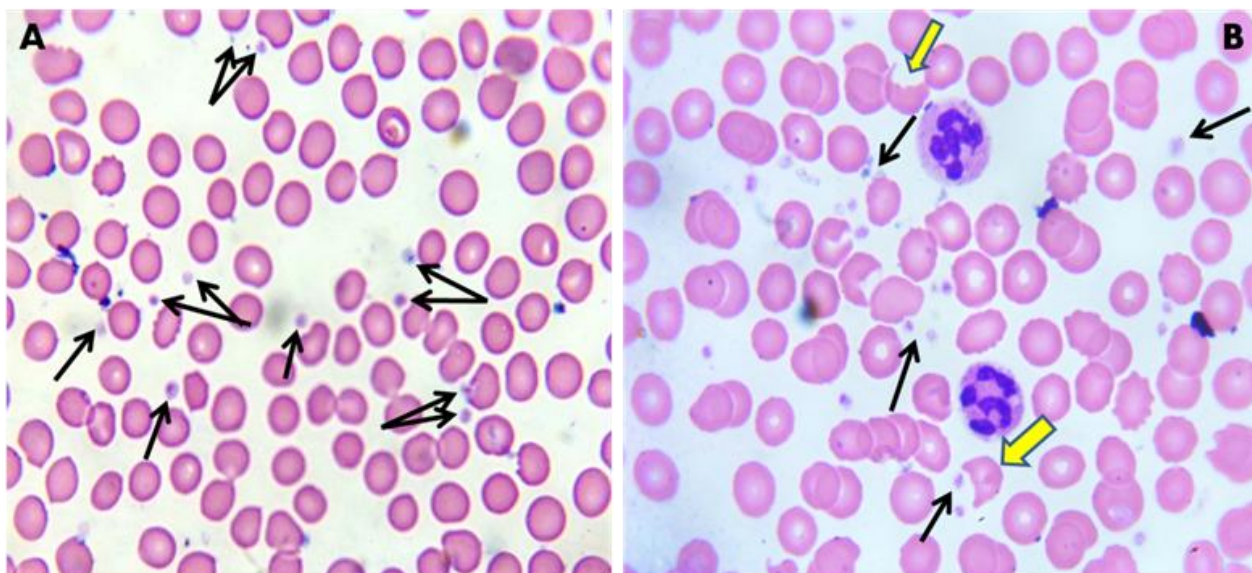
Thrombotic thrombocytopenic purpura is a rare disease which causes a thrombotic microangiopathy. Although this disease is rare, a high index of suspicion is required to make a diagnosis as it is associated with a very high mortality rate if not managed properly. Diagnosis is made even more confusing as the clinical and laboratory

features of TTP are not specific for TTP and therefore in practice, other more common differential diagnoses may be considered before TTP. A preliminary diagnosis of immune thrombocytopenic purpura was made, but patients with ITP usually do not have remarkable schistocytes in their peripheral blood, also the direct antiglobulin test was negative ruling out possible Evan's syndrome. Due to presenting with anaemia, purpura, petechiae and neurological symptoms, a provisional diagnosis of an acute leukaemia with central nervous system involvement was also entertained. However on peripheral blood film or in the bone marrow, there were no blasts as expected in acute leukaemia (and the white cell count was within normal). Rather, because the blood film showed characteristic schistocytes of MAHA coupled with polychromasia and thrombocytopenia this led to the differential diagnosis of a thrombotic microangiopathy. Other types of TMAs are haemolytic uraemic syndrome (HUS), atypical haemolytic uraemic syndrome (aHUS) and secondary TMA due to drugs, cancers, etc occur more frequently. However, in this patient there was no preceding history of bloody diarrhoea which is usually seen in HUS, neither did she have renal impairment which is also a common feature of HUS. She had not been on any drugs. She did not have cancer. Therefore, by exclusion, a preliminary diagnosis of the rare TTP was made.

Ideally, with a high index of suspicion, samples for analysis of ADAMTS13 should be taken from the patient at presentation but due to financial reasons and availability of testing for ADAMTS13 which had to be done at a reference laboratory, testing for ADAMTS13 was not done until about the 39th day of therapy with high dose steroids (prednisolone). Severe ADAMTS13 deficiency occurs when the value is <10% (normal >50%). The index case had a value of 14% at the time of testing when steroid therapy had already begun. It is

**Table 1.** Serial full blood count

Day of Presentation	Hb conc.	PCV	WBC	WBC Differential Count					Platelets
				Neut.	Lymph.	Mono.	Eosino.	Baso.	
Day 1	8.1	25	6.3	56.7	34.3	5.3	3.3	0.4	31
Day 11	10.5	30	14.4	70.5	21.2	6.7	1	0.6	130
Day 18	11.8	35	9.7	54.1	37.8	5.7	1.6	0.8	165
Day 65	14.4	45	15.1	82	11.8	4.7	0.7	0.8	349
Day 80	13.8	42	4.3	58.4	36.1	2.3	2.8	0.4	293
Day 136	12.9	38	4.7	56.5	33.3	6.9	2.6	0.7	310



**Figure 4.** Peripheral blood film showing response to steroid **(A)** Black arrows pointing to reduced number of schistocytes and increased number of platelets on film compared to blood film at presentation in Fig.2 above. **(B)** Although a few schistocytes are still present (yellow arrows), they are significantly reduced on film, with platelets in adequate number (black arrows point to some platelets). There are 2 neutrophils on the film.

therefore possible that if ADAMTS13 testing was done *ab initio* at presentation, the value may have been <10% (George and Al-Nouri, 2012) and this would be a case of severe deficiency especially taking into consideration her presentation of widespread petechiae and purpura, menorrhagia, severe thrombocytopenia of  $31 \times 10^9/L$ , anaemia (Hb of 8.1g/dL) and marked schistocytes on the peripheral blood film. Although this patient had deficiency of ADAMTS13, it was not proven if she had congenital TTP due to mutations in the ADAMTS13 gene or if hers was a case of acquired TTP due to autoantibodies to ADAMTS13. It is possible that since she was presenting for the first time at age 19 that it is most likely the acquired form she has.

Plasma exchange is far superior to plasma infusion in reducing the mortality in patients with TTP. Prior to this, patients with TTP had been treated with whole blood transfusions and later, plasmapheresis with plasma infusions (Sadler and Mortimer, 2010). In a developing country with limited availability of apheresis, performing plasma exchange for the patient was not feasible. Also, at the time of presentation, TTP because

of its' rare nature was not initially considered. Moreover, she achieved a remarkable response to steroid with a rapid increase in platelet count and haemoglobin concentration and did not require transfusion or plasma exchange thereafter.

This case report is to document this rare disease in our environment which was successfully managed with high dose steroid.

## REFERENCES

- Barbour T, Johnson S, Cohn S, Hughes P (2012). Thrombotic microangiopathy and associated renal disorders. *NDT Perspectives. Nephrol Dial Transplant*: 27: 2673–2685 doi: 10.1093/ndt/gfs279
- Blombery P, Scully M (2014). Management of thrombotic thrombocytopenic purpura: current perspectives. *Journal of Blood Medicine*. 5:15-23. doi:10.2147/JBM.S46458.
- Evan Sadler J, Mortimer P (2010). Antibody mediated thrombotic disorders: thrombotic thrombocytopenic purpura and heparin-induced thrombocytopenia. In: Lichtman M, Kipps T, Seligsohn U, Kaushansky K. and Prchal J. (eds), *Williams Hematology*, 8e, Part XII: Hemostasis and Thrombosis, 8th ed. McGraw-Hill, London and New York, Chapter 133.

- George JN, Al-Nouri ZL (2012). Diagnostic and therapeutic challenges in the thrombotic thrombocytopenic purpura and hemolytic uremic syndromes. *ASH Education Book*. December 8, vol. 2012 no. 1 604-609
- George JN, Nester CM (2014). Syndromes of Thrombotic Microangiopathy. *N Engl J Med*; 371:654-666 August 14, 2014 DOI: 10.1056/NEJMra1312353
- Hovinga JAK, Lammle B (2012). Role of ADAMTS13 in the pathogenesis, diagnosis, and treatment of thrombotic thrombocytopenic purpura. *ASH Education Book*. December 8, Vol. 2012 no. 1 610-616
- Rock GA1, Shumak KH, Buskard NA, Blanchette VS, Kelton JG, Nair RC, Spasoff RA (1991). Canadian Apheresis Study Group. Comparison of plasma exchange with plasma infusion in the treatment of thrombotic thrombocytopenic purpura. *N Engl J Med*.325(6):393-397
- Sarode R, Bandarenk N, Brecher ME, Kiss JE, Marques MB, Szczepiorkowski ZM, Winters JL (2012). Thrombotic thrombocytopenic purpura: American Society for Apheresis (ASFA) consensus conference on classification, diagnosis, management, and future research. *J. Clin. Apheresis*, 2014 29: 148–167. doi: 10.1002/jca.21302
- Scully M, Hunt BJ, Benjamin S, Liesner R, Rose P, Peyvandi F, Cheung B, Machin SJ (2012). British Committee for Standards in Haematology. Guidelines on the diagnosis and management of thrombotic thrombocytopenic purpura and other thrombotic microangiopathies. *Br J Haematol*. 2012 Aug;158(3):323-35. doi: 10.1111/j.1365-2141.09167.x. Epub 2012 May 25.
- Zheng XL, Sadler JE (2008). Pathogenesis of Thrombotic Microangiopathies. *Annual review of pathology*.3:249-277. doi:10.1146/annurev.pathmechdis.3.121806.154311.

How to cite this article: Korubo KI (2016). Thrombotic thrombocytopenia purpura in a Nigerian girl. *Int. Inv. J. Med. Med. Sci.* Vol. 3(4): 62-67