

Case Report

A neonate of Prune-Belly Syndrome for Sigmoid loop colostomy and Suprapubic cystostomy: A challenge for the Anaesthesiologist

^{*1}Dr Pratibha Jain Shah (MD (Anaesthesiology), FIPM), ²Dr Vishal Jain, ³Dr K K Sahare, ⁴Dr Neha Chandrakar's

¹Pain Physician, BLS/ACLS Instructor, Associate Professor, Dept of Anaesthesiology and Critical Care, Pt J.N. M. Medical College, Raipur (C.G.) – 492001

²Assistant Professor, Dept of Radiology, Pt J N M Medical College, Raipur

³Professor & Head, Dept of Anaesthesiology; Critical Care, Pt J N M. Medical College, Raipur

⁴Senior Resident, Dept of Anaesthesiology; Critical Care, Pt J N M. Medical College, Raipur

Abstract

We describe the successful anaesthetic management of three days old pre-term male baby of Prune-Belly syndrome (PBS), presented with breathlessness, lax wrinkled abdominal wall with distended abdomen, not passing urine/ motion, bilateral undescended testis and absence of anal opening since birth underwent sigmoid loop colostomy and suprapubic cystostomy. PBS a rare congenital anomaly (1 in 40,000 births), that is associated with a distinctive set of physical problems like deficient abdominal musculature, bilateral cryptorchidism and urinary tract anomalies that a child is born with. Patient of PBS undergo a myriad of surgical procedure either to diagnose or to treat associated problems. Respiratory and urinary complications are the leading cause of perioperative morbidity in these patients. Problems associated with PBS which may confront an anaesthesiologist are discussed in a case report.

Keywords: Prune Belly Syndrome; Anaesthesia management; Complications.

INTRODUCTION

Prune belly syndrome (PBS) is a figurative term coined by Osler for the wrinkled appearance of the abdomen, like a prune, resulting from agenesis of abdominal musculature. Parker (1895) noted the triad of congenital anomalies associated with PBS (cryptorchidism, deficient abdominal wall musculature and urinary tract anomalies). Originally, it was described by Frohlich in 1839, this triad doesn't mean the total spectrum of the syndrome, it may also involve cardiopulmonary, gastrointestinal, musculoskeletal and CNS (Israel, 2009; Herman and Siegel, 2009; Kristoff et al., 2012; Hassett et al., 2012; Akdag et al., 2015). It may also be referred as Eagle-Berrett syndrome, triad syndrome, abdominal musculature deficiency syndrome and mesenchymal

dysplasia syndrome (Israel, 2009; Hassett et al., 2012). The prognosis may vary from stillbirth to a normal life expectancy depending on the degree of pulmonary and renal compromise; mortality is 20% within first month and 50% within 2years (Hassett et al., 2012, Stoelting et al., 2008). Major cause of morbidity in PBS is recurrent urinary and pulmonary complications that require meticulous preoperative monitoring, antibiotic coverage, active pulmonary physiotherapy and avoidance of any respiratory depressant drugs (Israel, 2009; Kristoff et al., 2012; Stoelting et al., 2008; Holder, 1989). The various perioperative problems which we had encountered in PBS are discussed.

CASE REPORT

A three day old, 2.5kgs pre-term male child presented with breathlessness, lax wrinkled abdominal wall with

*Corresponding Author Email: prati_jain@rediffmail.com

distended abdomen, not passing urine/ motion, bilateral undescended testis and absence of anal opening since birth. It was home delivery and already received BCG and Polio vaccination. The patient was diagnosed as PBS and scheduled for colostomy and suprapubic cystostomy.

Preoperatively, baby was dull, pale, responding to pain, dyspneic using accessory muscles with very poor GC, RR 30-35/min, SPO₂-91-95%, PR-150/min, bilateral diminished air entry, distended abdomen with visible dilated bowel loops, loose redundant skin and bilateral empty scrotal sac. (Figure 1) Except low Hb (8 gm %), other investigations, especially serum creatinine, serum electrolyte, BT, CT were within normal limits. X-ray chest and abdomen revealed mild pleural effusion with dilated fluid filled bowel loops. USG abdomen showed lax abdominal wall with grossly dilated fluid filled bowel loops with free fluid in between, mild right sided pleural effusion, distended urinary bladder and bilateral hydronephrosis. He was under IV antibiotics coverage.

After taking informed high risk consent from parents, baby was shifted to OT and placed on a warm blanket. Multipara (Phillips MP20) monitor and precordial stethoscope was attached. Stomach was decompressed with Ryle's tube. Following premedication with IV Atropine 0.2mg and preoxygenation, induction was done with O₂: N₂O (1:2) and sevoflurane (up to 4-6%) through 0 size facemask and trachea was intubated (3mm ID plain ETT) effortlessly. Anaesthesia was maintained with O₂:N₂O (1:2) and sevoflurane (1.5-2%) with IPPV. Thereafter, 4ml 0.125% Bupivacaine was injected into caudal epidural space for intraoperative and postoperative analgesia. 30ml warm Isolyte P and 20ml blood was infused intraoperatively. All the vitals remained stable throughout the operation, lasting 2hrs.

After completion of surgery, child was shifted to NICU for ventilatory support until adequate spontaneous respiratory efforts. On 2nd post-operative day, trachea was extubated. IV Ketorolac 1.25mg 8hrly was given intravenously for postoperative analgesia. All vitals including temperature were maintained. Chest physiotherapy, saline nebulization and antibiotic coverage continued in post-operative period to prevent pulmonary and urinary complications. The post-operative course was uneventful.

DISCUSSION

PBS is a rare, male predominant congenital syndrome (1:40,000 births), rarely occur in female with anomalies of uterus and vagina (Israel, 2009; Kristoff et al., 2012; Hassett et al., 2012; Akdag et al., 2015; Stoelting et al., 2008; Holder, 1989). There are no obvious racial predilections, but common with twin pregnancies, trisomy 18 and 21. The etiology and pathogenesis of PBS is not yet fully understood. The embryological theory suggests an aberration of mesenchymal

development at around 6-10th weeks of gestation affecting the abdominal wall musculature, mesonephric and paramesonephric ducts whilst others consider the distal urinary tract obstruction at the junction of the glandular and penile urethra as the first underlying mechanism that leads to oligohydramnios and congenital pulmonary hypoplasia (Kristoff et al., 2012; Wood et al., 2007; Wheatley et al., 1996).

All male PBS patients have cryptorchidism, Malrotation and anal atresia are frequently seen. Our case had cryptorchidism too and anal atresia. Urological disorder in PBS varies from simple dilatation or obstruction to renal dysplasia (Israel, 2009; Akdag et al., 2015; Stoelting et al., 2008; Holder, 1989; Wood et al., 2007; Seidel et al., 2015) Affected individuals are prone to urinary tract infections and subsequent renal failure. Thus, preoperative evaluation of renal function is must especially radiological evaluation for description of disease. The dilatation of urinary tract in utero results in varying degree of pressure atrophy of the abdominal wall musculature from a deficiency to a complete absence. In extreme cases, layering of the intestines and even peristalsis can be seen beneath the skin.

Ineffective coughing due to combined effect of pulmonary hypoplasia, absent abdominal musculature, relative flat diaphragm, chest deformity make PB patients prone for aspiration pneumonitis, recurrent chest infection and atelectasis. Thus preoperative chest x-ray and history of cyanosis is important to rule out problem with oxygenation or severe cardiopulmonary reserve (Stoelting et al., 2008; Holder, 1989; Wood et al., 2007; Seidel et al., 2015). (Flow chart-1)

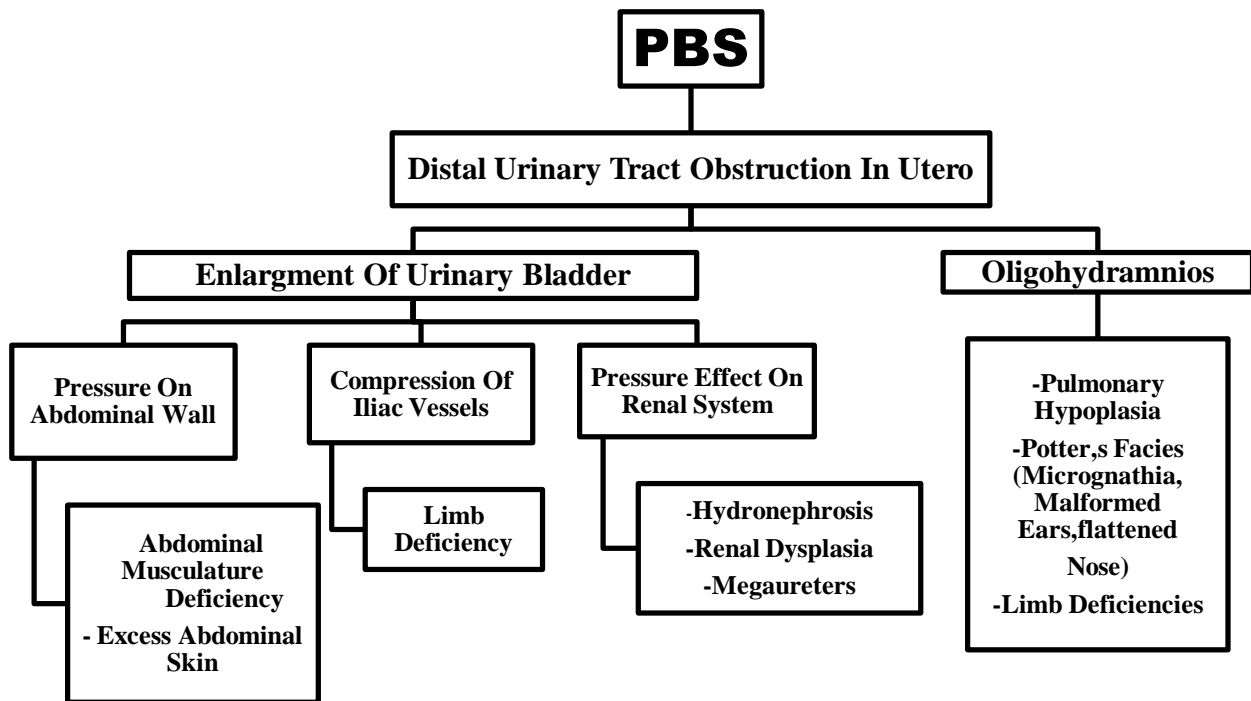
Oligohydramnios sometimes results in limb deficiencies due to compression of iliac vessels by enlarged bladder and characteristic Potter's facies (Israel, 2009; Kristoff et al., 2012; Akdag et al., 2015; Holder, 1989; Seidel et al., 2015). Laryngeal atresia and difficult intubation have also been reported. Other associated musculoskeletal problems are club foot, dislocation/ dysplasia of hip, arthrogryposis, pectus excavatum. Fallot's tetralogy and septal defects are common, requiring prophylactic antibiotic coverage. Malrotation of gut, imperforate anus, omphalocele and hirschsprung disease are also common which increases the risk of reflux and regurgitation (Holder, 1989; Bosenberg, 2004; Yoon et al., 2014). Thus characteristic presentation of PBS prompts complete head to toe physical assessment and diagnostic evaluation (Wood et al., 2007).

The nature of genitourinary disease and associated congenital anomalies may obviate the need for surgical intervention, either correction or palliation, as early as in neonatal period (Akdag et al., 2015; Holder, 1989; Seidel et al., 2015; Dénes et al., 2004). Thus associated major organ disease, surgical procedure to be performed and age of the patients influence the anaesthesia plan in PBS.

Premedication with sedatives were avoided because

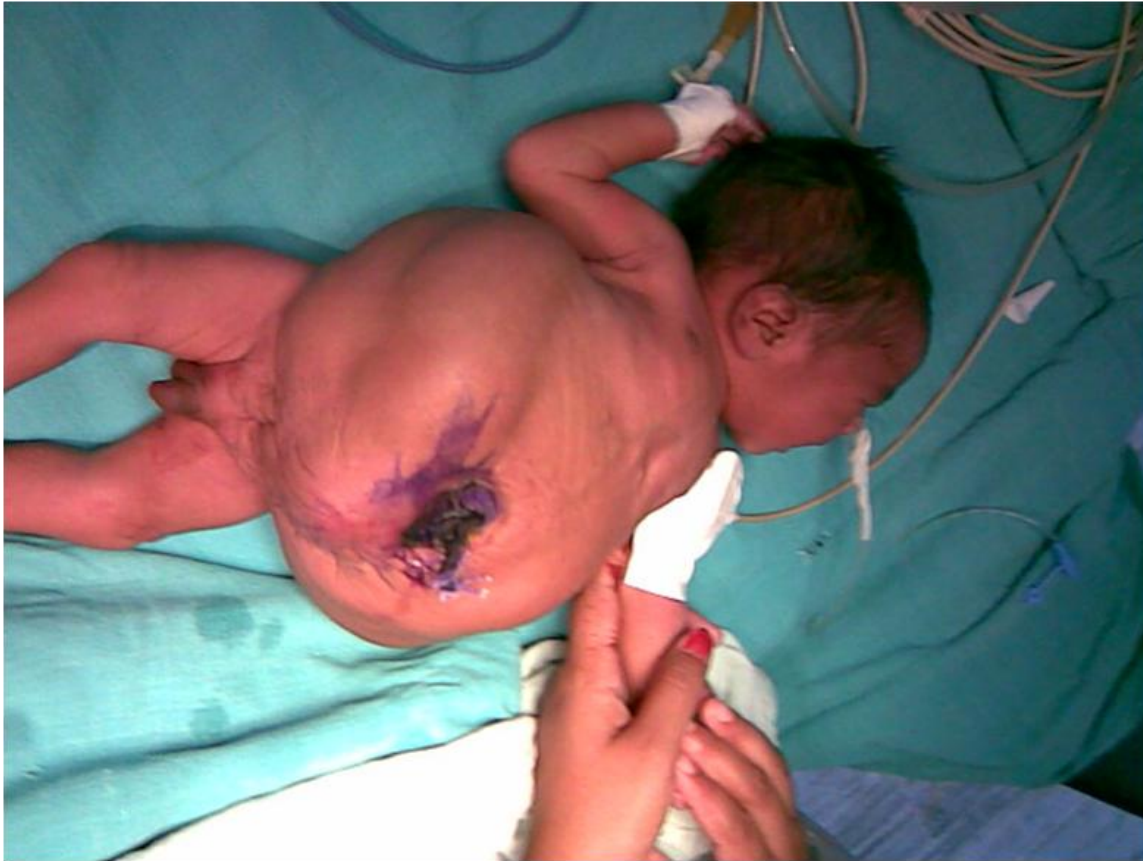

Figure 1. PBS



Flow Chart 1. PATHOPHYSIOLOGICAL CHANGES IN PRUNE-BELLY SYNDROME

of compromised respiration. If necessary, sedatives should be administered under close observation (Israel, 2009; Bosenberg, 2004; Yoon et al., 2014). Atropine and opioids cause urinary retention and thus should be avoided in voiding studies (Israel, 2009).

Induction of anaesthesia may be a tedious task considering the vast number of associated anomalies. Various sizes and type of masks are necessary, since the possible presence of potter's facies may prevent a snug mask fit (Holder, 1989; Wood et al., 2007; Seidel et al., 2015). Adequate preoxygenation is germane to an uneventful anaesthetic induction in patient having compromised respiration. Sevoflurane could be the best choice due to fast induction and recovery. Securing airway is a priority to reduce the risk of regurgitation. In PBS, respiration mainly depends on accessory muscles due to abnormal abdominal musculature and deficient diaphragmatic function. Following induction of anaesthesia, decreases activity of accessory muscles lead to severe paradoxical respiration and make IPPV mandatory. Lax abdominal wall and risk of residual paralysis obviates the need of muscle relaxant. The response to muscle relaxant is said to be normal, but can be prolonged in patient on aminoglycosides or with compromised renal function (Israel, 2009; Stoelting et al., 2008; Holder, 1989; Bosenberg, 2004; Yoon et al., 2014).

Proper positioning of the PBS must be advocated, because of likelihood of hip dysplasia or dislocations due to associated musculoskeletal problems. Vigilant monitoring is mandatory for early detection and treatment of problems. Fluid management is of particular concern if extensive surgery is planned, especially in presence of renal insufficiency. Otherwise one should follow the prescribed paediatrics guidelines (Israel, 2009).

Though the patient described in this case report was very sick but was fortunate in not having major body organ involvement or difficulty in intubation. Caudal epidural block was performed for intra and postoperative analgesia to obviate the need of narcotics/ sedative. Heisler et al., 2007 used thoracic epidural for pectus excavation repair for intraoperative analgesia (Akdag et al., 2015)

Postoperative period is also very crucial, requires prudent judgment and skill, as they are prone to develop respiratory insufficiency and infection. Postoperative ventilatory support, chest physiotherapy, nebulization, intermittent tracheal suctioning and antibiotic coverage are mandatory to avoid retention of secretions and atelectasis. Analgesics should be used cautiously because postoperative restlessness might be due to hypoxia from hypoventilation and, if mistaken from the effect of pain, the further analgesic administration could lead to additional respiratory depression (Israel, 2009; Holder, 1989).

CONCLUSION

PBS is a rare congenital anomaly, presented with a wide spectrum of severity and need multidisciplinary management. That needs in-depth knowledge of pathophysiology of complex syndrome, individual preoperative evaluation and preparation for successful anaesthetic management.

REFERENCES

- Akdag A, Arici S, Orhaner B, Dogan A (2015). Prune belly syndrome associated with bilateral multicystic dysplastic kidneys and urethral obstruction: A case report. *Ped Urol Case Rep*; 2 (4): 13-16.
- Wood AG, Brandem DH, Merritt L (2007). Prune-Belly Syndrome: A focused physical assessment. *Advance in Neonatal Care* June; 7 (3): 132-143.
- Bosenberg A (2004). Anaesthesia for prune belly syndrome: treatment. *South African J of Anaesthesia & Analgesia* May; 10-11.
- Dénes FT, Arap MA, Giron AM, Silva FA, Arap S (2004). Comprehensive surgical treatment of prune belly syndrome: 17 years' experience with 32 patients. *Urology* Oct; 64 (4): 789-93.
- Hassett S, Smith GH, Holland AJ (2012). Prune- Belly syndrome. *Pediatr Surg Int*; 28: 219-228.
- Heisler DB, Lebowitz P, Barst SM (2007). Pectus excavatum repair in a patient with prune belly syndrome Pediatric Anesthesia 01/2007; 4(4):267- 269
- Herman TE, Siegel MJ (2009). Prune belly syndrome. *J Perinatol*; 29 (1): 69-71.
- Holder JP (1989). Pathophysiologic and anaesthetic correlations of the prune belly syndrome. *AANA J*; 57(2):137-41.
- Israel F (2009). Prune-Belly Syndrome. *eMedicine Urology*, last updated: Oct 29.
- Kristoff V, Gregory VE, Veerle DB, Paul W (2012). The prune belly syndrome: report of a rare case and review of literature. *European Journal of Plastic Surgery*; 35: 241-243.
- Stoelting RK, Hines RL, Marschall KE(2008). Stoelting's anesthesia and co-existing disease. *Skin & musculoskeletal diseases*, 5th ed : 463.
- Seidel NE, Arlen AM, Smith EA, Kirsch AJ (2015). Clinical manifestations and management of prune-belly syndrome in a large contemporary pediatric population. *Urology*; 85 (1): 211-15.
- Wheatley JM, Stephens FD, Hutson JM (1996). Prune-belly syndrome: ongoing controversies regarding pathogenesis and management. *Semin Pediatr Surg*. May; 5 (2): 95-106.
- Yoon J, Ryu J, Kim J, Jeong CY, Park SG (2014). Anesthetic experience of a patient with Prune-belly syndrome. *Korean J Anesthesiol.*; 67 (Suppl): S94-5.

How to cite this article: Shah PJ (2015). A neonate of Prune-Belly Syndrome for Sigmoid loop colostomy and Suprapubic cystostomy: A challenge for the Anaesthesiologist. *Int. Inv. J. Med. Med. Sci.* Vol. 2(9): 131-134