

**A rare case of mixed gonadal dysgenesis: 45, X0/ 46, X, +mar 1/ 46, X, +mar 2**

**Carolina Talini<sup>1</sup>, Leticia Alves Antunes<sup>1</sup>, Bruna Cecília Neves de Carvalho<sup>1</sup>, Taís Soares de Carvalho<sup>1</sup>, Anne Twadowsky Didonato<sup>2</sup>, Veruska Peron<sup>2</sup> Karin Lucilda Schultz<sup>1</sup>, Maria Helena Camargo Peralta del Valle<sup>1,2,3</sup>**

<sup>1</sup>Department of Pediatric, Hospital Pequeno Príncipe, Curitiba/PR, Brasil

<sup>2</sup>Course of Medicine, Universidade Positivo, Curitiba/PR, Brasil

<sup>3</sup>Department of Pediatric, Universidade Federal do Paraná, Curitiba/PR, Brasil

**Abstract**

This study aims to report a rare case of mixed gonadal dysgenesis with mosaicism pattern 45 X0 / 46, X, +mar 1/ 46, X, +mar 2. Patient referred to the pediatric urology service with 2 months of age. Right after the baby was born it was not possible to determine the baby's gender. The karyotype was inconclusive: 45, X0. Contrast genitography and ureterocystogram showed a single perineal orifice below the micropenis and between the bifid scrotum, opacification of the bladder with male aspect urethra during urination and short penile urethra. There was also opacification of the posterior vaginal cavity with low junction to the posterior urethra and a linear opacity image suggesting uterine canal. Laparoscopy revealed bilateral gonadal bands and spermatic elements entering the inguinal canal. Müllerian derivatives were absent. Gonadal biopsy was performed and concluded that these were abnormal infantile testes. Microarray testing took a few months and resulted in: 45 X0 / 46, X, +mar 1/ 46, X, +mar 2. Patient was kept on topic androstenedione for 6 months and then underwent penoscrotal hypospadias correction. Mosaic chromosomal pattern is a rare condition that can present with a wide variety of phenotypes. Early recognition has important implications on these patients' social and psychological life and also for their proper management.

**Keywords**

Mixed gonadal dysgenesis; ambiguous genitalia; mosaicism; mar+2.

Copyright © 2016 [pediatricurologycasereports.com](http://www.pediatricurologycasereports.com).

**Corresponding Author:**

Maria Helena Camargo Peralta del Valle  
Universidade Federal do Paraná, Curitiba/PR, Brasil

E-mail: [mhperalta@gmail.com](mailto:mhperalta@gmail.com)

Accepted for publication: 23 May 2016

## Introduction

Gonadal dysgenesis consists of 46, XY gonadal dysgenesis, mixed gonadal dysgenesis (MGD), and 45, X Turner syndrome. It refers to a variety of clinical situations in which abnormal development of the fetal gonad is detected [1,2]. MGD is a sexual development disorder in which there is a differentiated gonad on one side and a streak testis (usually intra-abdominal) or a streak gonad on the other side associated or not to persistence of Müllerian structures – ovary and uterus. At birth, only 4-7% of newborns with sexual development disorders have ambiguous genitalia and indetermined gender [3]. In physical examination, cryptorchidism and/or hypospadias can be found. Therefore, a chromosomal study via karyotyping is necessary in patients who have hypospadias associated with cryptorchidism [4]. Different clinical presentations and variable cromossomic abnormalities emphasize the importance of a multidisciplinary approach to establish early diagnosis, gender definition and prevention of mental and social long term sequel [5].

This study aims to report a case that differs from the others in literature as it is a rare case of chromosomal mosaicism that has only been reported in literature once.

## Case Reports

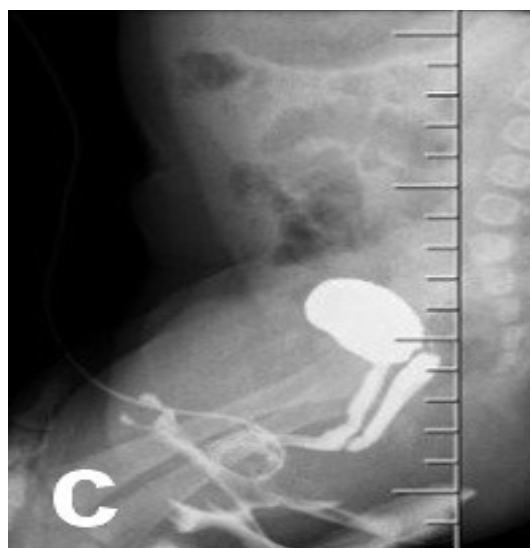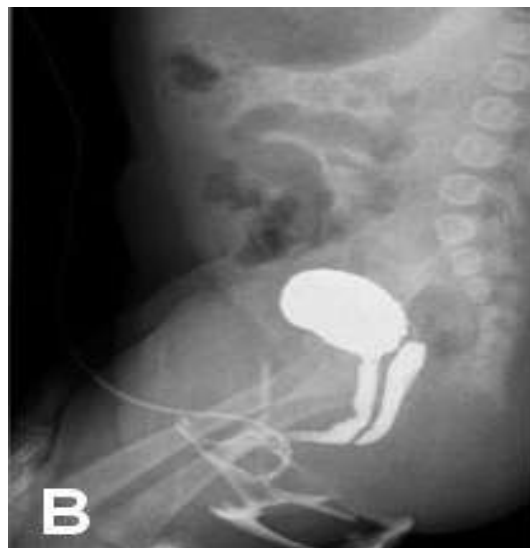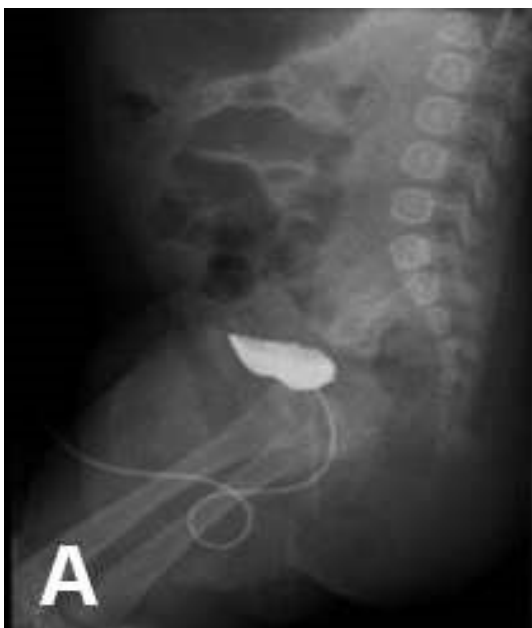This patient was first referred to our pediatric urology service at the age of 2 months. His weight at birth was 1.900 g at 36 weeks of gestation. During pregnancy three different morphologic obstetric ultrasound studies described the fetus as a female. Two days before delivery, another ultrasound study described the baby as a male. Immediately after the baby was born it was not possible do determine the baby's gender.

The first physical examination at our institution showed micropenis measuring 2,5cm, penoscrotal hypospadias, right gonad palpable at bifid scrotum and left gonad palpable in the inguinal canal [Fig. 1].



**Fig. 1.** Genitalia aspect at first admission.

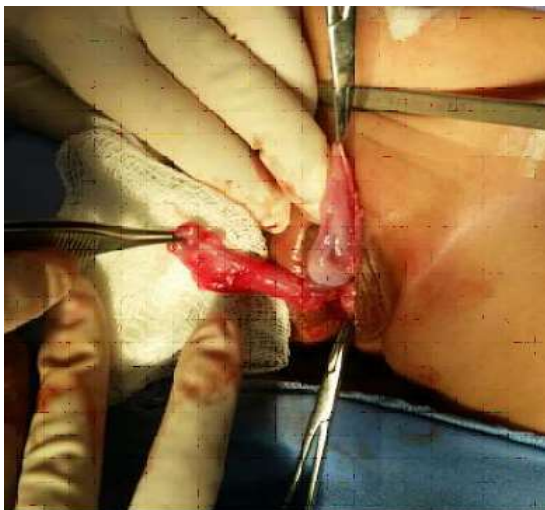
In order to establish this patient's gender, several diagnostic tests were performed. Karyotype analysis was inconclusive: 45, X0. Hormonal laboratory tests excluded congenital adrenal hyperplasia. Contrast genitography and urethrocytogram were performed. These studies showed a single perineal orifice below the micropenis and between the bifid scrotum, opacification of the bladder with male aspect urethra during urination and a short penile urethra. There was also opacification of the posterior vaginal cavity with low junction to the bulbar urethra and a linear opacity image suggesting uterine canal. No fistulous path to the rectum was present [Fig. 2A,B,C].



**Fig. 2.** (A, B, C) Urethrocytogram and genitography.

The initial chosen approach was laparoscopy, which revealed a rudimentary uterus, bilateral gonads and spermatic elements entering the inguinal canal. Other Müllerian derivatives (ovaries) were absent.

Gonadal biopsy was performed and concluded that these were abnormal infantile testes [Fig. 3].



**Fig. 3.** Gonadal biopsy – infant.

After counseling with the family and a multidisciplinary team, the decision was made to pronounce the patient male gendered. The patient was discharged with topical androstenedione prescription while awaiting for the microarray result that revealed: 45 X0 / 46, X, +mar 1/ 46, X, +mar 2. One month after hospital discharge the patient returned to the clinic presenting a 1 cm phallus enlargement. He remained using topical hormone formulation for 6 months and then underwent hypospadias correction by Duckett technique. He developed a small fistula that was surgically corrected six months after the hypospadias initial surgery.

## Discussion

Infants born with ambiguous genitalia as a result of sexual differentiation abnormalities are a highly social and medical emergency. The 4 major pathological groups of patients with ambiguous genitalia are congenital adrenal hyperplasia, male pseudohermaphroditism, mixed gonadal dysgenesis, and true hermaphroditism [6]. Early diagnosis and evaluation of patients with these syndromes are critical for the prevention of psychological effects as well as to rule out other abnormalities. In this instance, a complete and careful medical evaluation and genetics counseling of newborns referred to nurseries is necessary to avoid any delayed or insufficient diagnosis, and to provide medical, surgical and psychological intervention in children with guardians other than their biological parents. Additionally, the presence of other congenital and/or genetic abnormalities must also be evaluated [2,5].

Sexual differentiation is a complex process, and the SRY (sex-determining region of the Y chromosome), gene is extremely critical within this cascade of events. The Y chromosome contains the SRY which induces male sex development during embryogenesis, especially the development of the testes. These begin to be morphologically identified between the

seventh and eighth week. In this process, the Sertoli cells are the first to become recognizable. These are organized as cells surrounding tubules and produce the Müllerian inhibiting factor (MIF), a hormone that through local diffusion leads to regression of the Müllerian duct derivatives (which would originate the uterus, uterine tubes and proximal vagina) [7,8]. Leydig cells produce testosterone which induces Wolff ducts to differentiate into epididymis, vas deferens, seminal vesicles and ejaculatory duct. In most distant urogenital tissues, such as the genital tubercle, conversion of testosterone into dihydrotestosterone by the enzyme 5-alpha-reductase is required. In the absence of the SRY or in the presence of a second X chromosome, ovaries develop. This then determines the gonadal sex [9,10]. In cases with a 45,X chromosomal line, the lack of a second X chromosome lead to the development of streak gonads, because a second X chromosome is essential for full development and functioning of the ovaries [7].

The mosaicism pattern found in this patient is a rare type that has only been reported once in literature. Mosaicism is defined as the presence of two or more chromosomal lineages in the same individual, in most cases of 45,X/46,XY mosaicism, the cause is

suggested to be the loss by nondisjunction of the Y chromosome after normal disomic fertilization [11]. The different distributions of the 45,X and 46,XY chromosomal cell lines among the tissues in individuals with this mosaicism presumably reflect the wide variety of phenotypes observed, not only in our patient but also in the literature [12].

In postnatal studies, the most common clinical presentation of 45,X/46,XY mosaicism is ambiguity of the external genitalia. This phenotype is usually associated with two dysgenetic testes or with a streak gonad and a contralateral dysgenetic testis [13]. Although close monitoring of patients with 45,X/46,XY mosaicism is essential, there is unfortunately no consensus on what the best form of management should be [12,13]. Three components are very important in order to provide adequate treatment – gender identity, gender role and sexual orientation that may or may not be congruent. Several factors are involved in this process, but the degree of virilization of the external genitalia and the presence of gonads with testicular features in the labioscrotal folds stand out among them [12]. The parents' impression is another factor that should be taken into consideration [14,15]. There is a very high incidence of malignant tumor development in the dysgenetic gonads

(50%). Gonadoblastoma is the most common tumor; but seminoma and dysgerminoma can be seen, especially in the streak gonads [16]. Hence, Das et al recommend bilateral gonadectomy in all patients with mixed gonadal dysgenesis [6]. Thus, the risk of developing cancer and its management should also be assessed irrespective of the choice of gender. Individuals who are well virilized and present gonads in the labioscrotal folds present the best conditions for choosing male sex of rearing [17,18]. As a result of the choice of a multidisciplinary approach and the parents, reconstruction of penoscrotal hypospadias was done using the Duckett technique. Excision of mullerian structures (vaginal cavity and uterine canal) is planned.

### Conclusion

Mosaic chromosomal pattern is a rare condition that can present with a wide variety of phenotypes resulting from involvement of different aspects of the

### References

1. Berkovitz GD, Fechner PY, Zacur HW, et al. Clinical and pathologic spectrum of 46,XY gonadal dysgenesis: its relevance to the understanding of sex differentiation. *Medicine (Baltimore)*. 1991;70(6):375-83.

individual, such as growth, hormone balance, gonadal development, sex of rearing and fertility. Early recognition has important implications on these patients' social and psychological lives and also for their adequate management. The treatment of these anomalies needs a multidisciplinary approach involving the endocrinologist, neonatologist and pediatric urologist. At the same time, while assigning sex to a child with ambiguous genitalia, the karyotype, the phenotype, mental sex and the parental wishes should be given due consideration. The treatment and the choice of gender should be individualized on the basis of these factors.

### Acknowledgements

The author(s) declare that they have no competing interests and financial support.

2. Soheilipour F, Abed O, Behnam B, Abdolhosseini M, Alibeigi P, Pazouki A. A rare case of mixed gonadal dysgenesis with mosaicism 45, X/46, X, +mar. *Int J Surg Case Rep*. 2015;7C:35-8.



3. Moshiri M, Chapman T, Fechner PY, et al. Evaluation and management of disorders of sex development: multidisciplinary approach to a complex diagnosis. *Radiographics*. 2012;32(6):1599-618.
4. Jawaheer D, Juo SH, Le Caignec C, et al. Mapping a gene for 46,XY gonadal dysgenesis by linkage analysis. *Clin Genet*. 2003;63(6):530-5.
5. Ocal G. Current concepts in disorders of sexual development. *Jour Clin Res in Ped End*. 2011;3(3):105-114.
6. Das SK, Kumar A, Arvind N K, Phadke S. Surgical management of ambiguous genitalia in infants and children: An SGPGI experience. *Indian J Urol*. 2003;19(2):145-51.
7. Rosa RF, D'Ecclesiis WF, Dibbi RP, et al. 45,X/46,XY mosaicism: report on 14 patients from a Brazilian hospital. A retrospective study. *Sao Paulo Med J*. 2014;132(6):332-8.
8. Sadler T W, Langman J. Medical embryology-urogenital development. Kluwer Health/Lippincott Williams & Wilkins. 2012, 12th ed Capítulo 16, pp.243-259.
9. Kolon TF. Disorders of sexual development. *Curr Urol Rep*. 2008;9(2):172-7.
10. MacLaughlin DT, Donahoe PK. Sex determination and differentiation. *N Engl J Med*. 2004 22;350(4):367-78.
11. Nonomura K, Kakizaki H, Fukuzawa N, et al. Monozygotic twins with discordant sexual phenotypes due to different ratios of mosaicism of 47,X, idic(Y), idic(Y)/46,X, idic(Y)/45,X. *Endocr J*. 2002;49(4):497-501.
12. Soheilipour F, Abed O, Behnam B, Abdolhosseini M, Alibeigi P, Pazouki A. A rare case of mixed gonadal dysgenesis with mosaicism 45, X/46, X, +mar. *Int J Surg Case Rep*. 2015;7C:35-8.
13. Sinclair A. Eleven years of sexual discovery. *Genome Biol*. 2001;2(7):REPORTS4017.
14. Ahmed SF, Rodie M. Investigation and initial management of ambiguous genitalia. *Best Pract Res Clin Endocrinol Metab*. 2010;24(2):197-218.
15. Pinette MG, Wax JR, Blackstone J, Cartin A. Normal growth and development of fetal external genitalia demonstrated by sonography. *J Clin Ultrasound*. 2003;31(9):465-72.
16. Donohoe PK, Crawford JD. Ambiguous genitalia in the newborn. In: Welch KJ, Randolph JG, Ravitch MM et al (ed 4). Chicago. IL. Year book. 1986, p. 1374.
17. El-Sherbiny M. Disorders of sexual differentiation: I. Genetics and pathology. *Arab J Urol*. 2013;11(1):19-26.
18. Bhaskararao G, Himabindu Y, Nayak SR, Sriharibabu M. Laparoscopic

gonadectomy in a case of complete androgen insensitivity syndrome. Journal of Human Reproductive Sciences. 2014;7(3):221-23.

Access this article online

<http://pediatricurologycasereports.com>

Quick Response Code

