

ASSESSMENT OF RELATIONSHIP OF MANDIBULAR THIRD MOLAR ROOT TO INFERIOR ALVEOLAR NERVE CANAL USING PHOTOSTIMULABLE PHOSPHOR PLATE

D.Prabhu Shankar¹, P Manodh², V.G.Muruganand³, Aparna Murugan⁴

1.Associate professor, Dental college

2.Associate professor, Dental college

3.PG trainee, Dental college

4.PG trainee, Dental college

ABSTRACT:

The extraction of impacted mandibular third molars has long been associated with the dreaded and rarely, grave and irreversible complications. The oral and maxillofacial surgeons' dogma strongly links most complications with the proximity of inferior alveolar canal and the impacted teeth, the relationship of which is still a topic of debate among surgeons. In this randomized, prospective case study, involving 114 patients, we have attempted to evaluate the relationship between impacted mandibular third molar root and the inferior alveolar canal with intra oral periapical radiographs using photo stimulable phosphor plates and the incidence of inferior alveolar nerve injury following removal of impacted mandibular third molar. Preoperative assessment based on Rood and Shehab Criteria revealed 38.6% cases with an interruption of white line, 25.4% had darkening of root and 11.4% cases with diversion of the canal and 7% of cases revealed an inferior alveolar nerve deficit corresponding with the radiographic signs of "darkening of the third molar root" and "interruption of white line" by the third molar root. In comparison with the other imaging modalities Photo Stimulable Phosphor plate consumes less time with higher image resolution and magnification to gain better knowledge of the inferior alveolar canal and root relationship

Key words: Impaction - Mandibular molar- Photostimulable plate – radiographic signs - Inferior alveolar nerve

INTRODUCTION:

Impacted teeth can be defined as those teeth that are prevented from reaching its normal eruption by adjacent tooth, overlying bone, or soft tissue, or other impediments. The impacted mandibular third molar removal is the most common surgical procedure in oral and maxillofacial surgery and it is widely acknowledged to be useful due to its prevention of future problems. [3] The

major complications associated with the surgical removal are the neurosensory deficits post-operatively with an incidence of 0.26 to 8.4 % of inferior alveolar nerve. [2,16] The degree and the incidence of nerve injury is multi-factorial which includes surgeon's experience, age and sex of the patient and most importantly the anatomical relationship between the mandibular

canal and impacted mandibular third molar root. According to Rood and Shehab^[36] there are seven radiographical signs which suggest a close relationship between mandibular third molar and inferior alveolar canal, four of these signs are seen in the root of the tooth and three signs are seen on the inferior alveolar canal.

For precise identification of the proximity of mandibular canal and third molar root pre-operatively and to avoid complications and upgrade the surgical planning, various intra oral and extra oral radiographs like Orthopantomogram (OPG), intraoral periapical radiograph (IOPA), computed tomography (CT), cone beam computer tomography (CBCT), Photo Stimulable Phosphor plate (PSP) images are available, with Photo Stimulable Phosphor plates being latest technology incorporated by oral and maxillofacial surgeons worldwide.^[3,9]

The purpose of this study is to evaluate the relationship between mandibular third molars and the inferior alveolar canal with intra oral periapical radiographs using a photostimulable phosphor plate and the incidence of inferior alveolar nerve injury following removal of impacted mandibular third molar

MATERIALS AND METHODS:

114 patients, who reported to the department of Oral and Maxillofacial Surgery, Meenakshi Ammal Dental College, for the Transalveolar extraction of impacted mandibular third molars,

were selected for this study based on the inclusion criteria of presence of one or two Rood and Shehab Criteria. An Impacted mandibular third molar with periapical infection and cysts, no involvement of third molar root to inferior alveolar canal or radiographs with more than two radiographic signs were excluded. Radiographs of included patients were taken using Photostimulable Phosphor plate (fig I, II, III) IOPAR with paralleling cone technique and assessed for Rood and Shehab criteria.

Preoperative assessment: The details of the patients and third molar status were recorded according to a standardized protocol, including age and gender, impaction pattern, and the presence of 1 or more of the 7 radiographic signs listed below (fig IV).

- A) Darkening of the root
- B) Deflected root
- C) Narrowing of the root
- D) Dark and bifid root
- E) Interruption of the white line
- F) Diversion of the inferior alveolar canal
- G) Narrowing of the inferior alveolar canal.

A Standard operative technique for transalveolar extraction of mandibular third molar was performed.

Postoperative assessment: All the patients were examined post operatively

on the 7th day at the time of suture removal for the presence of any injury to the inferior alveolar nerve. The patients were questioned on paresthesia /anesthesia in the operated side of the lip and chin region. Neurosensory tests like static light touch (fig V), two point discrimination test (figVI) and pin prick test (fig VII) were performed for confirmation. Patients with neurosensory changes were followed up for a period of 6 months. If recovery was not complete after 6 months, the injury was considered permanent or delayed.

RESULTS:

114 patients (68 (59.6 %) male and 46 (40.35%) female) who reported to Meenakshi Ammal Dental College, Department of Oral and Maxillofacial Surgery with an age range of 18-35 years were included in the study (Fig- VIII). (TABLE – 1) Out of the 114 cases 44 (38.6%) cases presented with interruption of white line as radiographic marker. 29 (25.4%) had darkening of root, 13 (11.4%) cases presented with diversion of the canal, 7 (6.1%) cases presented with narrowing of the canal, 5 (4.4%) cases had Diversion of root, 4 (3.5%) cases presented with dark bifid apex, 3 (2.6%) cases had narrowing of root and 9 patients (7.9%) had 2 radiographic signs- darkening of the root and interruption of the white line (fig-IX).

The radiographic signs “darkening of the third molar root” and “interruption of white line by the third molar root” had an inferior alveolar nerve deficit in 4 (3.5%) and 3 (2.6%) cases respectively

after impaction surgery and showed statistically significant P value (TABLE 3). Out of the 4 cases with darkening of root, 1 case (0.87%) had an inferior alveolar defect for a period of more than 6 months and the rest 3 cases (2.63%) had a temporary nerve deficit and recovered within a period of 3 months. All the 3 cases seen with interruption of the white line with temporary nerve deficit recovered within a period of 3 months.

Out of the 9 radiographs with 2 radiographical signs 1 case (0.87%) had a neurosensory deficit, which was temporary (TABLE 2). Out of the 114 cases, 8 cases revealed an inferior alveolar nerve deficit, of which 7 cases showed grade 1 nerve injury (neuropraxia), while the 1 case showed grade III nerve injury (axonotmesis) (fig-X). Pinprick test with two point discrimination of the lower lip were negative in these patients with absence of response to light touch.

DISCUSSION:

Photo-Stimulable Phosphor (PSP) imaging is a digital technique for intra-oral radiography, which commercially came into use in the late 1980s. Although many studies have assessed extra-oral radiographic methods for assessment of mandibular third molars before removal, no study seems to have analyzed the use of digital intraoral radiography ^[15], which makes this study the first of its kind. In addition, the intraoral image is sharper than the panoramic image which is used by many

oral surgeons, and even though the focal trough is relatively wide in the molar regions of the panoramic image, the roots of the mandibular third molar may be blurred if beyond the layer of sharpness.^[16]

In our study the incidence of darkening of root was seen in 25.4 % cases, whereas interruption of white line was seen in 38.6 % cases with the total population of 114 patients, when compared to the incidence of 6.04 % & 4.61 % with 800 patients seen by Rood et al.

Catellon et al in their prospective study tried to determine the incidence of inferior alveolar nerve (IAN) damage after surgical removal of lower third molars, identify causes, and to construct a predictive model to assess the risk of inferior alveolar nerve injury and concluded that Patient age, ostectomy of the bone distal to the third molar, the radiologic relationship between the roots of the third molar and the mandibular canal, and deflection of the mandibular canal increased the risk of inferior alveolar nerve damage. Older patients were at a higher risk of suffering permanent injuries.

Carrio et al in a literature review of preoperative radiographic signs in orthopantomography (OPG) and computed tomography (CT) related to the risk of inferior alveolar nerve damage during the surgical extraction of lower third molar, found that radiographic signs in the OPG that indicate a close proximity between the

lower third molar and the inferior alveolar canal are considered a risk factor for nerve damage. These signs were depicted as darkening and the deflection of the root, and diversion and interruption in the white line of the canal. In the majority of reviewing studies, the routine use of computed tomography is not justified, and is only recommended when radiographic signs appear in the orthopantomography that demonstrate a direct anatomical relationship between the lower third molar and the canal. In the computed tomography, the absence of cortical bone in the canal implies a contact between the root of the lower third molar and the canal, and is related to the presence of some radiographic signs in the orthopantomography. Some studies demonstrate that despite the absence of cortical bone, the risk of lesion or exposure of the nerve during the extraction of lower third molar was low.

In our study, out of the 114 patients, 5 patients complained paresthesia of lower lip on the operated side and 3 patients had paresthesia on the skin of the mental region at the time of suture removal.

These nerve injuries were assessed using neurological tests, which can be divided into 2 basic categories mechanoreceptive and nociceptive testing based on the specific receptors stimulated through cutaneous contact. Mechanoreceptive testing can be further divided into Two-point discrimination test (TPD), static light touch test and brush directional

stroke test. Nociceptive testing is subdivided into pinprick test and thermal discrimination test.

In our study, we have used two-point discrimination test, static light touch test and pin prick test for patients with signs of inferior alveolar nerve deficit, according to the protocol given by A. R. Loescher and K. G. Smith. Patients who participated in the study were unable to discriminate between two points on the operated side initially till the third month postoperatively.

A classification of neurological injuries based on mechanism of injury has been described by Sunderland.³⁵ These include compression injury (neuropraxia), severe compression, stretch injury (axonotmesis), complete section of a nerve trunk (neurotmesis), and other injuries (perineural inflammation). The damaged nerve will react by going through stages of Wallerian degeneration and an attempt of axon regeneration, but the altered sensation is likely to remain permanent if there is no change after one to two years. In contrast, some authors claim that persistently symptomatic patients are classified as having a permanent nerve injury if there has been no change after 3 months¹. The Permanent altered sensation is more likely to occur where the nerve was severed (neurotmesis) or crushed as a result of sectioning with a rotary instrument or crushing of the nerve as a result of displacement of root tips into the inferior alveolar canal [35]. According to Robert et al ⁵ inferior

alveolar nerve injury was found in 4 out of 1000 patients, in our study, we had a nerve injury in 8 patients out of 114 patients, which was higher compared to Robert et al study. Out of the 8 patients, 7 patients had neuropraxia and 1 case had axontmesis, none of the patients had neurotmesis as per Sunderland classification. And according to Seddon classification, it was grade 1 injury in 7 patients and grade III injury in 1 patient.

The patients who had neurosensory deficit were managed medically with capsule Rerve plus once daily for 3 weeks and reviewed periodically for sensory changes, which was done in accordance with Gintaraset al ¹⁴ Of the 8 cases which showed a sensory nerve deficit, 7 cases showed a complete recovery at the end of 3 months, whereas 1 case had a prolonged prophesy for a period of more than 6 months.

CONCLUSION:

This is a pioneering study done using Photo-Stimulable Phosphor plate periapical radiograph to evaluate the relationship between impacted mandibular third molar root apex to the inferior alveolar canal. Significant statistical and clinical co- relation was observed between radiographic signs like darkening of root, interruption of white line and nerve injury. 7.01 % of inferior alveolar nerve injury present in our study are similar to the previous studies done using conventional intra oral periapical radiograph, orthopantomogram (OPG), cone beam

computer tomography (CBCT) and computer tomography (CT). In comparison with the other imaging modalities Photo-Stimulable Phosphor plates are cost effective and less time consuming. It revealed higher image

resolution and magnification which helped us to gain better knowledge of the inferior alveolar canal and root relation enabling us to carry out the surgical procedure with greater safety.

REFERENCES:

1. Nguyen, Edward, Dragan Grubor, and Arun Chandu. Risk Factors for Permanent Injury of Inferior Alveolar and Lingual Nerves During Third Molar Surgery. *Journal of Oral and Maxillofacial Surgery* 72, no. 12 (2014): 2394-2401.
2. Xu, Guang-zhou, Chi Yang, Xin-Dong Fan, Chuang-Qi Yu, Xie-Yi Cai, Yong Wang, and DongMei He. Anatomic relationship between impacted third mandibular molar and the mandibular canal as the risk factor of inferior alveolar nerve injury. *British Journal of Oral and Maxillofacial Surgery* 51, no. 8 (2013): e215-e219.
3. Hasegawa, T., S. RI, T. Shigeta, M. Akashi, Y. Imai, Y. Takei, Y. Shibuya, and T. Komori. Risk factors associated with inferior alveolar nerve injury after extraction of the mandibular third molar a comparative study of preoperative images by panoramic radiography and computed tomography. *International journal of oral and maxillofacial surgery* 42, no. 7 (2013): 843-851.
4. Selvi, Firat, Thomas B. Dodson, Anders Nattestad, Kevin Robertson, and Len Tolstunov. Factors that are associated with injury to the inferior alveolar nerve in high-risk patients after removal of third molars. *British Journal of Oral and Maxillofacial Surgery* 51, no. 8 (2013): 868-873.
5. Juan M. Cespedes-Sanchez, Raul Ayuso-montero, Antoni Mari-Roig. The importance of a good evaluation in order to prevent oral nerve injuries-A review. *Acta Odontologica Scandinavica* 72, no. 3 (2014): 161-167.
6. Meshram, Vikas Sukhadeo, Priyatama Vikas Meshram, and Pravin Lambade. Assessment of Nerve Injuries after Surgical Removal of Mandibular Third Molar: A Prospective Study. *Asian Journal of Neuroscience* 2013 (2013).
7. Kim, Jin-Woo, In-Ho Cha, Sun-Jong Kim, and Myung-Rae Kim. Which risk factors are associated with neurosensory deficits of inferior alveolar nerve after mandibular third molar extraction? *Journal of Oral and Maxillofacial Surgery* 70, no. 11 (2012): 2508-2514.
8. Soğur, E., B. G. Baksı, and A. Mert. The effect of delayed scanning of storage phosphor plates on occlusal caries detection. *Dentomaxillofacial Radiology* (2012) 41, 309-315.
9. Akcicek, G., S. Uysal, N. Avcu, and O. Kansu. Comparison of different imaging techniques for the evaluation of proximity between molars and the mandibular canal. *Clinical Dentistry and Research* 36, no. 1 (2012): 2-7.
10. Szalma, József, Edina Lempel, Sára Jeges, and Lajos Olasz. Darkening of third molar roots: panoramic radiographic associations with inferior alveolar nerve exposure. *Journal of Oral and Maxillofacial Surgery* 69, no. 6 (2011): 1544-1549.

11. Leung, Yiu Yan, and Lim Kwong Cheung. Correlation of radiographic signs, inferior dental nerve exposure, and deficit in third molar surgery. *Journal of Oral and Maxillofacial Surgery* 69, no. 7 (2011): 1873-1879.
12. Tolstunov, Len, Bahram Javid, Lance Keyes, and Anders Nattestad. Pericoronectomy: an alternative surgical technique for management of mandibular third molars in close proximity to the inferior alveolar nerve. *Journal of Oral and Maxillofacial Surgery* 69, no. 7 (2011): 1858-1866.
13. Cilasan, Ulkem, TulinYildirim, EsraGuzeldemir, and ZaferOzgurPektas. Coronectomy in patients with high risk of inferior alveolar nerve injury diagnosed by computed tomography. *Journal of Oral and Maxillofacial Surgery* 69, no. 6 (2011): 1557-1561.
14. Juodzbaly, Gintaras, Hom-Lay Wang, and GintautasSabaly. Injury of the inferior alveolar nerve during implant placement: a literature review. *Journal of oral & maxillofacial research* 2, no. 1 (2011).
15. Jerjes, Waseem, TahwinderUpile, Priya Shah, FaraiNhembe, DipaliGudka, Panagiotis Kafas, Eileen McCarthy et al. Risk factors associated with injury to the inferior alveolar and lingual nerves following third molar surgery revisited. *Oral Surgery, Oral Medicine, Oral Pathology, Oral Radiology, and Endodontology* 109, no. 3 (2010): 335-345.
16. Cheung, Lim K., Y. Y. Leung, L. K. Chow, M. C. M. Wong, E. K. K. Chan, and Y. H. Fok. Incidence of neurosensory deficits and recovery after lower third molar surgery: a prospective clinical study of 4338 cases. *International journal of oral and maxillofacial surgery* 39, no. 4 (2010): 320-326.
17. Poort, Lucas J., Johan W. van Neck, and Karel GH van der Wal. Sensory testing of inferior alveolar nerve injuries: a review of methods used in prospective studies. *Journal of Oral and Maxillofacial Surgery* 67, no. 2 (2009): 292-300.
18. Matzen, Louise Hauge, Jennifer Christensen, and Ann Wenzel. Patient discomfort and retakes in periapical examination of mandibular third molars using digital receptors and film. *Oral Surgery, Oral Medicine, Oral Pathology, Oral Radiology, and Endodontology* 107, no. 4 (2009): 566-572.
19. Ergün, S. P. Güneri, D. Ilgüy, M. Ilgüy, and H. Boyacıoğlu. How many times can we use a phosphor plate? A preliminary study. (2014).
20. Hillerup, Søren. Iatrogenic injury to the inferior alveolar nerve: etiology, signs and symptoms, and observations on recovery. *International journal of oral and maxillofacial surgery* 37, no. 8 (2008): 704-709.
21. Chiu, Hui-Lin, Shui-Hui Lin, Chia-Hui Chen, Wen-Chen Wang, Jin-Yi Chen, Yuk-Kwan Chen, and Li-Min Lin. Analysis of photostimulable phosphor plate image artifacts in an oral and maxillofacial radiology department. *Oral Surgery, Oral Medicine, Oral Pathology, Oral Radiology, and Endodontology* 106, no. 5 (2008): 749-756.
22. Almendros-Marqués, Nieves, Leonardo Berini-Aytés, and Cosme Gay-Escoda. Influence of lower third molar position on the incidence of preoperative complications. *Oral Surgery, Oral Medicine, Oral Pathology, Oral Radiology, and Endodontology* 102, no. 6 (2006): 725-732.
23. Hull, Donald J., Daniel A. Shugars, Raymond P. White Jr, and Ceib Phillips. Proximity of a lower third molar to the inferior alveolar canal as a predictor of delayed recovery. *Journal of oral and*

- maxillofacial surgery 64, no. 9 (2006): 1371-1376.
24. Koong, B., M. J. Pharoah, M. Bulsara, and M. Tennant. Methods of determining the relationship of the mandibular canal and third molars: a survey of Australian oral and maxillofacial surgeons. *Australian dental journal* 51, no. 1 (2006): 64-68.
 25. Tsuchida, Ryoko, Kazuyuki Araki, Atsushi Endo, Itsuo Funahashi, and Tomohiro Okano. Physical properties and ease of operation of a wireless intraoral x-ray sensor. *Oral Surgery, Oral Medicine, Oral Pathology, Oral Radiology, and Endodontology* 100, no. 5 (2005): 603-608.
 26. Mahasantipiya, Phattaranant May, N. W. Savage, P. A. J. Monsour, and R. J. Wilson. Narrowing of the inferior dental canal in relation to the lower third molars. (2014).
 27. Miloro, Michael, and Jeffrey DaBell. Radiographic proximity of the mandibular third molar to the inferior alveolar canal. *Oral Surgery, Oral Medicine, Oral Pathology, Oral Radiology, and Endodontology* 100, no. 5 (2005): 545-549.
 28. Tay, Andrew Ban Guan, and Wee Ser Go. Effect of exposed inferior alveolar neurovascular bundle during surgical removal of impacted lower third molars. *Journal of oral and maxillofacial surgery* 62, no. 5 (2004): 592-600.
 29. Pogrel, M. Anthony, J. S. Lee, and D. F. Muff. Coronectomy: a technique to protect the inferior alveolar nerve. *Journal of oral and maxillofacial surgery* 62, no. 12 (2004): 1447-1452.
 30. Susarla, Srinivas M., Bart F. Blaeser, and Daniel Magalnick. Third molar surgery and associated complications. *Oral and maxillofacial surgery clinics of North America* 15, no. 2 (2003): 177-186.
 31. Drage, Nicholas A., and Tara Renton. Inferior alveolar nerve injury related to mandibular third molar surgery: an unusual case presentation. *Oral Surgery, Oral Medicine, Oral Pathology, Oral Radiology, and Endodontology* 93, no. 3 (2002): 358-361.
 32. Valmaseda-Castellón, Eduard, Leonardo Berini-Aytés, and Cosme Gay-Escoda. Inferior alveolar nerve damage after lower third molar surgical extraction: a prospective study of 1117 surgical extractions. *Oral Surgery, Oral Medicine, Oral Pathology, Oral Radiology, and Endodontology* 92, no. 4 (2001): 377-383.
 33. Couture, Rex A., and Charles Hildebolt. Quantitative dental radiography with a new photostimulable phosphor system. *Oral Surgery, Oral Medicine, Oral Pathology, Oral Radiology, and Endodontology* 89, no. 4 (2000): 498-508.
 34. Huda, Walter, Lynn N. Rill, Douglas K. Benn, and James C. Pettigrew. Comparison of a photostimulable phosphor system with film for dental radiology. *Oral Surgery, Oral Medicine, Oral Pathology, Oral Radiology, and Endodontology* 83, no. 6 (1997): 725-731.
 35. Schultze-Mosgau, S., and R. H. Reich. Assessment of inferior alveolar and lingual nerve disturbances after dentoalveolar surgery, and of recovery of sensitivity. *International journal of oral and maxillofacial surgery* 22, no. 4 (1993): 214-217.
 36. Rood, J. P., and B. A. A. Nooraldeen Shehab. The radiological prediction of inferior alveolar nerve injury during third molar surgery. *British Journal of Oral and Maxillofacial Surgery* 28, no. 1 (1990): 20-25.
 37. Rood, J. P. Degrees of injury to the inferior alveolar nerve sustained during

- the removal of impacted mandibular third molars by the lingual split technique. *British Journal of Oral Surgery* 21, no. 2 (1983): 103-116.
38. Azaz, Badri, ArieShteyer, and Moshe Piamenta. Radiographic and clinical manifestations of the impacted mandibular third molar. *International journal of oral surgery* 5, no. 4 (1976): 153-160.
 39. Duinkerke, A. S. H., A. C. M. Van de Poel, F. P. G. M. Van der Linden, W. H. Doesburg, and W. A. J. G. Lemmens. Evaluation of a technique for standardized periapical radiographs. *Oral Surgery, Oral Medicine, Oral Pathology* 44, no. 4 (1977): 646-651.
 40. Q.A collectible sponsored by CRCPD's committee on quality Assurance in Diagnostic X-ray (H-7).
 41. Loescher, A. R., K. G. Smith, and P. P. Robinson. Nerve damage and third molar removal. *Dent Update* 30, no. 7 (2003): 375-82.
 42. Palma-Carrió C¹, García-Mira B, Larrazabal-Morón C, Peñarrocha-Diago M. Radiographic signs associated with inferior alveolar nerve damage following lower third molar extraction *Med Oral Patol Oral Cir Bucal*. 2010 Nov 1;15(6):e886-90

TABLES:

TABLE -1: Incidence of seven radiographical signs

RADIOGRAPHIC SIGNS	SIGN APPEARENCE	PERCENT OF POPULATION (TOTAL 114 CASES)
Darkening of root	29	25.4
Interruption of white line	44	38.6
Diversion of canal	13	11.4
Narrowing of canal	7	6.1
Diversion of root	5	4.4
Dark & bifid apex	4	3.5
Narrowing of root	3	2.6
Darkening & interruption of line	9	7.9

TABLE - 2: Incidence of paresthesia seen

RADIOGRAPHIC SIGN	PARESTHESIA SEEN	PERCENT OF POPULATION (TOTAL 114CASES)
Darkening of root	4	3.5
Interruption of white line	3	2.63
Diversion of canal	0	NA
Narrowing of canal	0	NA
Diversion of root	0	NA
Dark & bifid apex	0	NA
Narrowing of root	0	NA
Darkening of root & interruption of white line	1	0.87

TABLE - 3:

Darkening of root	Interruption of whiteline	Darkening&Interruption of white line
15.207 ^a	32.818 ^b	5.444 ^a
1	1	1
.000	.000	.020

FIGURES:



fig I : Photostimulable plate



fig II: Photostimulable cover




fig III: Photostimulable plate holder

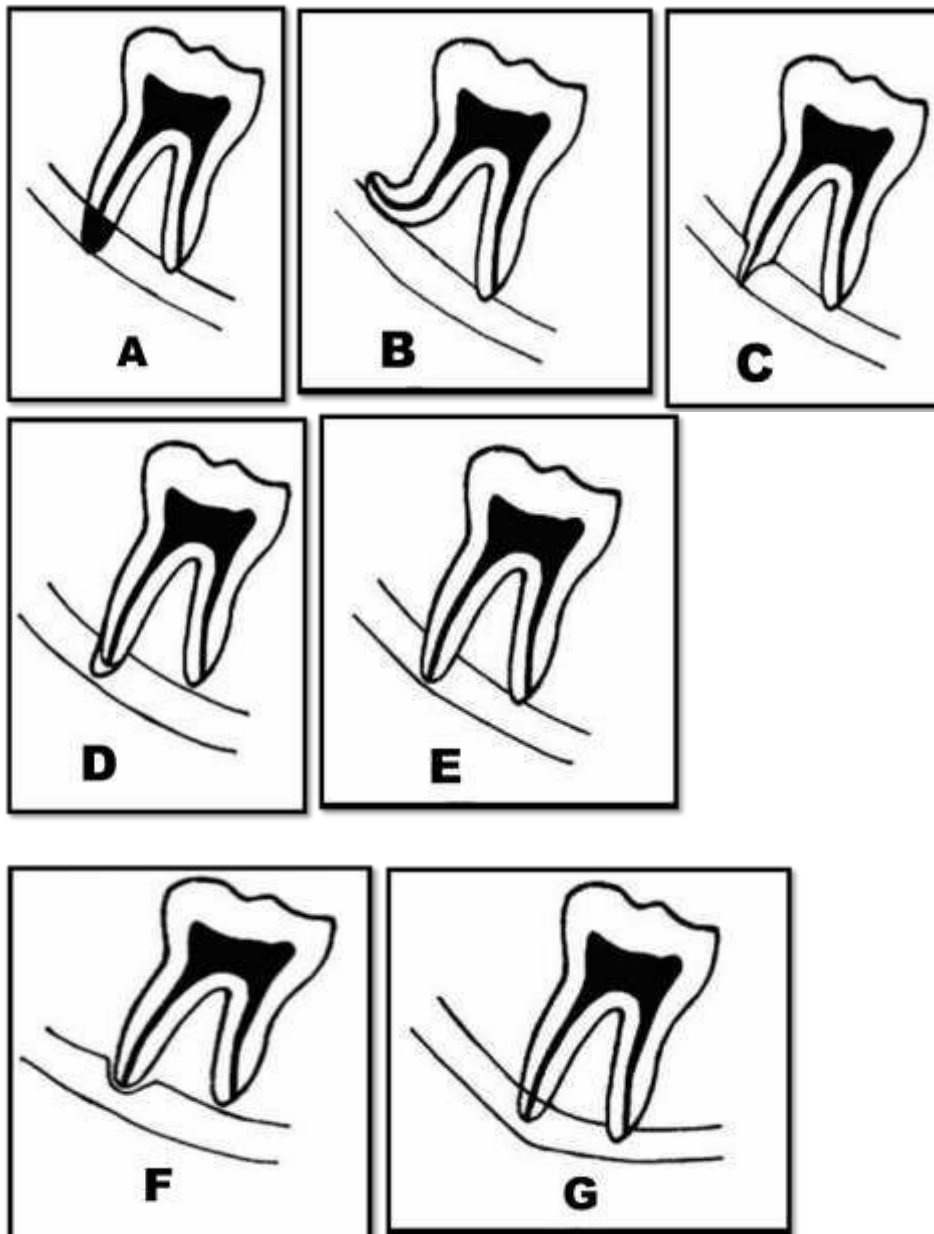


fig IV:

- A) Darkening of the root
- B) Deflected root
- C) Narrowing of the root
- D) Dark and Bifid root
- E) Interruption of the white line
- F) Diversion of the inferior alveolar canal
- G) Narrowing of the inferior alveolar canal

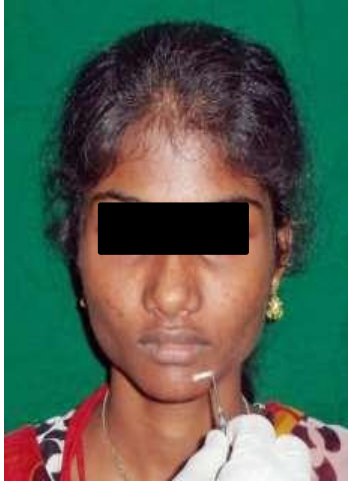

fig V: Light Touch Assessment (lt)

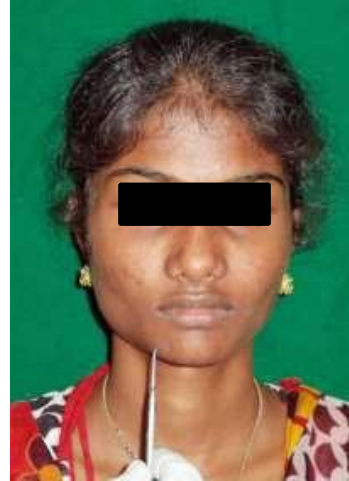

fig VII: Pinprick Test (pp)

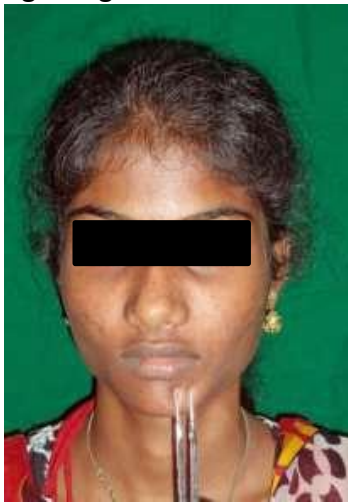

fig VI: Two - Point Discrimination test (tpd)

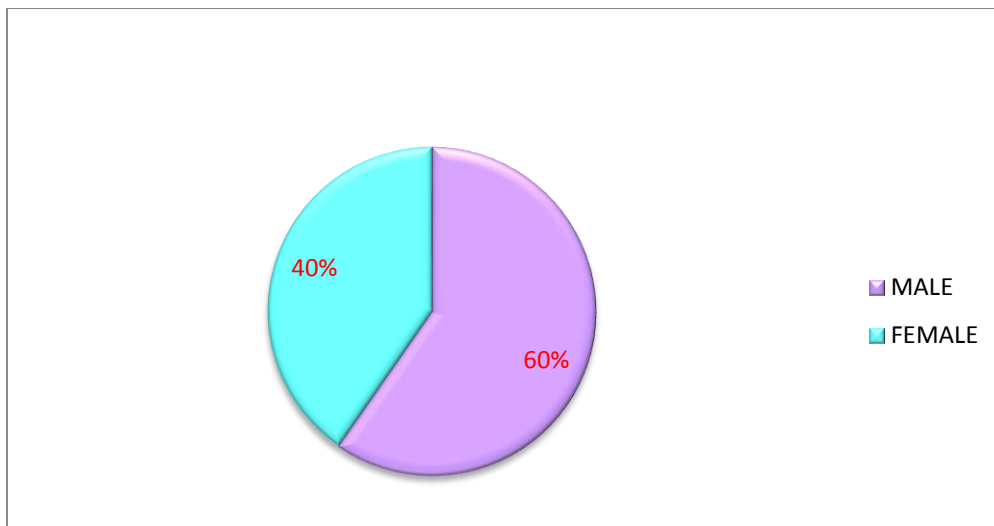


fig : VIII

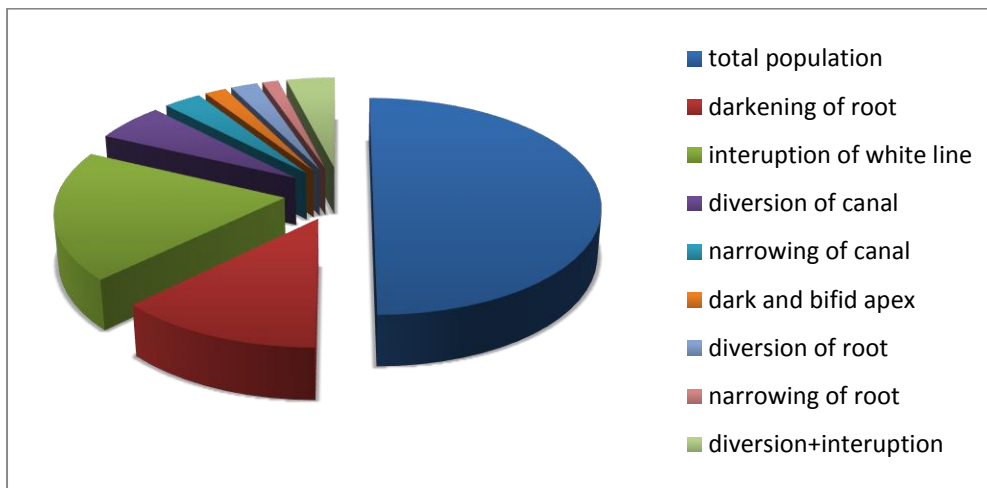


Fig IX: Radiographic signs present in total population

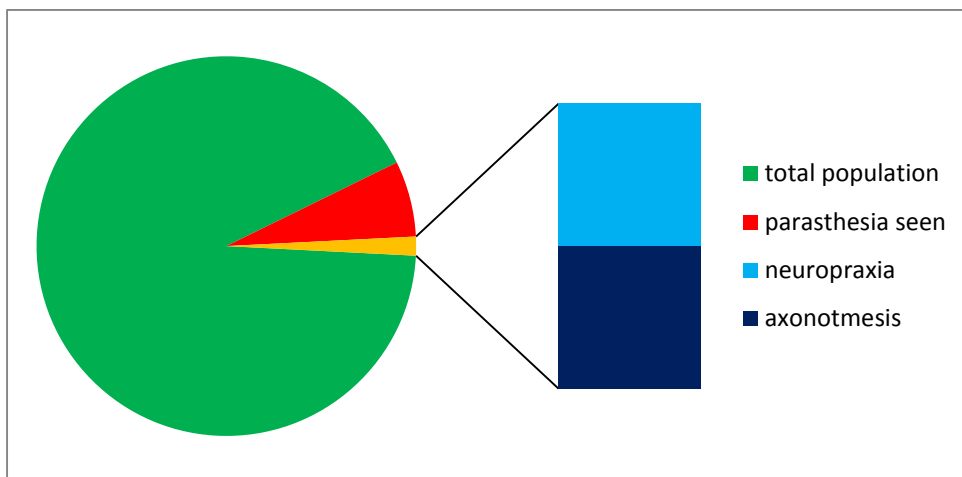


Fig X: Neurosensory Deficit