

# Research & Reviews: Journal of Dental Sciences

## Orthodontic Treatment for Cleft Palate Associated Open-Bite Malocclusion Using Compensatory Extraction Protocol: A Case Report

Ezgi Atik<sup>1\*</sup> and İlken Kocadereli<sup>2</sup>

<sup>1</sup>Research Assistant, Department of Orthodontics, Faculty of Dentistry, Hacettepe University, Ankara, Turkey

<sup>2</sup>Professor, Department of Orthodontics, Faculty of Dentistry, Hacettepe University, Ankara, Turkey

### Case Report

Received date: 28/11/2015

Accepted date: 04/12/2015

Published date: 12/12/2015

#### \*For Correspondence

Dr.Ezgi Atik, Research assistant,  
Department of Orthodontics, Faculty of  
Dentistry, Hacettepe University, Sıhhiye,  
06100, Ankara, Tel: +90 312 3052290,  
Tele Fax: +90 312 3091138, Turkey

E-mail: ezgibaytorun@hotmail.com

Keywords: Cleft palate, open-bite,  
extraction

#### ABSTRACT

A female patient aged 18 years and 4 months referred to dental our clinic with a chief complaint of the unaesthetic appearance of the maxillary anterior teeth and open bite. The maxillary arch was constricted resulting from both the initial cleft and the previous surgical scarring which contributed to bilateral posterior cross bite. The first stage of the orthodontic treatment began with slow maxillary quad-helix expansion appliance. After 4 months of expansion period, asymmetric extractions including upper right and lower left first molar teeth were performed and full fixed 0.022-in Roth prescribed appliances were placed with anchorage appliances to begin aligning and closing the extraction spaces. Active orthodontic treatment was 23 months. At the end of the comprehensive orthodontic treatment of an adult patient with isolated cleft palate, normal function and better esthetics were achieved and the patient was satisfied with the results.

### INTRODUCTION

Cleft lip and/or palate are the most frequent craniofacial anomalies seen in human beings with an incidence of 1:800 live births. Isolated cleft palate occurs in 1:2000 live births. Cleft palate is caused by break in fusion between the palatine shelves forming during 8th week of the embryonic period. The etiology of the clefts are both genetic and environmental factors <sup>[1]</sup>.

Dental abnormalities, malformation, abnormal eruption pattern, deficient midface development, severe maxillary transverse deficiency and alveolar cleft can be seen in patients with CLP <sup>[2,3]</sup>. In order to improve facial esthetics and function, treatment of the CLP patients includes respectively nasoalveolar molding, labial repair, palatoplasty, orthodontic expansion, primary or secondary alveolar bone graft, surgery, and comprehensive orthodontic treatment <sup>[4,5]</sup>.

The purpose of this case report is to present the comprehensive orthodontic treatment approach for an adult female patient who had isolated cleft palate, anterior open-bite and severe maxillary constriction.

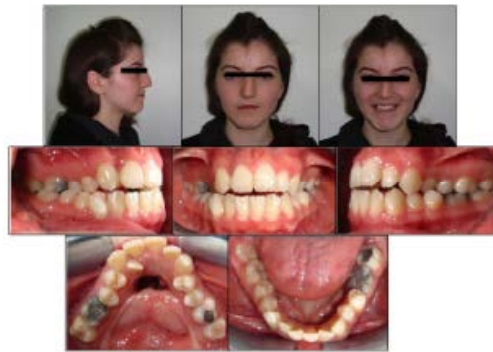### CASE REPORT

A young female (aged 18 years 4 months) came to the clinic for the treatment of severe maxillary crowding. Her chief complaint was the unaesthetic appearance of the maxillary anterior teeth and anterior open-bite. She had isolated cleft palate with no other local or systemic illness. She underwent palatoplasty operations when she was at 2.5,4,6 and 16 years old.

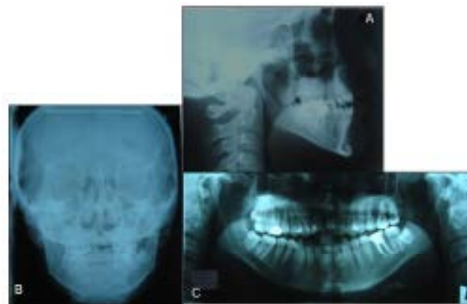
She showed asymmetry in the frontal view with mandibular deviation to the left side. The lateral view of the photograph showed a straight facial profile with a retruded upper lip (**Figure 1**). The maxillary and mandibular midlines were deviated to the right side 1 mm and 3 mm respectively.

The maxillary arch was collapsed as a result of both the initial cleft and the previous surgical scarring in the palate which contributed to bilateral posterior cross-bite. Upper left and lower right first molars were extracted when she was 13 years old due to extensive caries from poor oral hygiene. The maxillary right lateral incisor was palatally ectopic and severely malpositioned.

In addition, She had severe crowding in the maxillary arch (-7,5 mm) and moderate crowding in the mandibular arch (-2,5 mm). Overbite and overjet were -2 mm and 0 mm, respectively. The canine relationships were Class II on the right and Class I on the left sides (**Figure 1**). The panoramic radiograph (**Figure 2**) showed missing upper left and lower right first molar teeth. Cephalometric analysis indicated a skeletal Class III relationship (ANB,  $-2^\circ$ ) with a vertical growth pattern (GoGnSN,  $45^\circ$ ). The maxillary incisors were slightly proclined (Mx1-SN,  $106^\circ$ , Mx1-FH,  $118^\circ$ ), and the mandibular incisors were retroclined (IMPA,  $82^\circ$ ) (**Table 1**).



**Figure 1.** Pretreatment facial and intraoral photographs.



**Figure 2.** Pretreatment radiographs: A, lateral cephalogram; B, posteroanterior cephalogram; C, panoramic radiograph.

**Table 1.** Cephalometric variables at pretreatment (T0) and post-treatment (T1).

Measurement	Pretreatment (T0)	Post-treatment (T1)
SNA ( $^\circ$ )	$73^\circ$	$72.9^\circ$
SNB ( $^\circ$ )	$75^\circ$	$73.2^\circ$
ANB ( $^\circ$ )	$-2^\circ$	$-0.3^\circ$
MP-FH ( $^\circ$ )	$36^\circ$	$33.8^\circ$
GoGnSN ( $^\circ$ )	$45^\circ$	$41.7^\circ$
Mx1-SN ( $^\circ$ )	$106^\circ$	$101.6^\circ$
Mx1-FH ( $^\circ$ )	$118^\circ$	$112.2^\circ$
Mx1-NA ( $^\circ$ )	$33^\circ$	$27^\circ$
IMPA ( $^\circ$ )	$82^\circ$	$81^\circ$
FMIA ( $^\circ$ )	$62^\circ$	$64.3^\circ$
Mnd1-NB ( $^\circ$ )	$19^\circ$	$20^\circ$
Overjet (mm)	-2 mm	2.4 mm
Overbite (mm)	0 mm	2.3 mm
Low.Lip-E (mm)	-5 mm	-3.6 mm
Upp.Lip-E (mm)	-8 mm	-4.5 mm

The treatment objectives were to resolve transvers maxillary deficiency, align the dental arches, close the open-bite, obtain normal over jet and overbite, establish a Class I canine relationship, correct the dental midline shifts. Also it was important to observe the maxilla carefully during treatment not to open and damage the palatal cleft.

Orthognathic surgery has been suggested to the patient. The surgical objective was to advance the maxilla to improve her facial profile. The patient declined the surgical option and decided to pursue with orthodontic treatment alone.

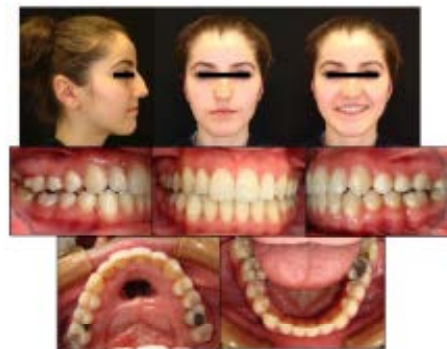The treatment stages were explained to the patient in several stages, as follows: (1) Expansion of the maxillary dental arch with a quad-helix application. (2) Extractions including upper right and lower left first molar teeth. (3) Moving the palatally positioned right lateral incisor into the dental arch. (4) Correction of the upper and lower dental midline deviation. (5) The mesialization of the lower left second molar by the application of miniscrew. (6) Essix and fixed retainers for retention.

The first stage of the orthodontic treatment began with maxillary expansion. Quad-helix appliance was cemented to the right first and left second maxillary molars and activated for every month until the desired maxillary expansion was gained. After 4 months of expansion period, upper right and lower left first molar teeth were extracted. As an anchorage transpalatal arch and lingual arches were used. 0.022-inch Roth prescribed brackets (Forestadent, Pforzheim, Germany) were applied in the both maxillary and mandibular dental arches for aligning. In the maxillary arch, right lateral incisor was by passed during alignment stage until there was enough space for replacement. To provide adequate area for the lateral incisor, maxillary right first and second premolar and canine teeth were retracted with an elastic chain toward second molar. In addition, a coil spring was used between the maxillary right canine and central incisor both to widen the space and correct the upper midline toward to left side. When adequate space was gained, piggy-back arch mechanic was used to move the palatally positioned right lateral incisor into the arch.

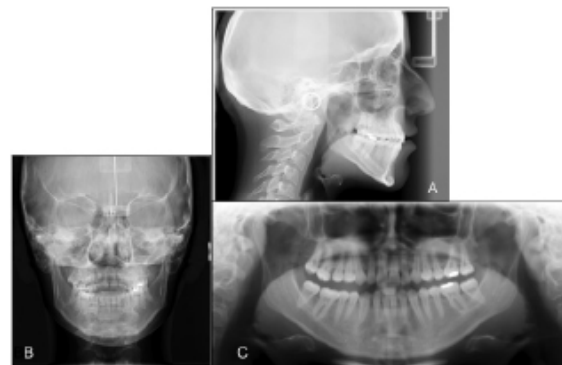
In the lower arch, left first molar's extraction space was mainly used for midline correction. After lower dental midline was corrected, lingual arch was removed and orthodontic miniscrew (6 mm long, 1.5 mm diameter; Orlus, Seoul, Korea) was placed into the buccal side between mandibular left first and second premolar under local anesthesia. Elastic chain was connected from the miniscrew to the hook of the molar band attached to the mandibular left second molar for the mesialization of the second molar. The miniscrew was removed when the mesial movement of the second molar was completed. During the finishing stage, Class II diagonal and box elastics were used to correct the dental midline and Class II relationship on the right side.

Duration of active orthodontic treatment was 23 months. After treatment, the patient was referred to the Department of Plastic Reconstructive and Esthetic Surgery for the palatoplasty surgery. Maxillary and mandibular essix retainers were delivered with fixed retainers and the patient was instructed to wear them full time for 1 year and then nights thereafter.

Treatment objectives were achieved at the end of the treatment (**Figures 3 and 4**). Class I canine relationships were established and dental midlines were coincident with both facial midline and each other. Ideal overbite and over jet were achieved and the curve of spee was leveled.



**Figure 3.** Post-treatment facial and intraoral photographs.



**Figure 4.** Post-treatment radiographs: A, lateral cephalogram; B, posteroanterior cephalogram; C, panoramic radiograph.

The post-treatment lateral cephalometric analysis showed mild skeletal changes with backward movement of the mandible (ANB,  $-0.3^\circ$ ) and a decrease in mandibular plane angle (SN-MP,  $41.7^\circ$ ). Maxillary incisors were retroclined. (Mx1-SN,  $101.6^\circ$ ; Mx1-FH,  $112.2^\circ$ ). The mandibular incisors were slightly proclined (IMPA,  $81^\circ$ ) (**Table 1**). The post-treatment panoramic radiograph showed acceptable root parallelism with no signs of bone or root resorption (**Figure 4**).

## DISCUSSION

Patients with CLP have several features such as deficient midface resulting in Class III malocclusion, maxillary transverse deficiency, alveolar cleft and dental abnormalities [6,7]. The combination of skeletal and dental malocclusion challenges the treatment of CLP and requires interdisciplinary approaches in order to obtain ideal esthetic and functional outcomes [8]. Interdisciplinary treatment plan frequently includes primary surgeries during infancy, orthodontic expansion, alveolar bone graft, comprehensive orthodontic treatment and jaw surgery [9,10].

As a treatment alternative, orthognathic surgery including maxillary advancement was recommended to our patient. So that, this operation would improve the facial profile. However she definitely declined the surgery. If the skeletal discrepancy is mild and esthetic concerns are minimal, dental compensation by orthodontic treatment alone might be recommended for the patients<sup>[14]</sup>. Therefore, we decided on orthodontic camouflage treatment alone.

Palatoplasty has a detrimental effect on the maxillary growth<sup>[12,13]</sup>. The patient had four palatoplasty operations between 2 and 16 years old age and therefore had extremely narrow maxillary dental arch and bilateral posterior cross-bite. The first treatment option was to expand the maxillary arch for both reconstruction of the occlusion and for more efficient mastication. Several orthodontic appliances are available to expand the maxilla, including slow or rapid maxillary expansion, surgically assisted orthodontic expansion, and expansion during surgery<sup>[14,15]</sup>. To our patient, it was difficult to apply rapid palatal expansion appliance by the reason of damage risk to the palatal tissue. Therefore, slow expansion was chosen for the first stage of the treatment. A quad-helix appliance was used to expand the maxillary arch for 4 months.

The treatment of open-bite malocclusion is generally considered challenge due to the multifactorial etiologic factors<sup>[16]</sup>. Different treatment modalities are available for open-bite correction. In our patient upper left and lower right first molars were extracted when she was 13 years old due to extensive caries from poor oral hygiene. Since this patient showed severe maxillary crowding, vertical growth pattern and open-bite malocclusion, the treatment of choice was to perform compensatory extractions including upper right and lower left first molar teeth. In this way, it was possible to close the bite, coordinate dental midlines and correct the dental crowding.

In our patient some additional treatment adjuncts were used to achieve the desired result. In the lower arch, miniscrew application provided excellent skeletal anchorage. Lower left first molar extraction space was closed with bodily movement of the second molar as the post-treatment panoramic radiograph showed root parallelism of the second molar. Also, the lower mandibular incisors were slightly proclined by the help of miniscrew anchorage at the end of the treatment.

This case report describes the comprehensive treatment of an adult with cleft palate and open-bite malocclusion. She was successfully treated by orthodontic camouflage treatment.

## REFERENCES

1. Tai K, Park JH, Okadakage S, Mori S, Sato Y. Orthodontic treatment for a patient with a unilateral cleft lip and palate and congenitally missing maxillary lateral incisors and left second premolar. *Am J Orthod Dentofacial Orthop.* 2012;141:363-373.
2. Fishman LS. Factors related to tooth number, eruption time, and tooth position in cleft palate individuals. *ASDC J Dent Child.* 1970;37: 303-306.
3. Lai MC, King NM, Wong HM. Abnormalities of maxillary anterior teeth in Chinese children with cleft lip and palate. *Cleft Palate Craniofac J.* 2009;46: 58-64.
4. Bergland O, Semb G, Abyholm F, Borchgrevink H, Eskeland G. Secondary bone grafting and orthodontic treatment in patients with bilateral complete clefts of the lip and palate. *Ann Plast Surg.* 1986;17: 460-474.
5. Geraedts CT, Borstlap WA, Groenewoud JM, Borstlap-Engels VM, Stoelinga PJ. Long-term evaluation of bilateral cleft lip and palate patients after early secondary closure and premaxilla repositioning. *Int J Oral Maxillofac Surg.* 2007;36:788-796.
6. Qureshi WA, Beiraghi S, Leon-Salazar V (2012) Dental anomalies associated with unilateral and bilateral cleft lip and palate. *J Dent Child (Chic).* 2012;79: 69-73.
7. Ranta R, Tulensalo T. Symmetry and combinations of hypodontia in non-cleft and cleft palate children. *Scand J Dent Res.* 1988;96: 1-8.
8. Germec-Cakan D, Canter HI, Cakan U, Demir B. Interdisciplinary treatment of a patient with bilateral cleft lip and palate and congenitally missing and transposed teeth. *Am J Orthod Dentofacial Orthop.* 2014;145:381-392.
9. David DJ, Smith I, Nugent M, Richards C, Anderson PJ. From birth to maturity: a group of patients who have completed their protocol management. Part III. Bilateral cleft lip-cleft palate. *Plast Reconstr Surg.* 2011;128:475-484.
10. Suzuki EY, Watanabe M, Buranastidporn B, Baba Y, Ohyama K, Ishii M. Simultaneous maxillary distraction osteogenesis using a twin-track distraction device combined with alveolar bone grafting in cleft patients: preliminary report of a technique. *Angle Orthod.* 2006;76:164-172.
11. Tai K PJ, Okadakage S, Mori S, Sato Y. Orthodontic treatment for a patient with a unilateral cleft lip and palate and congenitally missing maxillary lateral incisors and left second premolar. *Am J Orthod Dentofacial Orthop.* 2012;141:363-373.
12. Ye B, Ruan C, Hu J, Yang Y, Thomas J, et al. A comparative study on the measurements of palatal shelf area and gradient for adult patients with unoperated cleft palate. *Cleft Palate Craniofac J.* 2012;49: 561-565.
13. Warren JJ, Bishara SE. Comparison of dental arch measurements in the primary dentition between contemporary and historic samples. *Am J Orthod Dentofacial Orthop.* 2001;119:211-215.

14. Da Silva Filho OG, Boiani E, de Oliveira Cavassan A, Santamaria M. Rapid maxillary expansion after secondary alveolar bone grafting in patients with alveolar cleft. *Cleft Palate Craniofac J.* 2009;46:331-338.
15. Okada W, Fukui T, Saito T, Ohkubo C, Hamada Y, et al. Interdisciplinary treatment of an adult with complete bilateral cleft lip and palate. *Am J Orthod Dentofacial Orthop.* 2012;141: S149-158.
16. Kassir C, Assi SB. Orthodontic management of an originally surgically planned treatment of an open bite: a case report. *Orthodontics.*