

# Importance and Calculation of Pharyngeal Spaces and Hyoid Position Before and After Orthognathic Surgery

Dhruv Yadav<sup>1</sup> Divyaroop Rai<sup>2\*</sup> Vikas Gill<sup>3</sup> Akрати Dosi<sup>4</sup> Abhilasha Choudhary<sup>5</sup>

<sup>1</sup>Post Graduate Student, Department of Orthodontics, Rajasthan Dental College, Jaipur, Rajasthan, India.

<sup>2</sup>Assistant Professor, Department of Orthodontics, Rajasthan Dental College, Jaipur, Rajasthan, India.

<sup>3</sup>Reader, Department of Orthodontics, Rajasthan Dental College, Jaipur, Rajasthan, India.

<sup>4</sup>Post Graduate Student, MHA, University of Houston, Texas, United States.

<sup>5</sup>Post Graduate Student, Department of Orthodontics, Rajasthan Dental College, Jaipur, Rajasthan, India.

## ABSTRACT

**Aim:** The purpose of the study was to examine the changes in dimension of pharyngeal airway spaces (PAS) and hyoid bone position after surgery in class II and class III skeletal malocclusion.

**Methods:** This study included 50 patients of class II and class III skeletal and dental malocclusion who had undergone orthognathic surgery. The pre and post treatment lateral cephalograms were taken to calculate upper and lower air way spaces and position of hyoid bone was also measured before and after the surgery.

**Results:** Changes in upper and lower airway spaces and alteration in the location of hyoid bone was seen in Class II cases only.

**Conclusion:** Maintaining of lower air way spaces in surgical class III cases of mandibular set back and position of hyoid bone is very important.

**Keywords:** Hyoid bone, Orthognathic surgery, Pharynx.

## INTRODUCTION

The nasopharynx is a musculo-membranous tube serving as a portal between the nasal chambers anteriorly and the oral pharynx inferiorly. Its primary biologic function is to provide a passage for air from the nasal chamber to the oral pharynx, laryngeal pharynx and ultimately to the lungs.

The nasopharynx also provides space on its posterior and superior wall for lymphoid tissue in the form of the nasopharyngeal tonsils as part of Waldeyer's tonsillar ring. This tissue, often seen to be hypertrophied during childhood, is also denoted as "adenoid".



The enlargement of the adenoids may lead to partial or total blockage of the nasopharyngeal passage making nasal respiration either inefficient or impossible. Thus the concurrent function of the nasopharynx as the site for the passage of nasal airway flow, may be in conflict<sup>1</sup>.

The potential disharmony between the adenoid mass and the nasopharyngeal airway may be due to the difference in growth patterns of the bony nasopharynx and the attached tonsillary tissue<sup>2</sup>. Obstruction of the nasopharynx predisposes a child to chronic mouth breathing, pathognomic for "respiratory obstruction syndrome" described by Ricketts<sup>3</sup>. The influence of the soft tissues on the craniofacial growth had been studied earlier, and is highly relevant to the orthodontic diagnosis and the treatment plan. In 1872, Tomes<sup>4</sup> hypothesized that maxillary constriction could be caused by lymphatic

Received: Oct. 10, 2014; Accepted: Feb. 2, 2015

\*Correspondence: Dr. Divyaroop Rai

Department of Orthodontics, Rajasthan Dental College, Jaipur, Rajasthan.

E-mail: divyaroop@hotmail.com

tissue hypertrophy of the pharynx that leads to the absence of lip seal and a lower tongue position to maintain the permeability of the airway.

Some authors believed that evaluation of the soft tissues such as tonsils, adenoids, nasal polyps, neuromuscular functional jaw patterns and facial contours, should be an integral part of treatment planning to aid in the stability and aesthetics of the orthodontic or orthopedic results.<sup>5-7</sup>

Behlfelt<sup>8</sup>observed that children who suffered from adenoidal hypertrophy had greater extensions in head posture and lower positions of the hyoid bone associated with lower tongue posture. He also speculated that the inferior hyoid/tongue posture was the response to a physiologic reflex to increased oropharyngeal capacity. The nasopharyngeal skeleton increases its capacity mainly by vertical growth, which is statistically related to a patient’s age but not to body size or weight<sup>9-11</sup>. Relative growth and size of the soft tissues surrounding the skeletal structures mainly determine pharyngeal space size. From early adulthood to later years (approximately 20-50 years of age), the nasopharyngeal skeleton hardly changes. Posterior nasopharyngeal depth increases as the posterior pharyngeal wall becomes thinner. This means that pharyngeal morphology not only changes during childhood and adolescence, but also varies during adulthood<sup>12</sup>. Adenoid hypertrophy is an important cause of nasal obstruction<sup>13</sup> and is commonly related to many symptoms, including mouth breathing<sup>14,15</sup>. As a consequence, oral respiration leads to significant neuromuscular and soft-tissue rearrangements<sup>16,17</sup>, which might result in distorted craniofacial growth and orthodontic alterations<sup>18-21</sup>.

According to the functional-matrix hypothesis proposed by Moss<sup>22</sup> soft-tissue units guide the hard tissues to an extent. The studies of Linder-Aronson<sup>18</sup>, Woodside and Linder-Aronson<sup>23</sup>, Solow and Greve<sup>24</sup>are good examples for this hypothesis, where average craniofacial morphology of the “adenoid children” approached that of the control group subjects after adenoidectomy.

Mandibular advancement and setback BSSO surgery improves the occlusion, function and

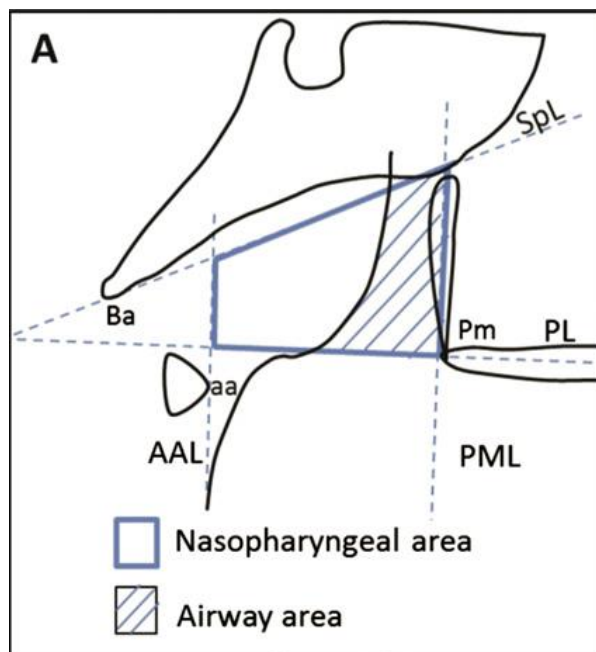
aesthetics by changing the position of the mandible in both Class II and Class III malocclusion.

**MATERIALS AND METHOD**

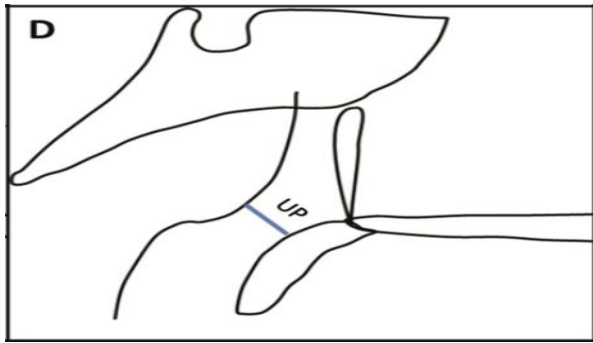
50 patients having class II and III dental and skeletal characters (25 each) treated by orthognathic surgery, were analyzed using pre-treatment and post-treatment cephalograms taken in natural head position, for calculating upper - lower air way and hyoid bone position.

All the cases were selected on the basis of vertical growth pattern, class II and class III were based on the skeletal base where class II skeletal cases were surgically treated with BSSO advancement and class III skeletal cases were surgically treated with BSSO setback. Growth pattern was based on Go-Gn to SN and GO-Me to SN and skeletal pattern was based on Wits appraisal (AO-BO) and ANB angle.

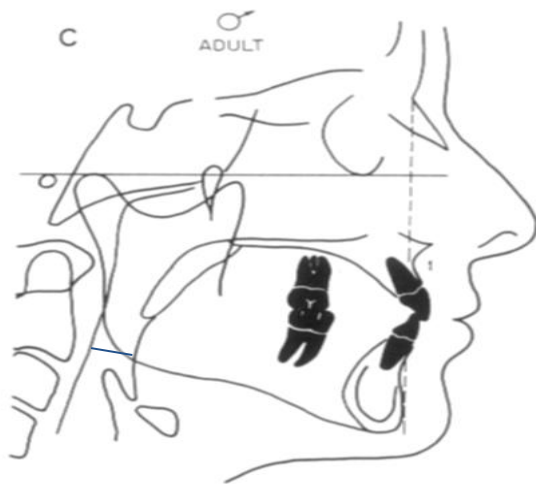
Upper Air way spaces were calculated by Mc Namara<sup>25</sup> and Handelman and Osborne<sup>26</sup>. Lower air way space was measured from posterior border of tongue intersecting with lower border of mandible.



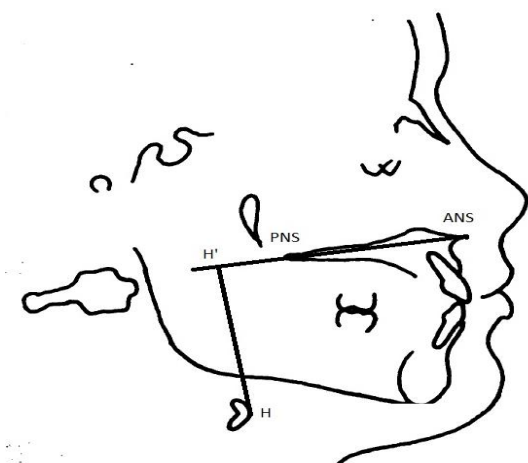
**Fig 1:** Handelman and Osborne Handelman and Osborne Airway area (Aa) (%): (airway area/nasopharyngeal area) x 100 (Fig 1).



**Fig 2:**Upper pharynx (UP) (mm): nearest distance from a point on the posterior outline of the soft palate and a point on the adenoid outline, Lower air way spaces was calculated by Mc Namara<sup>43</sup>.



**Fig 3:** Lower pharynx



**Fig 4:** Hyoid Bone Position

Position of the Hyoid bone was noted in the antero-posterior direction and vertical position by the help of H point(hyoidale) on the hyoid bone

measured by drawing a perpendicular line to the cephalometric H point on hyoid bone from palatal plane (ANS-PNS), H point is superimposed on palatal plane and readings were taken. If the point was before PNS it was measured in negative value.

**RESULT**

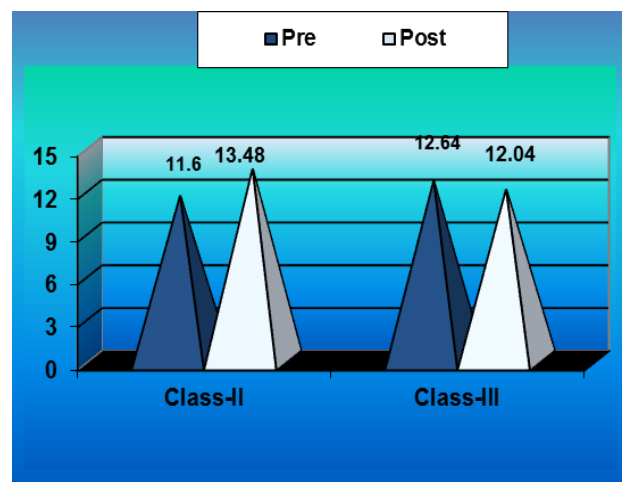
**Table 1**

The mean of lower airway space of class II pre-treatment was  $11.60 \pm 3\text{mm}$  and post treatment was  $13.48 \pm 2.19\text{mm}$ . It was observed that lower airway space post treatment was increased. The mean change in airway space area was significant (Sig.).

The mean of lower airway space of class III pre-treatment was  $12.64 \pm 4.50\text{ mm}$  and post treatment was  $12.04 \pm 3.22\text{ mm}$ . The mean change in airway space from pre to post treatment was  $0.60 \pm 2.99\text{ mm}$ . The mean change in airway space was not significant (NS).

**Table 1:** Mean  $\pm$  SD of lower way space at pre & post of class -II & class-III subjects (mm) (McNamara Analysis).

Group	Mean $\pm$ SD		Mean change $\pm$ SD	P-value	Sig
	Pre	Post			
Class II	$11.60 \pm 3.00$	$13.48 \pm 2.19$	$-1.88 \pm 3.40$	$<.01$	Sig
Class III	$12.64 \pm 4.50$	$12.04 \pm 3.22$	$0.60 \pm 2.99$	$>.05$	NS



**Graph 1:** lower way space at pre & post of class -II & class-III subjects (mm)

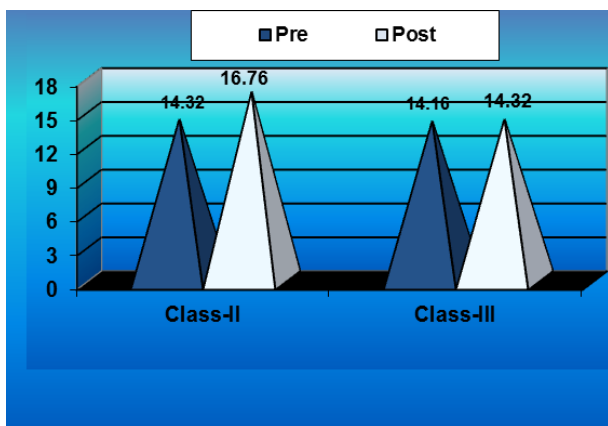
**Table II**

The mean of upper airway space of class II pre-treatment was  $14.32 \pm 4.21$  mm and post treatment was  $16.76 \pm 3.67$  mm. It was observed that upper airway space post treatment was increased. The mean change in airway space from pre to post treatment was  $2.44 \pm 1.88$ . This mean change in airway in airway space area was highly significant (HS).

The mean of upper airway space of class III pre-treatment was  $14.16 \pm 3.11$  mm post treatment was  $14.32 \pm 3.46$  mm. It was observed that upper airway space post treatment did not have much difference. The mean change in airway space was not significant (NS).

**Table 2:** Mean  $\pm$  SD of upper way space pre & post of class -II & class-III subjects (mm) (McNamara Analysis).

Group	Mean $\pm$ SD		Mean change $\pm$ SD	P-value	Sing
	Pre	Post			
Class II	$14.32 \pm 4.21$	$16.76 \pm 3.67$	$2.44 \pm 1.88$	$<.001$	HS
Class III	$14.16 \pm 3.11$	$14.32 \pm 3.46$	$0.16 \pm 2.78$	$>.05$	NS



**Graph 2:** Upper way space pre & post of class -II & class-III subjects (mm)

**Table III**

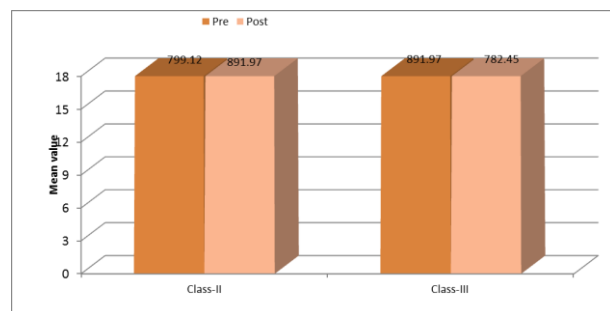
The mean of nasopharynx area of class II pre-treatment was  $799.12 \pm 205.35$  mm<sup>2</sup> post treatment was  $891.97 \pm 227.79$  mm<sup>2</sup>. It was observed that nasopharynx area post treatment was increased. The mean change in area from pre and

post treatment was  $92.85 \pm 157.85$ . The mean change in nasopharynx area was significant.

The mean of nasopharynx area of class III pre-treatment was  $827.78 \pm 114.08$  mm<sup>2</sup> and post treatment was  $782.78 \pm 112.23$  mm<sup>2</sup>. It was observed that nasopharynx area post treatment had decreased. The mean change in area from pre and post treatment was  $6.31 \pm 76.23$ . The mean change in nasopharynx area was not significant.

**Table 3:** Mean  $\pm$  SD of Nasopharynx at pre & post of class -II & class-III subjects (mm<sup>2</sup>) (Handelman and Osborne)

Group	Mean $\pm$ Sd		Mean change $\pm$ Sd	P-value	Sing
	Pre	Post			
Class II	$799.12 \pm 205.35$	$891.97 \pm 227.79$	$92.85 \pm 157.80$	$<.01$	Sig
Class III	$827.78 \pm 114.08$	$782.45 \pm 112.23$	$6.31 \pm 76.23$	$>.05$	NS



**Graph 3:** Nasopharynx at pre & post of class -II & class-III subjects (mm<sup>2</sup>)

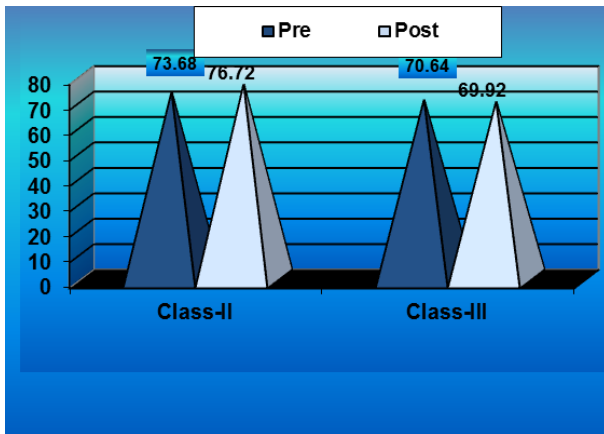
**Table IV**

The mean of vertical height of hyoid bone of class II pre-treatment was  $76.63 \pm 9.26$  mm and post treatment was  $76.72 \pm 9$  mm. It was observed that vertical height the post treatment was increased. The mean change in vertical height from pre to post treatment was  $3.04 \pm 3.43$  mm. The mean changed in vertical height was highly significant (HS).

The mean of vertical height of class III pre-treatment was  $70.64 \pm 6.45$  mm and post treatment had decreased. The mean change in vertical height from pre to post treatment was  $72 \pm 3.43$  mm. The mean changed in vertical height was not significant (NS).

**Table 4:** Mean ± SD Nasopharynx at pre & post of class –II & class-III subjects (mm<sup>2</sup>) (mm).

Group	Mean ± SD		Mean change ±SD	P-value	Sing
	Pre	Post			
Class II	73.68± 9.26	76.72± 9.19	3.04±3.43	<.001	HS
Class III	70.64 ± 6.45	69.92± 6.16	0.72± 3.42	>.05	NS



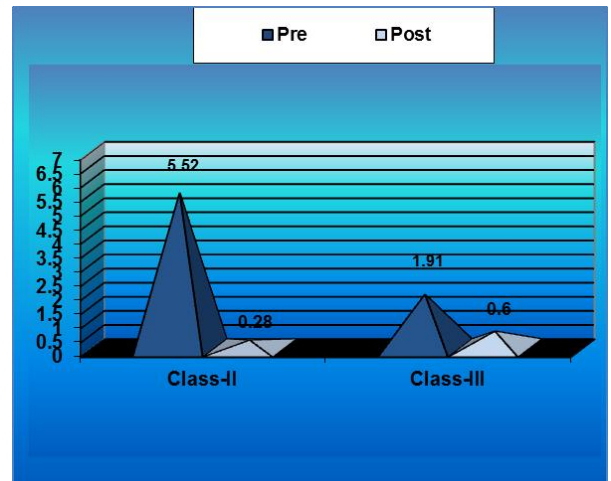
**Graph 4:** Nasopharynx at pre & post of class –II & class-III subjects

**Table V**

The mean of antero-posterior position of hyoid bone of class II pre-treatment was 5.52± 3.46 mm and post treatment was 6.28 ± 4.22mm. It was observed that antero-posterior position of hyoid bone post treatment was altered. The mean change in position from pre to post treatment was 0.76 ± 1.88 mm. The mean change was not significant (NS). The mean of antero-position of hyoid bone of class III pre-treatment was 0.28 ± 3.28 mm and post treatment was 0.60 ± 3.50 mm. It was observed that anterior posterior of hyoid bone post treatment was altered.

**Table 5:** Mean ± SD antero-posterior position pre and post treatment of class II & class III subjects (mm).

Group	Mean ± SD		Mean change ±SD	P-value	Sing
	Pre	Post			
Class II	5.52 ± 3.46	6.28 ± 4.22	0.76± 1.88	>.05	NS
Class III	0.28 ± 3.28	0.60 ± 3.50	0.32± 3.39	>.05	NS



**Graph 5:** Antero-Posterior position pre and post treatment of class II & class III subjects

The mean change in position from pre to post treatment was 0.38± 3.39 mm. The mean changed in antero-posterior position was not significant (NS).

**DISCUSSION**

Since, frequency and potential orthodontic consequences of nasopharyngeal obstruction are relatively high, it is important to have a simple, economical, readily available and reproducible way to diagnose upper airway obstruction. First, it was found that the capacity of lateral cephalograms for diagnosing posterior upper airway obstructions depended on 2 main features i.e. on the lateral cephalogram size of the adenoid and size of the nasopharynx. Both features can be evaluated by linear size measurements, area measurements and subjective classification<sup>27</sup>.

It has been mentioned in the literature that malocclusion type does not influence pharyngeal airway width<sup>28-30</sup>. When the Angle skeletal classification is taken into account, it was observed that Class I and Class III subjects had significantly larger airway volumes compared with Class II subjects. Alves<sup>30</sup> et al found a significant oropharyngeal volume difference between the sexes for the retropalatal and retroglossal regions for the Class III group, but no significant difference was observed for the nasal cavity volume. This might differ in this study because of the different anatomic limits to define the airway. Kim et al<sup>31</sup> stated that retrognathic patients tended to have a smaller airway volume compared with patients with a

normal anteroposterior skeletal relationship. In this study, it was found that subjects with a more retruded mandibular position with respect to the cranial base tended to have smaller OP airway volumes. Also, a significant increase in Class II cases showed increase in upper and lower pharyngeal air space (PAS) whereas in case of Class III there was no significant change in PAS in both Mc Namara and Handelman and Osborne analysis. For this two mechanisms are possible. First, anterior movement of the tongue may decrease the gravitational effect on the soft palate and it is assumed that the base of the tongue opposes the anterior wall of the soft palate. Second, forward displacement of the mandible may decrease collapsibility of the velopharynx because the lateral wall of the soft palate anatomically connects to the base of the tongue through the palatoglossal arch, and mandibular advancement possibly stretches the soft palate through the mechanical connection, stiffening the velopharyngeal segment.

The absence of significant changes in the anteroposterior position of the hyoid bone in relation to the anterior pharyngeal wall in this study might indicate that physiologic adaptations occurred to ensure maintenance of the airway. It seemed that the movement of the hyoid bone was directed downwards and not backwards since its postsurgical distance from the maxilla and the mandible increased and the distance from the mandibular symphysis and gonial angle decreased. These interpretations must be taken into consideration as the cephalometric parameters used did not allow always complete representation of the hyoid bone movement. The presence, for example, of an insignificant change in the distance from the hyoid bone to the anterior cranial base may be attributed to the remote location of this anatomic region and the relatively minor change of the position of the hyoid bone. But it can also cause narrowing of the pharyngeal airway space (PAS) and changes in the position of the hyoid bone and the tongue<sup>32</sup>. Pharyngeal airway narrowing can cause obstructive sleep apnoea syndrome (OSAS)<sup>33</sup>. Riley et al<sup>34</sup> suggested that mandibular setback might contribute to further development of OSAS after surgery and it could be associated with airway patency because airway resistance appears to increase after surgery<sup>35</sup>. Kawakami et al<sup>28</sup> demonstrated that PAS was maintained shortly

after mandibular setback surgery, whereas the hyoid bone moved inferiorly to compensate for the reduction in the oral volume. The positions of the tongue and the hyoid bone are also thought to change after mandibular setback surgery<sup>36-38</sup>.

In a study, Wickwire et al<sup>39</sup> found that the hyoid bone was displaced posteriorly in 19 patients and downward in 17 of the 22 patients. However, its position in long-term follow-up examinations (6 to 24 months) showed a pattern of continuous change, with a somewhat anterior repositioning in half of the subjects. According to the observations in this study vertical distance in Class II cases showed highly significant result, but the direction of shift of hyoid bone was different in all the cases not generally downwards and backwards as advocated. Wickwire et al<sup>39</sup> and Lew<sup>40</sup> showed that the hyoid bone progressively returns to its original position, whereas the postsurgical decrease in hypopharyngeal airway space is maintained during the follow-up period<sup>41</sup>. It was assumed that a reflex alteration in the pharyngeal muscular mechanism and the biomechanical conditions of the supra and infrahyoid muscles takes place postoperatively in patients seeking orthognathic surgery often are characterized by altered patterns of craniomandibular neuromuscular function, which differ from those of the normal or healthy population. Therefore, it is important that a detailed clinical examination and an accurate diagnosis precede this interdisciplinary management.

## CONCLUSION

Current evidence suggests that the greatest use of lateral cephalograms is as a screening tool for determining whether more intensive follow up is needed. Position of hyoid bone changes in class II malocclusion but the direction of hyoid bone was not backward and downward in every direction after treatment.

## CONFLICT OF INTEREST

No potential conflict of interest relevant to this article was reported.

## REFERENCES

1. Handelman CS, Osborne G, Growth of the nasopharynx and adenoid development from

- one to eighteen years. *Angle Orthod.* 1976;46(3):243-59.
2. Subtelny JD, Baker HK. The significance of adenoid tissue in velopharyngeal function. *Plast Reconstr Surg* (1946). 1956;17(3):235-50.
  3. Forum on the tonsil and adenoid problem in orthodontics. Questions and answers. *Am J Orthod.* 1968;54(7):508-14.
  4. Tomes CS: On the developmental origin of the v-shaped contracted maxilla. *Monthly review of Dental Surgery* 1872:1.2-5.
  5. Ackerman JL, Proffit WR. Soft tissue limitations in orthodontics: treatment planning guidelines. *Angle Orthod.* 1997;67(5):327-36.
  6. Hellsing E1, Hagberg C. Changes in maximum bite force related to extension of the head. *Eur J Orthod.* 1990;12(2):148-53.
  7. Ono T, Ishiwata Y, Kuroda T. Inhibition of masseteric electromyographic activity during oral respiration. *Am J Orthod Dentofacial Orthop* 1998;113(5):518-25
  8. Behlfelt K1, Linder-Aronson S, Neander P. Posture of the head, the hyoid bone, and the tongue in children with and without enlarged tonsils. *Eur J Orthod.* 1990;12(4):458-67.
  9. Fukawa A. Two Class II, Division 1 patients with congenitally missing lower central incisors. *Am J Orthod Dentofacial Orthop.* 1993;104(5):425-43.
  10. Laine T, Warren DW. Effects of age, gender, and body size on nasal cross-sectional area in children. *Eur J Orthod.* 1991;13(4):311-6.
  11. Tourne LP. Growth of the pharynx and its physiologic implications. *Am J Orthod Dentofacial Orthop.* 1991;99(2):129-39.
  12. Johnston CD, Richardson A. Cephalometric changes in adult pharyngeal morphology. *Eur J Orthod.* 1999;21(4):357-62.
  13. Wang DY, Clement PA, Kaufman L, Derde MP. Chronic nasal obstruction in children. A fiberoptic study. *Rhinology.* 1995;33(1):4-6.
  14. Wang DY, Bernheim N, Kaufman L, Clement P. Assessment of adenoid size in children by fiberoptic examination. *Clin Otolaryngol Allied Sci.* 1997;22(2):172-7.
  15. Dolen WK, Spofford B, Selner JC. The hidden tonsils of Waldeyer's ring. *Ann Allergy* 1990;65(4):244-8.
  16. Vargervik K, Miller AJ, Chierici G, Harvold E, Tomer BS. Morphologic response to changes in neuromuscular patterns experimentally induced by altered modes of respiration. *Am J Orthod.* 1984;85(2):115-24.
  17. Valera FC, Travitzki LV, Mattar SE, Matsumoto MA, Elias AM, Anselmo-Lima WT. Muscular, functional and orthodontic changes in pre-school children with enlarged adenoids and tonsils. *Int J Pediatr Otorhinolaryngol.* 2003;67(7):761-70.
  18. Linder-Aronson S. Respiratory function in relation to facial morphology and the dentition. *Br J Orthod.* 1979;6(2):59-71.
  19. Lessa FC, Enoki C, Feres MF, Valera FC, Lima WT, Matsumoto MA. Breathing mode influence in craniofacial development. *Braz J Otorhinolaryngol.* 2005;71(2):156-60.
  20. Mattar SE1, Anselmo-Lima WT, Valera FC, Matsumoto MA. Skeletal and occlusal characteristics in mouth-breathing pre-school children. *J Clin Pediatr Dent* 2004;28(4):315-8.
  21. Peltomäki T. The effect of mode of breathing on craniofacial growth-revisited. *Eur J Orthod* 2007;29(5):426-9.
  22. Pelikan RC, Iwata J, Suzuki A, Chai Y, Hacia JG. Identification of candidate downstream targets of TGF $\beta$  signaling during palate development by genome-wide transcript profiling. *J Cell Biochem.* 2013;114(4):796-807.

23. Woodside DG, Linder-Aronson S. The channelization of upper and lower anterior face heights compared to population standard in males between ages 6 to 20 years. *Eur J Orthod.* 1979;1(1):25-40.
24. Järund M, Dellborg C, Carlson J, Lauritzen C, Ejnell H. Treatment of sleep apnoea with continuous positive airway pressure in children with craniofacial malformations. *Scand J Plast Reconstr Surg Hand Surg.* 1999;33(1):67-71.
25. McNamara JA Jr. A method of cephalometric evaluation. *Am J Orthod* 1984;86(6):449-69.
26. Handelman CS, Osborne G. Growth of the nasopharynx and adenoid development from one to eighteen years. *Angle Orthod* 1976;46(3):243-59.
27. Major MP, Flores-Mir C, Major PW. Assessment of lateral cephalometric diagnosis of adenoid hypertrophy and posterior upper airway obstruction: a systematic review. *Am J Orthod Dentofacial Orthop.* 2006;130(6):700-8.
28. Watson RM Jr, Warren DW, Fischer ND. Nasal resistance, skeletal classification, and mouth breathing in orthodontic patients. *Am J Orthod.* 1968;54(5):367-79.
29. de Freitas MR, Alcazar NM, Janson G, de Freitas KM, Henriques JF. Upper and lower pharyngeal airways in subjects with Class I and Class II malocclusions and different growth patterns. *Am J Orthod Dentofacial Orthop.* 2006;130(6):742-5.
30. Alves PV, Zhao L, O'Gara M, Patel PK, Bolognese AM. Three-dimensional cephalometric study of upper airway space in skeletal class II and III healthy patients *J Craniofac Surg.* 2008;19(6):1497-507.
31. Kim YJ, Hong JS, Hwang YI, Park YH. Three-dimensional analysis of pharyngeal airway in preadolescent children with different anteroposterior skeletal patterns. *Am J Orthod Dentofacial Orthop.* 2010;137(3):306.e1-11.
32. Gjørup H, Athanasiou AE. Soft-tissue and dentoskeletal profile changes associated with mandibular setback osteotomy. *Am J Orthod Dentofacial Orthop.* 1991;100(4):312-23.
33. Hoekema A1, Hovinga B, Stegenga B, De Bont LG. Craniofacial morphology and obstructive sleep apnoea: a cephalometric analysis. *J Oral Rehabil* 2003;30(7):690-6.
34. Riley RW, Powell NB, Guilleminault C, Ware W. Obstructive sleep apnoea syndrome following surgery for mandibular prognathism. *J Oral Maxillofac Surg.* 1987;45(5):450-2.
35. Kawakami M, Yamamoto K, Fujimoto M, Ohgi K, Inoue M, Kirita T. Changes in tongue and hyoid positions, and posterior airway space following mandibular setback surgery. *J Craniomaxillofac Surg.* 2005;33(2):107-10.
36. Athanasiou AE, Toutountzakis N, Mavreas D, Ritzau M, Wenzel A. Alterations of hyoid bone position and pharyngeal depth and their relationship after surgical correction of mandibular prognathism. *Am J Orthod Dentofacial Orthop.* 1991;100(3):259-65.
37. Wenzel A, Williams S, Ritzau M. Relationships of changes in craniofacial morphology, head posture, and nasopharyngeal airwaysize following mandibular osteotomy. *Am J Orthod Dentofacial Orthop* 1989;96(2):138-43.
38. Wenzel A, Williams S, Ritzau M. Changes in head posture and nasopharyngeal airway following surgical correction of mandibular prognathism. *Eur J Orthod* 1989;11(1):37-42.
39. Wickwire NA, White RP Jr, Proffit WR. The effect of mandibular osteotomy on tongue position. *J Oral Surg* 1972;30(3):184-90.
40. Lew KK. Changes in tongue and hyoid bone positions following anterior mandibular subapical osteotomy in patients with Class III malocclusion. *Int J Adult Orthodon Orthognath Surg.* 1993;8(2):123-8.
41. Enacar A, Aksoy AU, Sençift Y, Haydar B, Aras K. Changes in hypopharyngeal airway space



and in tongue and hyoid bone positions following the surgical correction of mandibular prognathism. Int J Adult Orthodon Orthognath Surg. 1994;9(4):285-90.

**How to cite this article:**

Yadav D, Rai D, Gill V, Dosi A, Choudhary A. Importance and Calculation of Pharyngeal Spaces Pre and Post Surgical Treatment and Hyoid Position. Adv Hum Biol. 2015;5(1):5-13.