

Anaesthetic challenges in a child with a rare triad of kyphoscoliosis, neurofibromatosis and sickle cell trait

Aswale S¹, Gadkari C², Badwaik G³, Chauhan S¹, Deshmukh R⁴

Abstract:

Scoliosis is a complex deformity of spine and may be of varied etiology. It often poses a challenge in its anaesthetic management. We present anaesthetic management of a child who underwent scoliosis reconstruction with a rare triad of kyphoscoliosis, Neurofibromatosis type 1 (NF1, von Recklinghausen's disease) and sickle cell trait. Anaesthetic management of this case is challenging as it focuses on systemic changes particularly, cardiovascular, respiratory and nervous systems; related to deformity, pharmacological alteration due to Neurofibromatosis, precautions related to sickle cell trait as under unusual circumstances serious morbidity or mortality can result from complications related to polymerization of deoxy-hemoglobin S and the younger age group. Anaesthetic management in these patients with this triad was focussed primarily on optimisation of cardio-respiratory functions. Comprehensive pre-operative strategy and perioperative management of all coexisting diseases enables a successful outcome after the surgery.

¹Senior Resident, ²Associate Professor, ³Assistant Professor, ⁴Professor, NKP Salve Institute of Medical Sciences and Research Centre, Nagpur. drshwetaaswale@yahoo.com

Keywords: Kyphoscoliosis, Neurofibromatosis, Sickle cell trait, rare triad, hypotensive anesthesia

Introduction:

Neurofibromatosis type 1 (NF1, von Recklinghausen's disease) is an autosomal dominant single gene hereditary disorder of neural crest cells, involving neuroectoderm, mesoderm and endoderm. Scoliosis is a complex deformity of spine characterised by lateralisation of spinal curvature with malrotation of vertebrae and it mainly affects cardiovascular, respiratory and nervous systems. The scoliosis and dystrophy can be severe and progressive requiring surgical intervention (1). Sickle cell trait usually is not regarded as a disease state because it has complications that are either uncommon or mild. Nevertheless, under unusual circumstances serious morbidity or mortality can result from complications related to polymerization of deoxy-hemoglobin S.^[2] Anaesthetic management of these patients have special concerns due to associated co-morbidities, prolong duration of surgery, blood loss, hypothermia, intra-operative changes in positions. We managed a case of a child who underwent scoliosis reconstruction with a triad of Neurofibromatosis, sickle cell trait and kyphoscoliosis (2-5).

Case Report:

A 14 year old, 40 kg male child was admitted to surgery unit with complaints of deformity of spine and backache and was a diagnosed case of Neurofibromatosis type 1 and sickle cell trait (Figure

1-3). On examination, he had adequate mouth opening without any intraoral or external mass or deformity with Mallampati Class 1, without restricted neck movements. Breath holding time was reduced to 12 seconds. Chest was asymmetrical with air entry equal on both sides. There was no focal neurodeficit. Deformity of spine and backache were slowly progressive since 1 year with no neurodeficit with general and systemic examination within normal limits except asymmetrical chest however with bilaterally equal breath sounds. He had a severe thoracolumbar scoliosis (Cobb's angle 60 degree) and was planned for surgical correction of deformity (Figure 4). He was investigated with complete blood count, serum electrolytes, blood urea, serum creatinine, electrocardiogram, chest roentgenogram (PA and lateral view), pulmonary function tests, echocardiography with Color Doppler, CT thorax. His all biochemical laboratory investigations were within normal limits. Pulmonary function tests showed mild restriction without reversibility post-bronchodilator (Figure 5-6). Echocardiography showed moderate pulmonary artery hypertension (PASP-32mmHg) with ejection fraction-70%. MRI of thoracic spine was suggestive of short segment scoliosis from T6 to L3 with convexity towards the left side, straightening of cervical spine and plexiform neurofibromatosis in the sympathetic chain along the convexity of the curve. MRI brain was suggestive of abnormal myelination.

Risk and perioperative plan of anaesthesia was discussed with parents. High risk consent and informed consent were obtained. In operation theatre, all baseline monitors (non-invasive blood pressure, continuous ECG lead II, pulse-oximetre) were attached. Child was premedicated with Glycopyrrolate 160 mcg IV (using 1ml syringe for accuracy of dose), Midazolam 1.6 mg IV, Fentanyl 80mcg and Dexmedetomidine bolus 0.2 mcg/kg IV (3). Anaesthesia was induced with Propofol 80 mg and muscle relaxant Atracurium Besylate 20mg. Trachea was intubated with cuffed flexometallic endotracheal tube no. 6.5, in single attempt within 15 seconds. Anaesthesia was maintained with Dexmedetomidine infusion 0.7 mcg/kg/min, Fentanyl top ups, Atracurium top ups and Oxygen, Nitrous oxide with Isoflurane. Airway pressure and end tidal CO₂ monitoring were done. Right radial artery and left internal jugular vein cannulation were carried out for continuous hemodynamic and central pressure monitoring respectively.

Peripheral nerve stimulator was applied and urinary catheter and nasopharyngeal temperature probe were inserted. Appropriate measures to maintain normothermia were employed including warming blankets and warm fluid infusion. Hypotensive anaesthesia was given with use of Dexmedetomidine infusion, Fentanyl top ups and Isoflurane maintaining a mean arterial pressure around 60 mmHg. Tranexamic acid (loading dose of 10 mg/kg just before surgical incision followed by continuous infusion of 1 mg/kg hr) was also administered to minimise intra-operative blood loss. Surgery lasted for 7 hours with approximate losses of 1200 ml where minimal acceptable blood loss (MABL) was 400 ml. Interestingly enough, in an article by Kulkarni et al this much blood loss was acceptable and we adequately replaced it.^[4] We gave 4 litres of crystalloids and 700 ml of packed cell volume. Intraoperative analgesia was supplemented with Paracetamol (400mg) IV and Tramadol was given in addition to Fentanyl and Dexmedetomidine. Surgery was done in two parts. Part 1 consisted of transthoracic discectomy and release of scoliosis from anterior side was done in right lateral position. Part 2 consisted of D3-D11 transpedicular screw fixation & correction of scoliosis was done in prone position (Figure 7). Antibiotic cover of Cefazidime (25 mg/kg) IV and Vancomycin (15 mg/kg) IV were given. After completion of procedure, neuromuscular blockade was antagonised with Neostigmine 2 mg and Glycopyrrolate 160 mcg. After meeting with criteria of extubation, extubation was uneventfully done in supine position and patient was shifted to post-operative surgical intensive care unit. Post-operative analgesia was given with an initial IV loading dose of 100 mg Tramadol, followed by an

infusion of 12 mg/hr of Tramadol for 24 hours. If necessary repeated boluses of 50 mg Tramadol were given.^[5] Total dose of Tramadol given for postoperative analgesia was less than 300 mg with an acceptable VAS score of 3. Ondansetron cover of 4 mg IV was given for nausea and vomiting. Post operative chest physiotherapy including incentive spirometry was started. On day 5, patient was shifted to ward and subsequently discharged on 14th day without any complication.

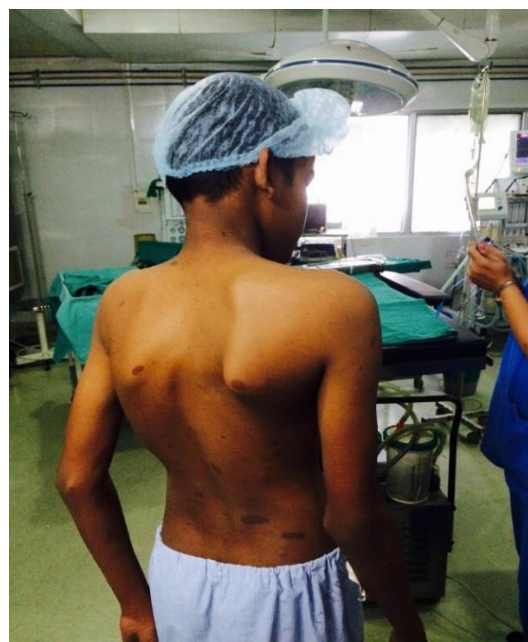

Fig.1: Side view of patient

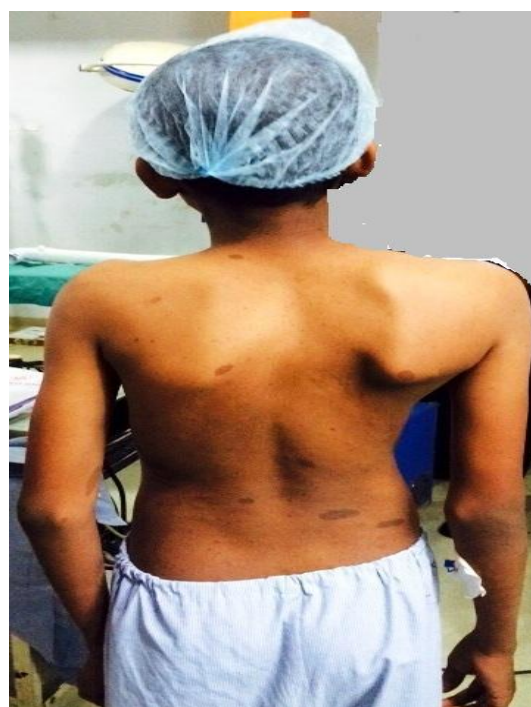

Fig.2: Back view of patient

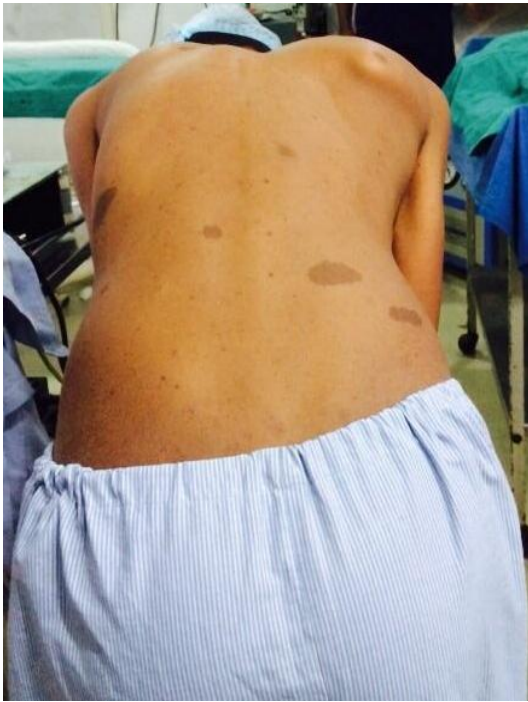

Fig.3: Patient leaning forward

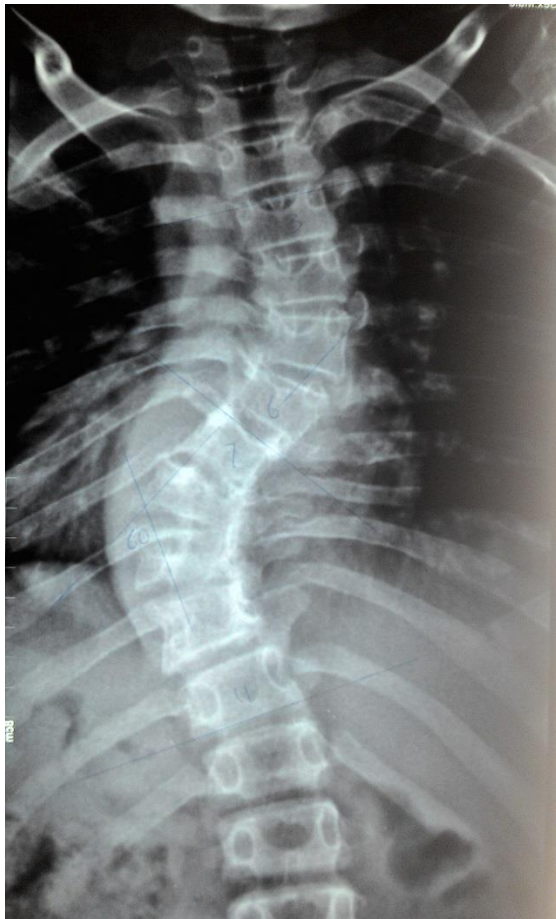

Fig.4: Chest X-Ray PA view showing Cobb's angle

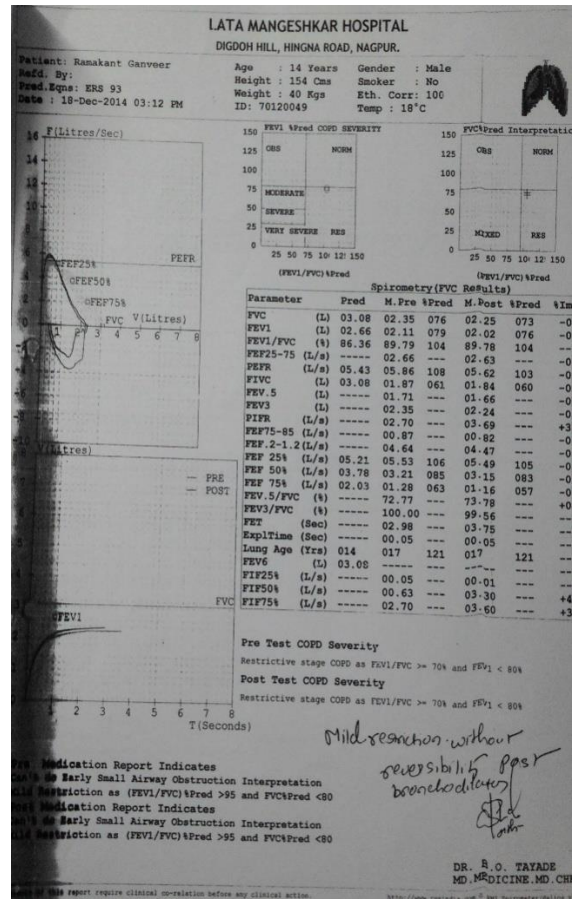


Fig.5: Pre-op PFT 1

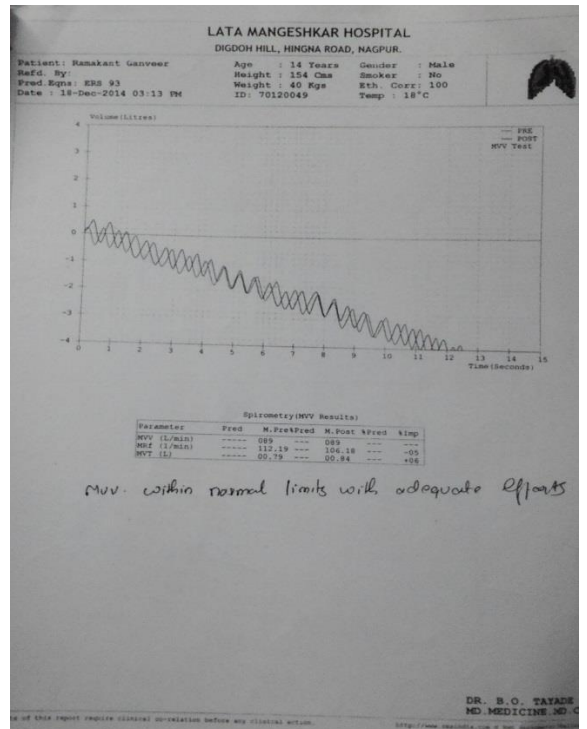


Fig.6: Pre-op PFT2

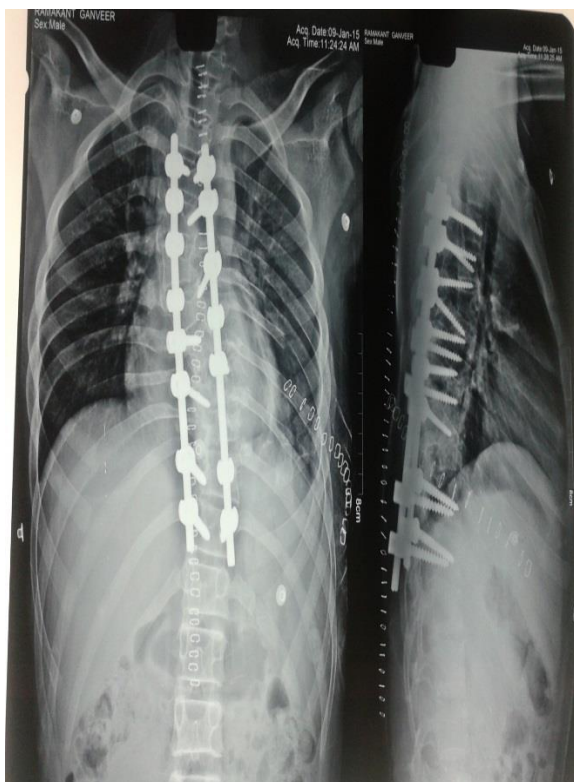


Fig.7: Chest X-Ray AP view and lateral view after corrective surgery

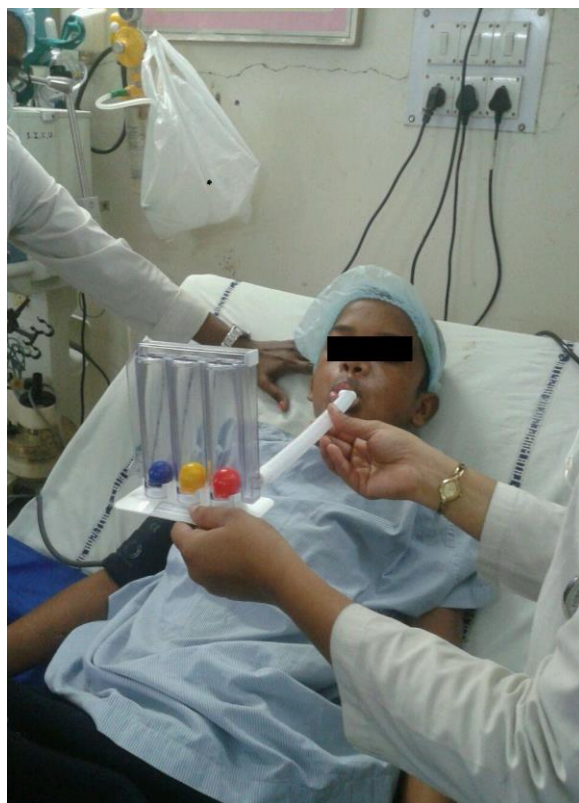

Fig.9: Post-Operative spirometry



Fig.8: Post-Operative positioning in SICU

Discussion:

Scoliosis is the most frequent musculoskeletal manifestation in Neurofibromatosis type 1. It occurs usually in the low thoracic region and has a prevalence ranging from 2% to 69% in the literature. Etiological theories regarding Neurofibromatosis type 1 related scoliosis include erosion or infiltration of bone by neurofibromas, primary mesodermal dysplasia, osteomalacia and endocrine disturbances (1). Neurofibromatosis is a group of hereditary diseases that are transmitted in an autosomal dominant fashion. They are characterized by formation of tumors of ectodermal and mesodermal tissues (endodermal tissue as well) and can therefore involve any organ system.

Pharmacological Aspects in Neurofibromatosis (6)

- Controversy surrounding sensitivity to neuromuscular blocking agents
- Both increased and decreased sensitivity has been reported
- The recommendation is to always use a nerve stimulator to monitor neuromuscular activity in patients with Neurofibromatosis

Sickle cell was an incidental finding seen in this patient. Under unusual circumstances serious morbidity or mortality can result from complications related to polymerization of deoxy-hemoglobin S.

Pathologic processes that cause hypoxia, acidosis, dehydration, hyperosmolality, hypothermia or elevated erythrocyte 2,3-DPG can transform silent sickle cell trait into a syndrome resembling sickle cell disease with vaso-occlusion due to rigid erythrocytes. Compound heterozygous sickle cell disease can be mistaken as uncomplicated sickle cell trait, particularly when an unusual globin variant is involved (2).

Perioperative anaesthetic precautions which we followed to prevent sickling (7):

- Titrated premedication in order to avoid ventilatory depression (hypoxemia)
- Anticipation of intraoperative fluid loss and adequate hydration (prevent hemoconcentration)
- Maintain normothermia (hypothermia actually prevents sickling, only because it causes vasoconstriction it has to be avoided, do not induce hyperthermia as it promotes sickling)
- Appropriate replacement of blood loss in order to reduce fraction of HbS thus reducing the likelihood of sickling.

We planned left internal jugular venous access, as left thoracotomy was planned. It may be difficult in these patients due to contractures and improper postures (8). We did it with conventional approach in single attempt as ultrasound facilities were not available at our institute.

Although literature shows association of Malignant Hyperthermia (MH) with myopathies in patients having scoliosis (8) but as he had no myopathy, so we preferred with use of inhalational anaesthetics for maintenance of anaesthesia (9). There is a high incidence of post-operative neurologic injury after major reconstructive spine surgery. Intraoperative neurological monitoring can improve patient outcome by allowing early detection of ischaemia before irreversible damage. Neuro-monitoring techniques to test spinal cord integrity during intraoperative period include somatosensory evoked potentials; transcranial motor evoked potentials, continuous and triggered electromyography activity and Stagnara wake-up test. We do not have the facility of advanced neurologic monitoring at our institute. In view of Cobb's angle being less than 90 degrees and no osteotomy (which is high risk for neurologic injury) (10) planned for this patient, it was decided to defer the wake up test as its role is controversial (11). Blood loss is another concern in scoliosis surgery. Common strategies to minimise blood loss in perioperative period include use of cell saver, recombinant factor VIIa and anti-fibrinolytic agents (aprotinin, tranexamic acid, epsilon-aminocaproic acid) (8). We administered

continuous infusion of tranexamic acid during the surgical procedure.

Although there are complications like nerve injury, accidental extubation, trauma to eye, pressure necrosis etc (12). We managed it by taking proper precautions related to adequate padding, securing endotracheal tube and becoming in-charge of the team while changing the position of the patient. Postoperatively we kept the patient in particular position in order to avoid stress over surgical site (Figure 8). Good chest physiotherapy with spirometry. Leg exercises were given to prevent deep vein thrombosis (Figure 9). Patient was discharged on 14th day post-operatively without any complications.

Conclusion:

Anaesthetic management in patient with scoliosis should focus primarily on optimisation of cardio-respiratory functions. Intraoperative considerations are monitoring, temperature maintenance, fluid balance, positioning, and blood conservation. Post operative intensive care, respiratory care and pain therapy deserve special mention. Anaesthetic drugs should be judiciously administered keeping in mind of the implications of sickle cell trait, Neurofibromatosis type 1 and Malignant Hyperthermia. Comprehensive pre-operative strategy and perioperative management of all coexisting diseases would enable a successful outcome after the surgery.

Acknowledgement:

I would like to thank Dr. Charuta Gadkari for her persistent help to write this case report.

References:

1. Bamps S, Calenbergh FV, Loon JV, Paesschen RV, Vanderschot P. Posterolateral approach in a neurofibromatosis type-I patient with severe dystrophic thoracickyphoscoliosis: A case report, cadaver study, and literature review. *JNeurosci Rural Pract* 2015;6:84-6.
2. Sickle cell trait, Home page, Available from: http://sickle.bwh.harvard.edu/sickle_trait.html (Last cited in 2015 February 9).
3. Mason KP, Lerman J. Review article: Dexmedetomidine in children: Current knowledge and future applications. *Anaesth Analg* 2011;113:1129-42.
4. Kulkarni AH, Ambareesha M. Scoliosis and anaesthetic considerations anaesthesia. *Indian Journal of Anaesthesia*. December 2007; 5(6):486-495.
5. Rüd U, Fischer MV, Mewes R, Paravicini D. Postoperative analgesia with tramadol. Continuous infusion versus repetitive bolus administration. *US National Library of Medicine* 1994 May; 43(5):316-21.
6. University of Kwazulu Natal, Home page, Available from: http://anaesthetics.ukzn.ac.za/Libraries/F..009/Neurofibromatosis_Dr_S_Naidu.sflb.ashx (Last cited in 2015 February 9).

7. Guidelines for the treatment of people with sickle cell disease, Home page, Available from:http://www.downstate.edu/anaesthesiology/residents/knowledge_hemotologic.html.
8. Singh J, Kapoor D, Srivastava M, Singh M. Anaesthetic management in a child with an atypical triad for reconstructive scoliosis surgery. *Indian Journal of Anaesthesia* 2013; 57(6):596-598.
9. Davis PJ, Brandom BW. The association of malignant hyperthermia and unusual disease: when you're hot you're hot or maybe not. *International Anesthesia Research Society* October 2009; 109(4): 27-29.
10. Acton QA. Kyphosis: new insights for the healthcare professional. *Scholarly Editions*. 2013;25(4):27.
11. Stagnara Wake Up Test. Available from: <http://boneandspine.com/stagnara-wake-up-test/> (Last cited in 2015 April 6).
12. Edgcombe H, Carter K, Yarrow S. Anaesthesia in the prone position. *British Journal of Anaesthesia* 2008; 100(2):165-183.