



Epidermoid/Dermoid cysts mimicking odontogenic infections: review of literature

Amin Rahpeyma (DDS)¹, Saeedeh Khajehahmadi (DDS)^{2*}, Ali Ghasemi(MD)³

¹Oral and Maxillofacial Diseases Research Center, Faculty of Dentistry, Mashhad University of Medical Sciences, Mashhad, Iran.

²Dental Research Center, Faculty of Dentistry, Mashhad University of Medical Sciences, Mashhad, Iran.

³Oral and Maxillofacial Diseases Research Center, Department of Pediatric Hematology and oncology, Faculty of Medicine, Mashhad University of Medical Sciences, Mashhad, Iran.

ARTICLE INFO

Article type

Review article

Article history

Received: 25 Nov 2014

Revised: 4 Jan 2015

Accepted: 10 Feb 2015

Keywords

Dermoid cyst

Epidermoid cyst

Odontogenic infection

ABSTRACT

Introduction: Dermoid/Epidermoid cysts are rare pathologic lesions that may involve the floor of the mouth. Infection and inflammation of the cyst can produce a clinical picture very similar to the submandibular and submental abscesses with odontogenic origin. Dermoid/epidermoid cysts are on the floor of the mouth with submental or submandibular component can be mistaken for odontogenic infections.

Methods: Four biopsy proven dermoid/epidermoid cysts operated in the Mashhad University of Medical Sciences, Ghaem hospital (2012-2013), were reviewed.

Results: Four patients, including two classic cases and two infected dermoid/epidermoid cysts, were erroneously diagnosed as odontogenic infection.

Discussion: The lesions located solely below mylohyoid muscle need to be removed through an extraoral approach but the lesions above the mylohyoid muscle or those that have both supra- and infra-mylohyoid components can be removed through an intraoral incision.

Conclusion: Dermoid/epidermoid cysts should be considered in the differential diagnosis of submental/submandibular swellings. In the absence of an odontogenic cause of infection, fine-needle aspiration biopsy and appropriate imaging evaluation techniques with sonography, CT or MRI are mandatory for correct diagnosis and surgical treatment planning. The clinicians should be very cautious to differentiate odontogenic infections from infected dermoid/epidermoid cysts.

Please cite this paper as:

Rahpeyma A, Khajehahmadi S, Ghasemi A. Epidermoid/Dermoid cysts mimicking odontogenic infections: review of literature. Rev Clin Med. 2015;2(4):190-194.

Introduction

Dermoid/epidermoid (D/E) cysts comprise 0.01% of all the oral cavity cysts. Among whole body D/E cysts, the oral cavity is responsible for 1.6%. Head and neck accounts for 7% of D/E and one-quarter of them are found at the floor of the mouth (FOM) (1). The most common location in the head and neck region is lateral aspect of the brow, followed by FOM (2). The most common sites for D/E cysts in the body are

testis and ovaries (3). The exact pathogenesis is unknown but the most acceptable theory is entrapment of the epithelium during fusion of the mandibular and hyoid arches (the first and second brachial arches) during the 3rd and 4th weeks of gestations in the embryonic period(4). FOM D/E cysts with submental or submandibular component can be mistaken for odontogenic infections (5).

***Corresponding author:** Saeedeh Khajehahmadi.

Dental Research Center, Faculty of Dentistry, Mashhad University of Medical Sciences, Mashhad, Iran.

E-mail: KhajehahmadiS@mums.ac.ir

Tel: 05138829501

This is an Open Access article distributed under the terms of the Creative Commons Attribution License (<http://creativecommons.org/licenses/by/3.0>), which permits unrestricted use, distribution, and reproduction in any medium, provided the original work is properly cited.

Methods and patients

Four biopsy proven D/E cysts operated in the Mashhad University of Medical Science, Ghaem hospital (from 2012-2013) were reviewed.

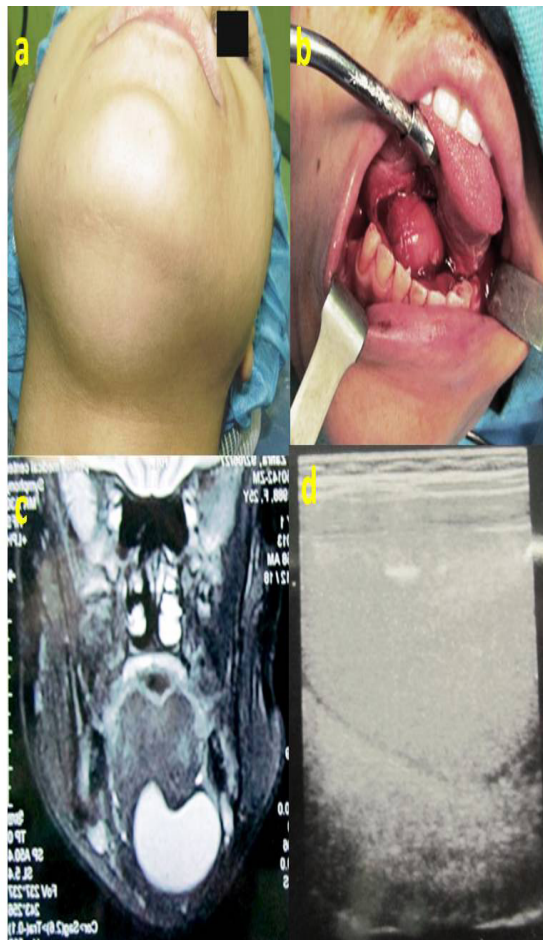Patients

Case 1 (classic case)

The patient was a 24-year-old female with a 6-month history of submental swelling and double chin appearance. The patient thought that this swelling had dental origin so she was attended to a dentist.

No pain, tenderness and discomfort were reported by the patient. Submental swelling was firm in palpation and fine needle aspiration (FNA) was not productive. Sonography showed a cystic cavity, measuring 45×39×22mm, filled with homogenous material. Magnetic resonance imaging (MRI) of the lesion showed a large lesion with both intraoral (FOM) and extraoral (submental) components. The lesion was enucleated by incision through the sublingual frenum (Fig.1).

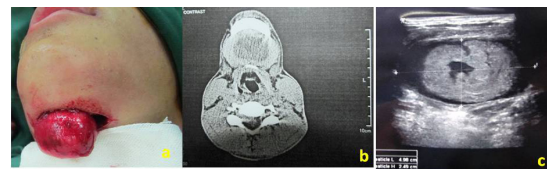
Figure 1. a, Double chin appearance. b, Epidermoid cyst was removed by an intraoral incision. c, MRI showed mid-line location of the lesion with both intraoral and submental components with extension to the left. d, Hypoechoic material filling the cystic cavity in obtained sonography



Case 2 (classic case)

The patient was a 15-year-old boy with a two-month history of submental swelling without any pain or tenderness. The lesion was not palpable when bimanual palpation was used for examination. Clinical appearance was similar to the patients with submental abscess. He reported a decrease in the size of the lesion after a course of antibiotic therapy prescribed by a dentist. Sonography showed a cystic cavity which was filled with hypoechoic material, measuring 50mm×25mm. Computerized tomography (CT) scan showed that the lesion was located beneath the mylohyoid muscle; therefore, it was enucleated using a 5-cm horizontal submental skin incision. Sharp dissection through skin, platysma, anterior belly of digastric muscles and blunt dissection around the cyst was carried out by a blunt-tip hemostat and finger ends (Fig.2).

Figure 2. An extraoral submental incision was used to remove the lesion. b, CT scan showed a lesion that extended from the mandibular bone to the hyoid bone. c, Corrugated material within the cyst in sonography.



Case 3

The patient was a 28-year-old male with a swelling in the right submandibular region. The overlying skin was red and the beard was sparse in the region; it was painful in palpation. Jaw radiography showed a carious second permanent molar with a periapical lesion.

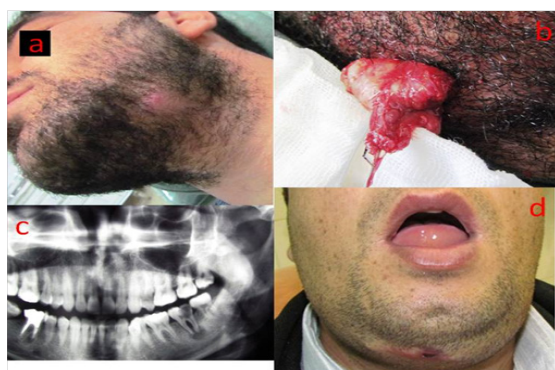With a provisional diagnosis of submandibular space abscess with odontogenic origin the patient was prepared for extraoral incision and drainage (I & D) under local anesthesia.

During hemostat penetration, a cheesy material extruded; therefore, with a tentative diagnosis of D/E cyst, the skin incision was extended and the lesion was removed totally. Histopathologic examination revealed an infected epidermoid cyst (Fig.3a-c).

Case 4

The patient was a 35-year-old male with a persistent fistula in the submental region. The patient reported a history of an abscess that was drained two years ago for the first time and now it was the third time that he attended for abscess drainage. Intraoral examination and radiographic evaluation revealed no odontogenic cause. Incisional biopsy was carried out and the pathologist reported an epidermoid cyst. He did not accept surgical treatment for the removal of the lesion (Fig.3d).

Figure 3. a, Erythema and alopecia of the skin in the submandibular region. b, Enucleated lesion. c, Panoramic view of the jaws showed a carious mandibular second molar with a periapical lesion. d, Submental swelling with persistent fistula.



Results

Four patients, including two classic cases and two infected D/E cysts, which were erroneously diagnosed as odontogenic infection, are reported.

Discussion

Dermoid cyst is a general term used to describe cysts in the submental area and floor of the mouth, which contains keratin. However, there is a need for definite histopathologic criteria such as hair follicles and other skin appendages (sebaceous glands) for applying the term “dermoid cyst” to such entities (6). Most of these lesions are epidermoid cysts, with the cystic cavity filled with keratin and surrounded by keratinized squamous epithelium. Respiratory epithelium (ciliated pseudostratified columnar epithelium) is also reported in some areas of cyst lining. However, gastrointestinal epithelium with its endodermal origin is in conflict with the diagnosis of D/E cysts (7).

In very rare instances, teratoid lesions with tissues originating from all the three embryonic layers of endoderm, mesoderm and ectoderm (muscle, bone, cartilage, gastrointestinal epithelium) and other histopathologic criteria similar to D/E cystic are presented (8). Mainly, there is one D/E in FOM but multiple D/E cysts have also been reported (9).

Double chin appearance in a young adult patient, in an alert clinician, should provoke the diagnosis of D/E cyst. If the lesion has a submental component, it is an esthetic problem that forces the patient to seek treatment. Other reported symptoms are odynophagia, dysphagia, snoring, shortness of the breath, Ludwig angina, gagging, obstructive sleep apnea syndrome and odontogenic abscess (10-12). It can induce functional disorders in swallowing, chewing and vocal function.

Ultrasonography is a highly recommended tool for evaluating submental swellings. It is inexpensive, reliable and without risks of radiation exposure (13).

Plain radiographs have no role in the diagnosis

except when radiopaque contrast media are injected into the cyst lumen.

MRI and CT scan have important roles in selecting an intraoral or extraoral approach to remove a D/E cyst from the floor of the mouth.

The lesions located solely below mylohyoid muscle need to be removed through an extraoral approach but the lesions above the mylohyoid muscle or those that have both supra- and infra-mylohyoid components can be removed through an intraoral incision. The best route for intraoral incision in D/E cysts in the midline is a sagittal incision of the oral mucosa along the lingual frenum (14). Through this route even very large cysts with both submental and FOM components can be removed. Endoscopy can assist in intraoral resection of external dermoid cysts (15).

The midline sagittal glossectomy for large FOM D/E cysts has been reported (16).

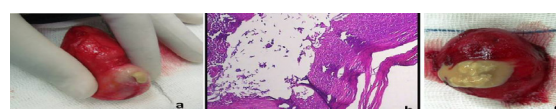
U-shaped superiorly based flap or inferiorly based flaps in the floor of the mouth for the removal of D/E cysts have also been described (17,18).

Extraoral access has disadvantages of skin scar and probability of keloid formation. A combination of intraoral and extraoral incisions has also been reported (19). In large deep lateral D/E cysts, sometimes the submandibular salivary gland should be removed to gain access to the cyst.

The majority of the patients are asymptomatic, but emergency appointments mainly for breathing problems have been mentioned in the literature (20). Anesthetic management of these patients is mainly similar to the other maxillofacial patients but in huge lesions of the floor of the mouth, intubation is difficult. Emptying the cyst content by aspiration is a useful aid to help tracheal intubation (21). There is a report of a case in the literature, in which tracheostomy was carried out for securing the airway due to an infected dermoid cyst (22). FNA for the diagnosis of dermoid cyst was first attracted attention in 1996 (23). Nowadays, it has gained paramount importance in the diagnosis of D/E cysts. In differential diagnosis of submental FOM swellings, ranula, branchial cleft cysts and lymphangioma are at the top of the list.

Keratin and enucleated squamous cells with or without inflammatory cells are pathognomonic for

Figure 4. a, Enucleated lesion at the bench. A small incision in the capsule and firm pressure on the cyst extruded cheesy material (keratin). b, Histopathologic examination showed keratin and keratinized stratified squamous epithelium (H-E×100). c, Pus and doughy material extruding from the cyst after incision of the capsule.



the diagnosis of D/E cysts (Fig.4) (24). Occurrence of infection after FNA biopsy has been reported (25).

If the cystic cavity is filled with highly viscous material, then FNA is not productive (26). Sudden enlargement of D/E cysts often occurs after infection but pregnancy and puberty with increased production of sebum have been reported in dermoid cysts (27,28). Very rare incidence of malignant changes in D/E cysts has been established (29). The first case in maxillofacial region was reported in 2000 (30). Symptomatic cases with submental/submandibular swellings, erythema of the overlying skin and localized alopecia over the inflamed region might be mistaken for an odontogenic infection, especially if decayed teeth are present in the mandibular arch on the same side. Presence of carious teeth in the lower jaw can confuse even an experienced clinician. Extrusion of cheesy material during incision and drainage should alert the clinician to the false diagnosis and the need for further evaluation. Recurrence after en bloc enucleation of the cyst has not been reported. Rupture of the cyst during removal and incomplete removal of the cyst may lead to recurrence. Rupture of the cyst and release of keratin into the wound evoke inflammatory responses. In cases in which intraoral route is used for the removal of large D/E cysts and the rupture happens, special attention to maintaining the airway in the post-operative period is mandatory. The study of Uval et al. about the neck masses confined to the submental region, showed that the clinical picture of the lesion could be complicated by dental problems (31). Differential diagnosis between D/E cysts and swelling caused by dental infection is necessary because surgical excision is mainstay of treatment for D/E cysts while incision and drainage, administration of systemic antibiotics and eliminating the cause of dental infection, are treatments used for odontogenic infections (32).

Conclusion

D/E cysts should be considered in the differential diagnosis of submental/submandibular swellings. In the absence of an odontogenic cause of infection, fine-needle aspiration biopsy and appropriate imaging evaluation techniques with sonography, CT or MRI are mandatory for correct diagnosis and surgical treatment planning. The clinician should be very cautious to differentiate odontogenic infections from infected D/E cysts.

Acknowledgement

We would like to thank Mrs Effat Momenizadeh who is nurse operating room in Omalbanin Hospital for her assistant in this research and Clinical Research Development Unit of Ghaem Hospital for

their assistant in this manuscript.

Conflict of Interest

The authors declare no conflict of interest.

References

1. Pirgousis P, Fernandes R. Giant submental dermoid cysts with near total obstruction of the oral cavity: report of 2 cases. *J Oral Maxillofac Surg.* 2011;69:532-535.
2. Mammen S, Korulla A, Paul M. An epidermal cyst in the floor of the mouth: a rare presentation. *Journal of clinical and diagnostic research: JCDR.* 2013;7:381.
3. Hoffman JG, Strickland JL, Yin J. Virilizing ovarian dermoid cyst with Leydig cells. *J Pediatr Adolesc Gynecol.* 2009;22:e39-e40.
4. Jain H, Singh S, Singh A. Giant sublingual dermoid cyst in floor of the mouth. *J Maxillofac Oral Surg.* 2012;11:235-237.
5. Grevers G, Ihrler S, Vogl T. [Current diagnosis and therapy of cysts of the mouth floor]. *Laryngo-rhino-otologie.* 1991;70:690-694.
6. Baisakhiya N, Deshmukh P. Unusual sites of epidermoid cyst. *Indian Journal of Otolaryngology and Head & Neck Surgery.* 2011;63:149-151.
7. Ho M, Crean S. Simultaneous occurrence of sublingual dermoid cyst and oral alimentary tract cyst in an infant: a case report and review of the literature. *Int J Paediatr Dent.* 2003;13:441-446.
8. Gordon PE, Faquin WC, Lahey E, et al. Floor-of-mouth dermoid cysts: report of 3 variants and a suggested change in terminology. *J Oral Maxillofac Surg.* 2013;71:1034-1041.
9. King RC, Smith BR, Burk JL. Dermoid cyst in the floor of the mouth: review of the literature and case reports. *Oral Surg Oral Med Oral Pathol.* 1994;78:567-576.
10. Seah T, Sufyan W, Singh B. Case report of a dermoid cyst at the floor of the mouth. *ANNALS-ACADEMY OF MEDICINE SINGAPORE.* 2004;33:77-79.
11. Goldman J, Barnes D, Pohl D. Obstructive sleep apnoea due to a dermoid cyst of the floor of the mouth. *Thorax.* 1990;45:76.
12. Westphal D, Reil B. [Infected dermoid and epidermoid cysts in the maxillofacial region. Differential diagnosis and therapy]. *Dtsch Zahnärztl Z.* 1978;33:804-807.
13. Makos C, Noussios G, Peios M, et al. Dermoid cysts of the floor of the mouth: two case reports. *Case reports in medicine.* 2011;2011.
14. Di Francesco A, Chiapasco M, Biglioli F, et al. Intraoral approach to large dermoid cysts of the floor of the mouth: a technical note. *Int J Oral Maxillofac Surg.* 1995;24:233-235.
15. Kim JP, Park JJ, Jeon SY, et al. Endoscope-assisted intraoral resection of external dermoid cyst. *Head Neck.* 2012;34:907-910.
16. Longo F, Maremonti P, Mangone GM, et al. Midline (dermoid) cysts of the floor of the mouth: report of 16 cases and review of surgical techniques. *Plast Reconstr Surg.* 2003;112:1560-1565.
17. Eken M, Oktay Z, Ayduran E, et al. Enucleating the large and median geniohyoid dermoid cysts of the floor of the mouth with intraoral inferior based U-shaped flap technique: how we do it. *Clin Otolaryngol.* 2009;34:479-481.
18. Eken M, Evren C, Sanli A, et al. An alternative surgical approach for sublingual dermoid cysts: a case report. *Kulak burun bogaz ihtisas dergisi: KBB= Journal of ear, nose, and throat.* 2006;17:176-178.
19. Papadogeorgakis N, Kalfarentzos EF, Vourlakou C, et al. Surgical management of a large median dermoid cyst of the neck causing airway obstruction. A case report. *Oral Maxillofac Surg.* 2009;13:181-184.
20. El-Hakim I, Alyamani A. Alternative surgical approaches for excision of dermoid cyst of the floor of mouth. *Int J Oral Maxillofac Surg.* 2008;37:497-499.
21. Raveenthiran V, Sam CJ, Srinivasan SK. A simple approach to airway management for a giant sublingual dermoid cyst. *Canadian Journal of Anesthesia/Journal canadien d'anesthésie.* 2006;53:1265-1266.

22. Arcand P, Granger J, Brochu P. Congenital dermoid cyst of the oral cavity with gastric choristoma. *The Journal of otolaryngology*. 1988;17:219-222.
23. Cramer H, Lampe H, Downing P. Dermoid cyst of the floor of the mouth diagnosed by fine needle aspiration cytology. *Acta Cytol*. 1996;40:319-326.
24. Jham BC, Duraes GV, Jham AC, et al. Epidermoid cyst of the floor of the mouth: a case report. *Journal-Canadian Dental Association*. 2007;73:525.
25. Filho PRSM, de Souza Andrade ES. Iatrogenic infection in dermoid cysts of the floor of the mouth. *Braz J Otorhinolaryngol*. 2011;77:675.
26. Santiago JC, Pellicer SM, Ramos AR, et al., editors. [Dermoid cyst of the floor of the mouth. A case report]. *Anales otorrinolaringologicos ibero-americanos*; 2001.
27. Tuz M, Dogru H, Uygur K, et al. Rapidly growing sublingual dermoid cyst throughout pregnancy. *Am J Otolaryngol*. 2003;24:334-337.
28. Pepe F, Panella M, Pepe G, et al. Dermoid cysts of the ovary. *Eur J Gynaecol Oncol*. 1985;7:186-191.
29. Crouet H, de Ranieri E, de Ranieri J. [Secondary cancers arising in mature benign cystic teratomas of the ovary (dermoid cysts). Review of the literature apropos of a new case]. *J Gynecol Obstet Biol Reprod (Paris)*. 1985;15:1055-1066.
30. Devine J, Jones D. Carcinomatous transformation of a sublingual dermoid cyst. *Int J Oral Maxillofac Surg*. 2000;29:126-127.
31. Ural A, Imamoglu M, Isik AÜ, et al. Neck masses confined to the submental space: Our experience with 24 cases. *Ear, Nose & Throat Journal*. 2011;90:538.
32. Al-Sebaei M, Papageorge M. A clinico-pathologic correlation. *Dermoid cyst*. *J Mass Dent Soc*. 2004;53:38.