

Journal of Coastal Life Medicine

journal homepage: www.jclmm.com



Document heading

doi: 10.12980/JCLM.3.2015JCLM-2014-0094

©2015 by the Journal of Coastal Life Medicine. All rights reserved.

Selenium ameliorates carbimazole induced hepatotoxicity and oxidative stress in Albino rats

Saber Abdel-Rahman Sakr*, Faten Roshdy Abdel-Ghafar, Samah Mohamed Abo-El-Yazid

Zoology Department, Faculty of Science, Menoufia University, Shebin El-Kom, Egypt

PEER REVIEW

ABSTRACT

Peer reviewer

Prof. Dr. Shaaban A. Mousa, Ph.D.,
Department of Anesthesiology and
Intensive Care Medicine, Charité
University Berlin, Campus Virchow
Klinikum and Campus Charite Mitte,
Augustenburgerplatz 1, 13353 Berlin,
Germany.

Tel: +49-30-450551219

Fax: +49-30-450551919

E-mail: shaaban.mousa@charite.de

Comments

This is a good study in which the authors examined the use of trace element such as selenium in the liver histological and biochemical damage induced by the antithyroid drug, carbimazole in albino rats. The result is interesting and suggested that selenium may be successfully used with carbimazole treatment with minimum side effects.

Details on Page 143

Objective: To evaluate the effect of the antithyroid drug, carbimazole on liver of albino rats and the possible ameliorative role of selenium.

Methods: Four groups of rats were used ($n=10$), Group 1 served as normal control, Group 2 was orally given sodium selenite ($10 \mu\text{g}/\text{kg}$ body weight) daily for 8 weeks, Group 3 was orally given carbimazole at a dose level of $1.35 \text{ mg}/\text{kg}$ body weight, Group 4 was orally administered carbimazole and sodium selenite daily for 8 weeks. Rats in control and treated groups were sacrificed by cervical decapitation after 8 weeks of treatment, their livers were removed and stained with H&E for histological examinations. Alanine aminotransferase and aspartate aminotransferase were determined in the sera. Malondialdehyde and the antioxidant enzymes, catalase and superoxide dismutase were measured in the liver.

Results: Cytoplasmic vacuolation of the hepatocytes, necrosis, leucocytic infiltrations, blood vessels congestion and fatty degeneration were observed in liver of carbimazole-treated animals. Carbimazole caused marked elevation in serum alanine aminotransferase and aspartate aminotransferase. It also caused an increase in malondialdehyde and depletion of the activity of the antioxidant enzymes, catalase and superoxide dismutase in the liver. Treating animals with carbimazole and selenium led to an improvement in both the histological and biochemical alterations induced by carbimazole. Moreover, selenium reduced the level of malondialdehyde and increased the activity of antioxidant enzymes, superoxide dismutase and catalase.

Conclusions: It is concluded that the ameliorative effect of selenium against the hepatotoxicity of carbimazole is attributed to its antioxidant properties.

KEYWORDS

Carbimazole, Selenium, Liver, Histology, Oxidative stress

1. Introduction

Selenium is a trace element that is essential at small amounts, but can be toxic at larger amount. Humans and animals require selenium for the function of a number of selenium-dependent enzymes, also known as selenoproteins. During selenoproteins synthesis, it is incorporated into a very specific location in the amino acid sequence in order to form a functional protein[1]. At least two types of selenoproteins are necessary for each animal cell, the first form is the family of glutathione-peroxidase and the second form is the family of deiodinases. Glutathione-peroxidases are the most powerful

antioxidant enzymes, which defend the cell against oxidative damage induced by oxidative stress related diseases and disorders such as cardiovascular disease, malignancies, bacterial or viral diseases, muscle dystrophy and arthropathy[2]. Gärtner reported that the plasma selenium levels indicate the amount of circulating selenoproteins and selenoenzymes which are important for modulating the immune system and also for thyroid hormone metabolism[3]. Sodium selenite is commonly used as a direct supplement for the treatment of selenium deficiency. Selenium had antiperoxidative effect and capacity to prevent cancer[4]. Liao *et al.*[5] reported that selenium played a beneficial role for prevention of cisplatin hepatotoxicity

*Corresponding author: Saber Abdel-Rahman Sakr, Zoology Department, Faculty of Science, Menoufia University, Shebin El-Kom, Egypt.
E-mail: sabsak@yahoo.com

Article history:

Received 21 Jul 2014

Received in revised form 25 Jul, 2nd revised form 2 Aug 2014

Accepted 12 Sep 2014

Available online 9 Dec 2014

in mice. Selenium has a protective effect against rat liver and kidney damage induced by mercury chloride and by cadmium[6,7].

Carbimazole is an antithyroid drug that is used for treatment of hyperthyroidism[8]. Frenais *et al.*[9] reported that carbimazole is a common oral treatment for hyperthyroidism in cats. On the other hand, the use of carbimazole was accompanied by deleterious effects on some organs. Ali *et al.*[10] reported that carbimazole produced mild necrosis of renal tubules in rats. Marazuela *et al.*[11] mentioned that carbimazole was capable of inducing acute pancreatitis and cholestatic hepatitis in a 33-year old female. Zaidi *et al.*[12] reported that carbimazole administration even in therapeutic dose during pregnancy and lactation resulted into alteration of the thyroid microstructure of the newborn. Pulmonary haemorrhage and necrotizing glomerulonephritis were associated with carbimazole therapy[13]. Vilchez *et al.*[14] reported that carbimazole therapy caused agranulocytosis, hepatotoxicity with severe cholestatic jaundice effects. The present work investigated the effect of selenium on carbimazole induced hepatotoxicity in Albino rat.

2. Materials and methods

2.1. Animals and treatments

Forty sexually mature male Albino rats (*Ratus norvegicus*) weighing (150±10) g were used. Animals were kept in the laboratory under constant temperature of (24±2) °C throughout the experimental work. They were maintained on a standard rodent diet composed of 20% casein, 15% corn oil, 55% corn starch, 5% salt mixture and 5% vitaminized starch (Egyptian Company of Oils and Soap, Kafr-Elzayat, Egypt). Water was available *ad libitum*. Animals were maintained and experimental procedures were complied with the guide for care and use of laboratory animal. They were divided into four groups ($n=10$). Group 1 animals served as normal controls; Group 2 animals were orally given sodium selenite (10 µg/kg body weight[15], daily for 8 weeks. Na₂SeO₃ was obtained from Laboratory Chemicals Division, British Drug Houses Ltd., England. It was dissolved in distilled water; Group 3 animals were orally given carbimazole which was obtained from Chemical Industries Development, Giza, A.R.E. as tablets supplied under the trade name Neo-Mercazole. It was dissolved in distilled water and orally administered to animals at a dose level of 1.35 mg/kg body weight (equivalent to the therapeutic dose for human)[16], daily for 8 weeks. Group 4 animals of this group were orally administered carbimazole (1.35 mg/kg body weight) and sodium selenite (10 µg/kg body weight) daily for 8 weeks.

2.2. Histological study

Ten animals from both the control and treated groups were sacrificed by cervical decapitation after 8 weeks of treatment. Immediately

after decapitation animals were dissected, livers were removed and fixed in 10% formalin. After fixation, specimens were dehydrated in an ascending series of alcohol, cleared in two changes of xylene and embedded in molten paraffin wax. Sections of five microns thickness were cut using rotary microtome and mounted on clean slides. For histopathological examination, sections were stained with Ehrlich's haematoxylin and counterstained with eosin. Liver sections were graded for the degree of fatty change and inflammation. Steatosis was scored as follows: 1 when less than 25% of the cells contained fat droplets, 2 when 25-50%, 3 when 50-75% and 4 when >75% contained fat droplets. Inflammation was graded 0 to 3, 1 indicated the presence of scattered inflammatory cells, 2 indicated the presence of foci of inflammatory cells and 3 corresponded to diffuse inflammation.

2.3. Biochemical studies

For biochemical assays, blood samples were collected from animals and sera was obtained by centrifugation of the blood samples and stored at -20 °C. Aspartate aminotransferase (AST) and alanine aminotransferase (ALT) were determined colorimetrically according to previous research[17]. In addition, fresh tissue samples of liver were homogenized in 0.1 mol/L phosphate buffer (pH 7.4) using a polytron homogenizer until a uniform suspension was obtained. The homogenate was centrifuged and the clear supernatant was separated. Malondialdehyde (MDA) was measured according to the method of Ohkawa *et al.*[18]. Superoxide dismutase (SOD) activity was determined according to the method of Rest and Spitznagel[19]. Catalase (CAT) activity was determined according to Aebi *et al.*[20].

2.4. Statistical analysis

All results are given as mean±SD and statistical analysis was performed using One way ANOVA to assess significant differences among treatment groups. The criterion for statistical significance was set at $P<0.05$. All statistical analyses were performed using SPSS statistical version 16 software package (SPSS® 4 Inc., USA).

3. Results

3.1. Histological results

Figure 1a shows histological structure of liver of control rat. Microscopic examination of liver of carbimazole-treated rats revealed many histopathological alterations. Liver sections reflected signs of injury as indicated by congestion of intrahepatic veins, central and portal (Figure 1b) and appearance of large mass of leucocytic inflammatory cells (Figure 1c). The hepatic tissue lost its normal arrangement and the hepatic cells became necrotic and showed

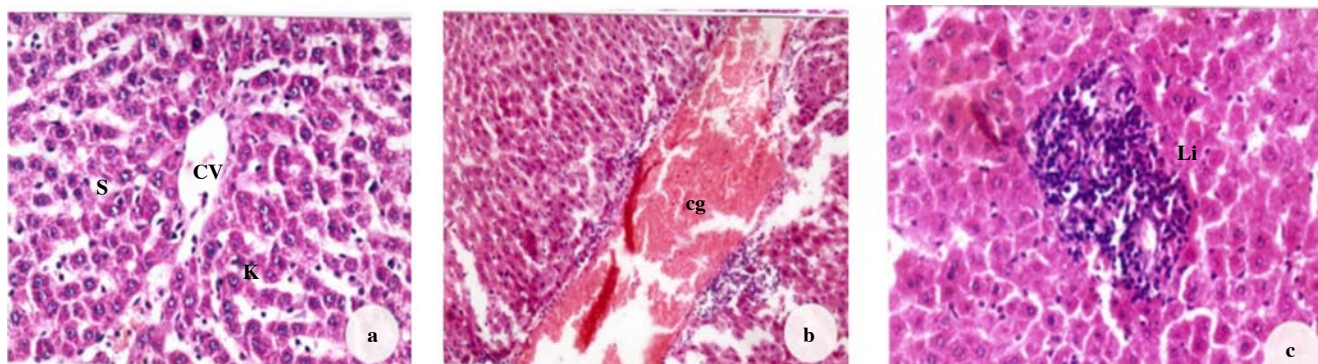


Figure 1. Liver section of a control rat and carbimazole-treated rat.

a: Liver section of a control rat showing central vein (CV), sinusoids (S) and Kupffer cells (K); b: Liver section of carbimazole-treated rat showing congested and enlarged vein (cg); c: Liver section of carbimazole-treated rat showing leucocytic infiltrations (Li) ($\times 400$).

degenerated cytoplasm with pyknotic nuclei (Figure 2a). Moreover, a large number of hepatocytes appeared with vacuolation of the cytoplasm which was so extensive to the extent that only a very limited portion of it was left (Figure 2b). The nuclei of these cells were pyknotic and the cell membranes were disrupted. Infiltrations by fat droplets of different sizes were observed (Figure 2c). Liver sections of animals treated with carbimazole and selenium showed that the liver tissue acquired some improvement compared with carbimazole group. Slight congestion of blood vessels and few leucocytic infiltrations were recorded (Figure 2d). Few cells showed fatty degeneration. Figure 3 showed that there is reduction in inflammation and steatosis grade in the liver of animals treated with carbimazole and selenium in comparison with those treated with carbimazole only.

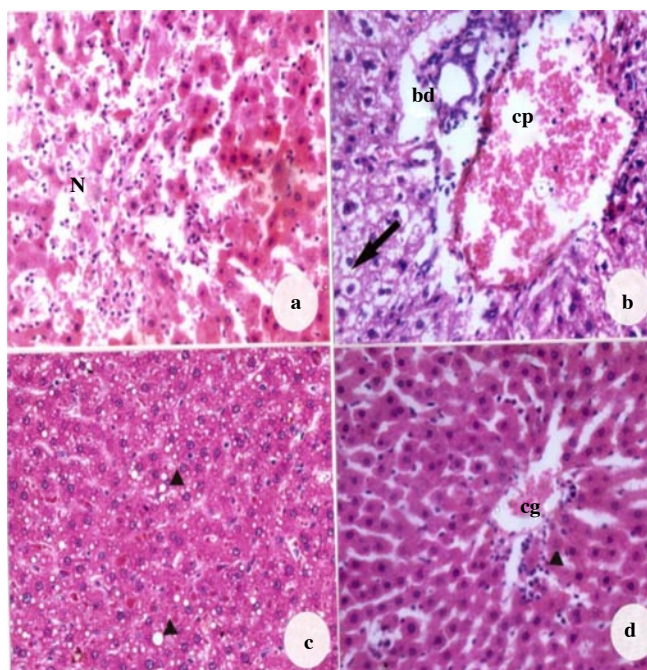


Figure 2. Ameliorative effect of selenium observed in histological study.

a: Liver section of carbimazole-treated rat showing necrosis (N); b: Cytoplasmic vacuolation of the hepatocytes (arrow), congested portal vein (cp) and degenerated bile duct (bd); c: Fat droplets of different sizes (head arrows); d: Specimen obtained from a rat treated with carbimazole and selenium showing a degree of improvement with few leucocytic infiltrations (head arrow) ($\times 400$).

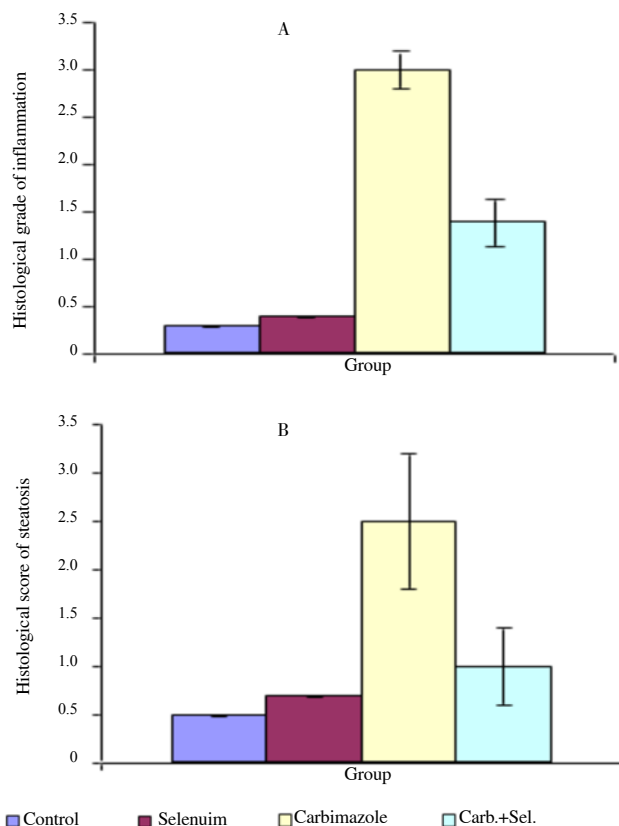


Figure 3. Histological grades of inflammation and steatosis in liver of rats given carbimazole alone and in combination with selenium.

3.2. Biochemical results

3.2.1. Change in ALT and AST

Serum ALT activity in different groups was shown in Figure 4A. There was no statistical difference between the control rats and those receiving selenium alone. Carbimazole-treated animals showed significant increase in serum ALT activities when compared to the control group. Non-significant difference in serum AST activity was recorded in animals treated with selenium when compared with control group (Figure 4B). Treating rats with carbimazole showed significant increase in serum AST activity while a significant decrease in AST activity was observed in animals treated with carbimazole and selenium.

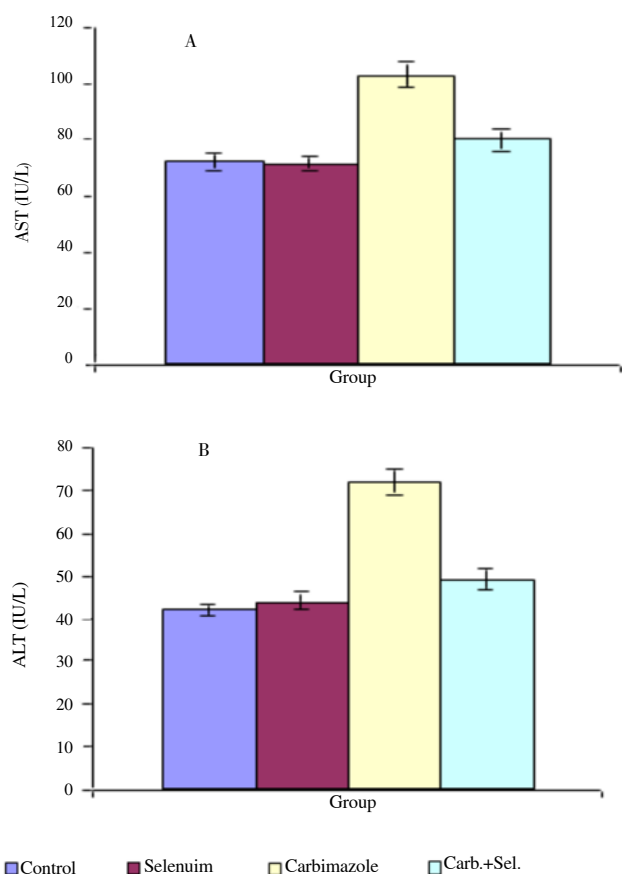


Figure 4. Changes in AST and ALT in different animal groups.

3.2.2. Changes in MDA, SOD and CAT

The effects of different treatments on MDA (index of tissue lipid peroxidation), SOD and CAT in liver of animals examined after 8 weeks are illustrated in Figure 5. A significant increase in MDA level and decrease in the activity of SOD and CAT was recorded in carbimazole-treated animals when compared with the control group. Treating rats with carbimazole and selenium caused a decrease in MDA level and increase of SOD and CAT activities.

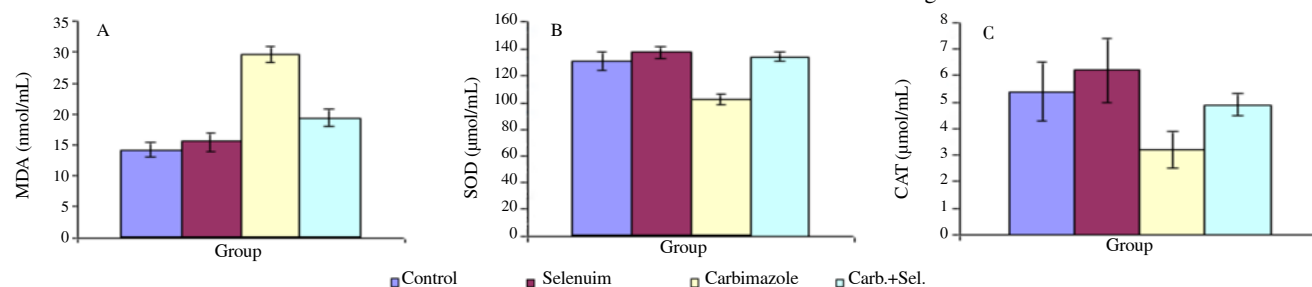


Figure 5. Changes in MDA, SOD and CAT in different animal groups.

enzymes may result from liver damage *e.g.* acute hepatocellular damage or extrahepatic obstruction, or both[25]. In agreement with this result, Ajayi and Akhigbe recorded an increase in transaminases after induction of hypothyroidism by carbimazole in rats[26]. They added that carbimazole caused lysis of hepatocytes.

Treating animals with carbimazole in the present study indicated a significant increase in malondialdehyde and reduction in the

4. Discussion

Carbimazole was found to cause adverse effect on hepatic tissue and its enzymatic activities in Albino rats. Carbimazole led to significant increase in the activity of serum transaminases (AST, ALT). The histopathological results indicated that carbimazole induced many alterations in the liver. These are cytoplasmic vacuolation of the hepatocytes, necrosis, leucocytic infiltrations, blood vessels congestion and fatty degeneration. Similar results were observed by some authors who recorded liver failure after carbimazole treatment. A 63 year old housewife with hyperthyroidism developed a reaction which included fever, pruritus, malaise, and, on one occasion, jaundice for 17 days after taking carbimazole. Challenge with carbimazole was followed within 12 h by abdominal pain, pruritus, and increased serum transaminase levels. Light microscopy of a liver biopsy showed increase of portal zone cellularity over the control and the electron microscopy revealed fine structural changes compatible with drug-related liver injury[21]. Blom *et al.*[22] described a patient with cholestatic hepatitis following the use of carbimazole. The liver biopsy showed intracanalicular cholestasis and some mononuclear cell infiltrate in the portal triades. A woman, after receiving carbimazole for hyperthyroidism for 3 months showed predominantly centrilobular cholestasis[23]. Epeirier *et al.*[24] report the case of a patient who developed jaundice, encephalopathy, marked increase in serum aminotransferase activity and a decrease in prothrombin and proaccelerin levels, after 6 weeks' treatment with carbimazole and propranolol for hyperthyroidism. A 37-year-old woman with severe hyperthyroidism treated with carbimazole developed agranulocytosis and severe mixed hepatotoxicity with severe cholestatic jaundice[14]. Transaminases, AST and ALT increased significantly in sera of rats treated with carbimazole. It was reported that transaminases were considered to be a more sensitive measure in evaluating liver function and damage. The elevations in serum levels of these

activities of the antioxidant enzymes (SOD and CAT). Similarly, Sakr *et al.*[27] reported that carbimazole caused significant decrease in SOD and CAT and an increase in MDA. Vijayakumar and Nalini showed that superoxide dismutase, catalase and glutathione peroxidase were reduced in erythrocytes of rats treated with carbimazole compared with control animals[28]. It was reported that excess levels of reactive oxygen and nitrogen species can attack

biological molecules such as DNA, protein and phospholipids which led to increase of lipid peroxidation and depletion of the antioxidant enzymes (superoxide dismutase, catalase and glutathione peroxidase). In the present work, a high lipid peroxidation with a concomitant decrease in the enzymatic antioxidant status, superoxide dismutase and catalase were recorded. The decrease in antioxidant enzymes activities might be due to excessive consumption secondary to the flux of superoxide radicals or due to further decrease in the activities of these protective enzymes. Therefore, the reduction in the activities of these enzymes may result in a number of deleterious effects due to the accumulation of superoxide radicals and hydrogen peroxide. Thus, it is concluded that carbimazole-induced oxidative stress in rats, which resulted in the hepatic toxicity observed in the present work.

Rats given carbimazole in combination with selenium exhibited a significant improvement in the hepatic alterations induced by carbimazole. Similarly, Fuentealba *et al.*[29] demonstrated that selenium supplementation to Wistar rats resulted in a reduction in the severity of Cu-associated morphologic changes in the liver. Selenium-enriched lactobacillus decreased liver injury and lipid peroxidation induced by CCl₄ administration in mice[30]. Shen *et al.*[31] observed that supplementation of the diet with vitamin E and selenium decreased hepatic fibrosis produced in rats by acute and chronic CCl₄ administration. El-Shenawy and Hassan reported that rats given selenium in combination with the HgCl₂ injection showed a significant decrease in serum ALT and AST levels as compared with HgCl₂ group[6]. Selenium supplementation has a protective effect on hepatic fibrosis induced by CCl₄ in mice. The decreased hepatic fibrosis after chronic CCl₄ administration in mice supplemented with selenium occurred in the setting of decreased inflammation and increased apoptosis[32]. The present results showed that inflammation and steatosis decreased in liver of rats given carbimazole and selenium. In agreement with result, Kim *et al.*[33] reported that selenium have anti-inflammatory properties. Vunta *et al.*[34] recorded that selenium supplementation was found to decrease inflammation in lung tissues induced by bacterial endotoxin lipopolysaccharide in selenium deficient mice.

Treatment with selenium was effective in the prevention of oxidative damage induced by carbimazole which resulted in significantly lower malondialdehyde in the liver. This can be explained by the important role of selenium in preventing lipid peroxidation and in protection of integrity and functioning of tissues and cells. The prevention of lipid peroxidation is essential for all aerobic organisms and so the organism is well equipped with antioxidants that directly or indirectly protect cells against the adverse effects of xenobiotics and toxic radicals[35]. By concomitant treatment of rats both to carbimazole and selenium the activities of SOD and CAT remain at the level of the control values, indicating that selenium eliminates the toxic effects of carbimazole on the activity of these enzymes. Sefi *et al.*[36] showed that exposure of

rats to methimazole promoted oxidative stress with an increase in liver malondialdehyde levels and a decrease in the activities of liver glutathione peroxidase, superoxide dismutase and catalase. They added that coadministration of selenium through diet improved all the biochemical parameters. Yu *et al.*[37] reported that selenium inhibited oxidative stress, apoptosis and cell cycle changes induced by excess fluoride in kidney of rats. Grotto *et al.*[38] reported that in rats chronically exposed to low levels of methylmercury, selenium co-administration showed a significant reduction in methylmercury-induced genotoxicity, reestablished glutathione peroxidase activity and reduced DNA damage. Viezeleiene *et al.*[39] concluded that selenium has a protective effect against aluminium-induced oxidative stress in mouse liver *in vivo*. Treatment of diabetic rats with selenium and vitamin E or their combination blunted the increment in malondialdehyde and reduction in superoxide dismutase and aldehyde oxidase[40]. Treating rats with dimethoate promoted oxidative stress with an increase in malondialdehyde and a decrease in glutathione peroxidase, superoxide dismutase and catalase activities in liver of rats. Co-administration of selenium and/or vitamin E through diet was found to have antioxidant effect[41]. It is concluded from the obtained results that selenium protect rats against hepatotoxicity of carbimazole and this is attributed to its antioxidant activity.

Conflict of interest statement

We declare that we have no conflict of interest.

Acknowledgements

Authors are thankful to Faculty of Science, Menoufia University, Egypt, for providing laboratory facilities and instruments to carry out this work.

Comments

Background

Carbimazole is an antithyroid drug that is used for treatment of hyperthyroidism. However, the use of carbimazole was accompanied by deleterious effects in some organs (hepatotoxicity, necrosis of renal tubules, adverse and pulmonary effects).

Research frontiers

This study evaluated the effect of the antithyroid drug, carbimazole on liver of albino rats and the possible protective effects of selenium.

Related reports

The data presented in this manuscript showing that selenium treatment prevent hepatotoxicity induced by the carbimazole treatment in the Albino rats.

These findings are in agreement with the previous studies by Liao *et al.*, (Pharmacological Research 2008; 57:125-131) which reported that the selenium has a beneficial role for prevention of cisplatin hepatotoxicity in mice.

Innovations and breakthroughs

The antithyroid drug, carbimazole is widely used in the treatment of hyperthyroidism. A growing body of data confirmed several systemic side effects after use of this medication. This study assesses the possible beneficial effect of selenium after liver damage induced by the antithyroid drug, carbimazole treatment into the rats.

Applications

The selenium treatment prevents the histological damage in the liver as well as biochemical abnormalities induced by the antithyroid drug, carbimazole in the Albino rats. These results support development of protective approaches for unwanted side effects resulted from antithyroid drug, carbimazole treatment and might offer a greater chance of successful use of carbimazole with minimum side effects.

Peer review

This is a good study in which the authors examined the use of trace element such as selenium in the liver histological and biochemical damage induced by the antithyroid drug, carbimazole in Albino rats. The result is interesting and suggested that selenium may be successfully used with carbimazole treatment with minimum side effects.

References

- [1] Holben DH, Smith AM. The diverse role of selenium within selenoproteins: a review. *J Am Diet Assoc* 1999; **99**: 836-843.
- [2] Gabryel B, Malecki A. Ebselen attenuates oxidative stress in ischemic astrocytes depleted of glutathione. Comparison with glutathione precursors. *Pharmacol Rep* 2006; **58**: 381-392.
- [3] Gärtner R. Selenium and thyroid hormone axis in critical ill states: an overview of conflicting view points. *J Trace Elem Med Biol* 2009; **23**(2): 71-74.
- [4] Thirunavukkarasu C, Sakthisekaran D. Sodium selenite, dietary micronutrient, prevents the lymphocyte DNA damage induced by N-nitrosodiethylamine and phenobarbital promoted experimental hepatocarcinogenesis. *J Cell Biochem* 2003; **88**(3): 578-588.
- [5] Liao Y, Lu X, Lu C, Li G, Jin Y, Tang H. Selections of agents for prevention of cisplatin-induced hepatotoxicity. *Pharmacol Res* 2008; **57**(2): 125-131.
- [6] El-Shenawy SM, Hassa NS. Comparative evaluation of the protective effect of selenium and garlic against liver and kidney damage induced by mercury chloride in the rats. *Pharmacol Rep* 2008; **60**(2): 199-208.
- [7] Jihen el H, Imed M, Fatima H, Abdelhamid K. Protective effects of selenium (Se) and zinc (Zn) on cadmium (Cd) toxicity in the liver and kidney of the rat: histology and Cd accumulation. *Food Chem Toxicol* 2008; **46**(11): 3522-3527.
- [8] Abbassy AA, Kamel SS, Assaad SN, Eid WE. Ultrasonographic and doppler study of the thyroid gland in Graves' disease before and after treatment with antithyroid drugs. *Endocrinol Pract* 1997; **3**(4): 225-230.
- [9] Frénais R, Burgaud S, Horspool LJ. Pharmacokinetics of controlled-release carbimazole tablets support once daily dosing in cats. *J Vet Pharmacol Ther* 2008; **31**(3): 213-219.
- [10] Ali BH, Bashir AA, Tanira MO. The effect of thyroxine or carbimazole treatment on gentamicin nephrotoxicity in rats. *Hum Exp Toxicol* 1995; **14**(1): 13-17.
- [11] Marazuela M, Sánchez de Paco G, Jiménez I, Carraro R, Fernández-Herrera J, Pajares JM, et al. Acute pancreatitis, hepatic cholestasis and erythema nodosum induced by carbimazole treatment for Graves' disease. *Endocr J* 2002; **49**(3): 315-318.
- [12] Zaidi TM, Khan AA, Hasan BM, Faruq AN. Carbimazole induced thyroid histopathy in Albino rats during development. *J Anat Soc India* 2004; **53**(2): 14-17.
- [13] Calañas-Continento A, Espinosa M, Manzano-García G, Santamaría R, Lopez-Rubio F, Aljama P. Necrotizing glomerulonephritis and pulmonary hemorrhage associated with carbimazole therapy. *Thyroid* 2005; **15**(3): 286-288.
- [14] Vilchez FJ, Torres I, Garcia-Valero A, López-Tinoco C, de Los Santos A, Aguilar-Diosdado M. Concomitant a granulocytosis and hepatotoxicity after treatment with carbimazole. *Ann Pharmacother* 2006; **40**(11): 2059-2063.
- [15] Swathy SS, Panicker S, Indira M. Effect of exogenous selenium on the testicular toxicity induced by ethanol in rats. *Indian J Physiol Pharmacol* 2006; **50**(3): 215-224.
- [16] Paget G E and Barnes J. M. Toxicity tests. In: Laurence DR, Bacharach AL, editors. *Evaluation of drug activities: pharmacometrics*. London and New York: Academic Press; 1964, p. 135-166.
- [17] Reitman S, Frankel S. A colorimetric method for the determination of

- serum glutamic oxalacetic and glutamic pyruvic transaminases. *Am J Clin Pathol* 1957; **28**: 56-63.
- [18] Ohkawa H, Ohishi N, Yagi K. Assay for lipid peroxidase in animal tissue by thiobaubituric acid reaction. *Anal Biochem* 1979; **95**: 351-358.
- [19] Rest RF, Spitznagel JK. Subcellular distribution of superoxide dismutases in human neutrophils. Influence of myeloperoxidase measurement of superoxide dismutase activity. *Biochem J* 1977; **166**(2): 145-153.
- [20] Aebi H, Wyss SR, Scherz B, Skvaril F. Heterogeneity of erythrocyte catalase II. Isolation and characterization of normal and variant erythrocyte catalase and their subunits. *Eur J Biochem* 1974; **48**(1): 137-145.
- [21] Lunzer M, Huang SN, Ginsburg J, Ahmed M, Sherlock S. Jaundice due to carbimazole. *Gut* 1975; **16**: 913-917.
- [22] Blom H, Stolk J, Schreuder HB, von Blomberg-van der Flier M. A case of carbimazole-induced intrahepatic cholestasis. An immune-mediated reaction? *Arch Intern Med* 1985; **145**: 1513-1515.
- [23] Ozenne G, Manchon ND, Doucet J, Hémet J, Schrub JC, Bercoff E. Carbimazole-induced acute cholestatic hepatitis. *J Clin Gastroenterol* 1989; **11**: 95-97.
- [24] Epeirier JM, Pageaux GP, Coste V, Perrigault PF, Banc P, Larrey D, et al. Fulminant hepatitis after carbimazole and propranolol administration. *Eur Gastroenterol Hepatol* 1996; **8**: 287-288.
- [25] Sherlock S. *Disease of the liver and biliary system*. 8th ed. Oxford: Blackwell Scientific Publication; 1981.
- [26] Ajayi AF, Akhigbe RE. Implication of altered thyroid state on liver function. *Thyroid Res Pract* 2012; **9**:84-87.
- [27] Sakr SA, Mahran HA, Nofal AE. Effect of selenium on carbimazole-induced testicular damage and oxidative stress in Albino rats. *J Trace Elem Med Biol* 2011; **25**: 59-66.
- [28] Vijayakumar RS, Nalini N. Efficacy of piperine, an alkaloidal constituent from piper nigrum on erythrocyte antioxidant status in high fat diet and antithyroid drug induced hyperlipidemic rats. *Cell Biochem Funct* 2006; **24**(6):491-498.
- [29] Fuentealba IC, Horney B, Daley J, Tasony-Ferraro A. The role of selenium in copper-induced damage in copper loaded rats livers. In: Nève J, Chappuis P, Lamand M, editors. *Therapeutic uses of trace elements*. New York: Springer; 1966, p. 259-264.
- [30] Chen L, Pan DD, Zhou J, Jiang YZ. Protective effect of selenium enriched lactobacillus on CCl₄ induced liver injury in mice and its possible mechanisms. *World J Gastroenterol* 2005; **11**: 5795-5800.
- [31] Shen XH, Cheng WF, Li XH, Sun JQ, Li F, Ma L, et al. Effects of dietary supplementation with vitamin E and selenium on rat hepatic stellate cell apoptosis. *World J Gastroenterol* 2005; **11**: 4957-4961.
- [32] Ding M, Potter JJ, Liu X, Torbenson MS, Mezey E. Selenium supplementation decreases hepatic fibrosis in mice after chronic carbon tetrachloride administration. *Biol Trace Elem Res* 2010; **133**(1): 83-97.
- [33] Kim SH, Johnson VJ, Shin TY, Sharma RP. Selenium attenuates lipopolysaccharide-induced oxidative stress responses through modulation of p38 MAPK and NF- κ B signaling pathways. *Exp Biol Med* 2004; **229**: 203-213.
- [34] Vunta H, Belda BJ, Arner RJ, Channa Reddy C, Vanden Heuvel JP, Sandeep Prabhu K. Selenium attenuates proinflammatory gene expression in macrophages. *Mol Nutr Food Res* 2008; **52**: 1316-1323.
- [35] Sies H. Oxidative stress, introductory remark. In: Sies H, editor. *Oxidative stress*. London: Academic Press; 1985.
- [36] Sefi M, Amara IB, Troudi A, Soudani N, Hakim A, Zeghal KM, et al. Effect of selenium on methimazole-induced liver damage and oxidative stress in adult rats and their offspring. *Toxicol Ind Health* 2012; **30**(7): 653-669.
- [37] Yu RA, Xia T, Wang AG, Chen XM. Effects of selenium and zinc on renal oxidative stress and apoptosis induced by fluoride in rats. *Biomed Environ Sci* 2006; **19**(6): 439-444.
- [38] Grotto D, Barcelos GR, Valentini J, Antunes LM, Angeli JP, Garcia SC, et al. Low levels of methylmercury induce DNA damage in rats: protective effects of selenium. *Arch Toxicol* 2009; **83**(3): 249-254.
- [39] Viezelienė D, Jansen E, Rodovicius H, Kasauskas A, Ivanov L. Protective effect of selenium on aluminium-induced oxidative stress in mouse liver *in vivo*. *Environ Toxicol Pharmacol* 2001; **31**(2): 302-306.
- [40] Ghaffari T, Nouri M, Saei AA, Rashidi MR. Aldehyde and xanthine oxidase activities in tissues of streptozotocin-induced diabetic rats: effects of vitamin E and selenium supplementation. *Biol Trace Elem Res* 2011; **147**(1-3): 217-225.
- [41] Ben Amara I, Soudani N, Troudi A, Bouaziz H, Boudawara T, Zeghal N. Antioxidant effect of vitamin E and selenium on hepatotoxicity induced by dimethoate in female adult rats. *Ecotoxicol Environ Saf* 2011; **74**(4): 811-819.