

## Acoustic pharyngometry: An objective assessment tool for determining pharyngeal airway

Kumar S<sup>1</sup>, Jayan B<sup>2</sup>, Bansal AK<sup>3</sup>

### ABSTRACT

<sup>1</sup>PG Resident, Division of Orthodontics and Dentofacial Orthopaedics, Department of Dental Surgery, Armed Forces Medical College, Pune-40

<sup>2</sup>Consultant Division of Orthodontics and Dentofacial Orthopaedics, ADC R&R, Delhi Cantt, New Delhi.

<sup>3</sup>PG Resident, Division of Orthodontics and Dentofacial Orthopaedics, Department of Dental Surgery, Armed Forces Medical College, Pune-40

The interest in studying the upper airway has always been there in orthodontics. Acoustic Pharyngometry is a relatively new technique in this field which measures the upper airway precisely. The technique is based on acoustic reflection technology. Sound waves are projected down the airway and reflected back out in such a way that the Pharyngometry software can analyze and quantify changes in the airway cross sectional area. It is an easy and quick technique that measures patient's pharyngeal airway size and patency from the oropharyngeal junction to the glottis. The technique is useful in screening of patients having higher risk for sleep disordered breathing, establishing candidacy for mandibular advancement device and accurate bite recording/ titration of the appliance and also for planning surgical intervention. The aim of this article is to sensitize orthodontic professionals about this technique and to discuss the basic procedural methodology along with its clinical usefulness.

Received: 16-02-2015  
Accepted: 28-03-2015

**Keywords:** Acoustic Pharyngometry, Acoustic Reflection, Obstructive sleep apnea

### INTRODUCTION

- Certain craniofacial features are known to have increased predilection for airway collapsibility leading to sleep disordered breathing like snoring and obstructive sleep apnea (OSA). Some of these risk factors are<sup>1</sup>: Narrow upper airway, especially at the level of the soft palate and the base of the tongue
- Relative mandibular retrognathism and Increased hyoid distance
- Decrease in posterior airway space
- Increased tongue volume, and
- Enlargement of the palatine or adenoidal tissues

It is important to correctly identify these cases so that right kind of orthodontic treatment can be instituted to address the decreased airway dimensions. Lateral cephalometry is routinely used diagnostic tool in orthodontics for diagnosis and treatment planning. Though it helps in analyzing the airway dimensions but fails to estimate it in three dimensional proportions.<sup>2</sup> It can measure the airway in anteroposterior dimension but not in the transverse. Gold standard for upper airway imaging is MRI; however it is not cost effective.

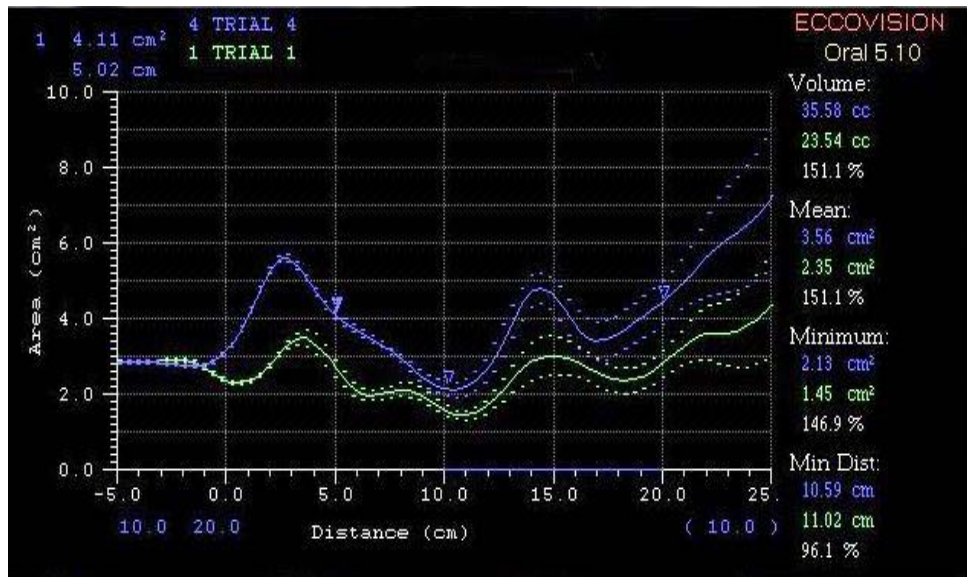Recently acoustic Pharyngometry has been introduced in clinical practice for orthodontists and otorhinolaryngologists for evaluation of

oropharyngeal & hypopharyngeal airway. It is a non-invasive procedure based on acoustic reflection technology, similar to the ship's sonar.<sup>3</sup> Sound waves are projected down the airway and reflected back out in such a way that the Pharyngometer software can analyze and quantify changes in the airway cross sectional area. It allows users to quickly and easily measure patient's pharyngeal airway size and patency from the oropharyngeal junction to the glottis. In this case series three such cases were evaluated for pharyngeal airway size and volume with different treatment implications.

**CASE 1:** A 52 year old male, a suspected case of OSA was referred to orthodontic clinic from department of pulmonary medicine for evaluation of pharyngeal airway. The patient gave a positive history of loud snoring, sense of choking and restless sleep. He also reported excessive day time sleepiness and fatigue. Acoustic Pharyngometry was done and the results showed a mean pharyngeal airway area of 2.35 cm<sup>2</sup> and a minimum of 1.45 cm<sup>2</sup> which meant that the airway was reduced. Test was repeated with a mandibular advancement of 6 mm and 4 mm vertical opening which showed significant airway improvement on pharyngogram (Fig 1). The patient was advised for polysomnography and the results showed AHI index of 56.7 (severe OSA) which confirmed our findings.

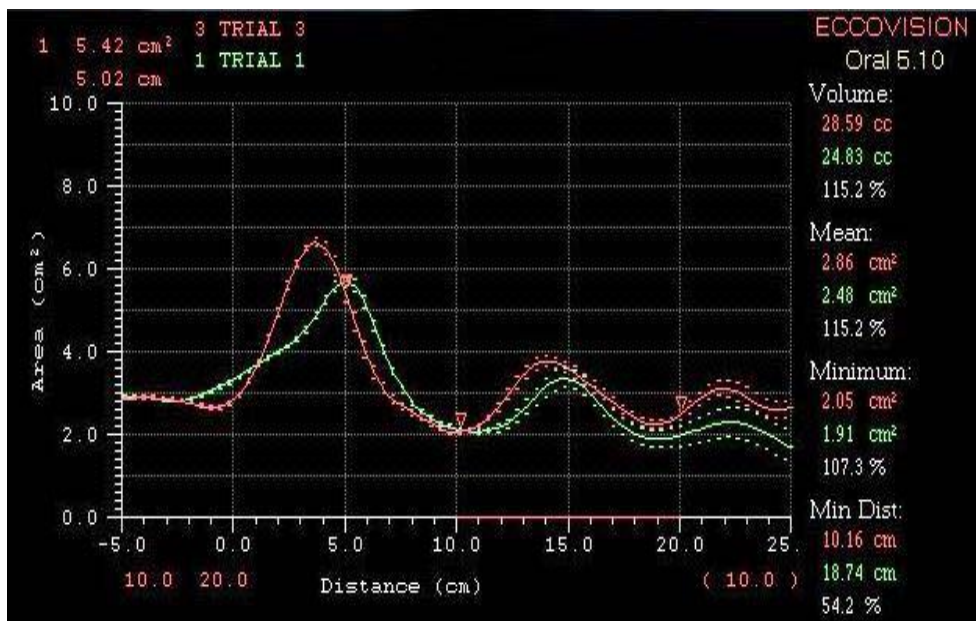
### Address for Correspondence:

Dr. Maj Sunil Kumar, PG Resident, Division of Orthodontics and Dentofacial Orthopaedics, Department of Dental Surgery, Armed Forces Medical College, Wanourie, Pune-40  
Email: dr.sunil.bhatti@gmail.com



**Fig 1:** Case 1 Pharyngogram- trial 1 showing initial airway and trial 4 after advancement

**CASE 2:** A 58 year old male patient was referred from a general dentist as a suspected case of OSA and for considering him for oral appliance therapy. Pharyngometry was carried out and the mean airway was 2.48 cm<sup>2</sup> and minimum airway was 1.91 cm<sup>2</sup>. To know the candidacy for oral appliance therapy the test was repeated with various combinations of mandibular advancement and vertical opening. The best airway increase was seen after 6 mm of mandibular advancement but this increase in pharyngeal airway was very small (Fig 2). The patient was further advised polysomnography and was referred to otorhinolaryngologist for feasibility of surgical management/ continuous positive airway pressure therapy.



**Fig 2:** Case 2 Pharyngogram- trial 1 initial airway value and trial 3 after advancement

**CASE 3:** A 15 year old female was diagnosed as a case of angles class II div 1 malocclusion with class II skeletal jaw relationship. Her airway was evaluated with acoustic pharyngometry which showed a mean area of 1.92 cm<sup>2</sup> and a minimum airway of 1.28 cm<sup>2</sup>. The case was then treated with fixed functional appliance therapy and her airway was again measured. The airway showed an improvement in the mean airway area to 2.46 cm<sup>2</sup> and the minimum airway was 1.79 cm<sup>2</sup> on this second measurement (Fig. 3).

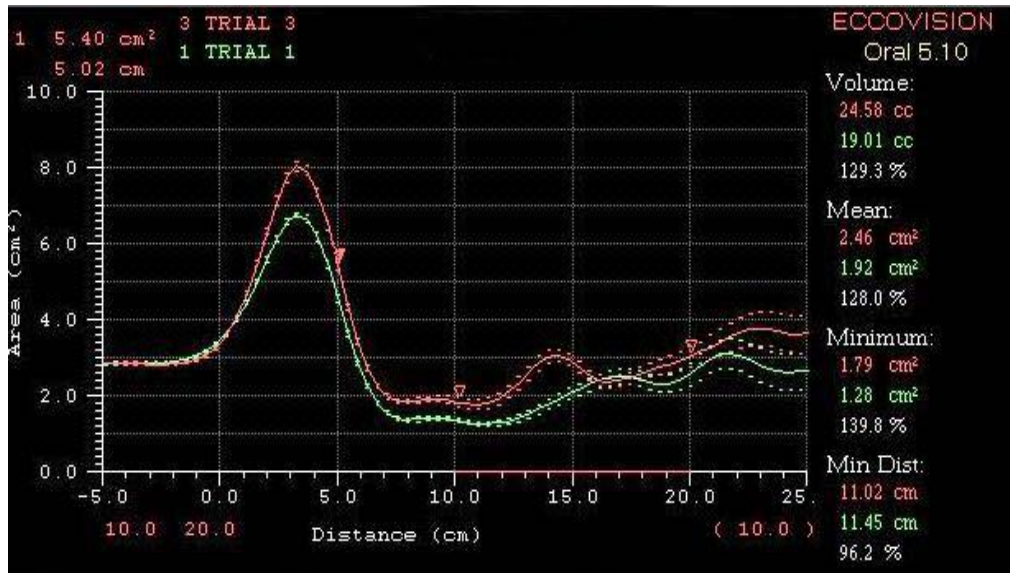


Fig 3: Case 3 Pharyngogram

**DISCUSSION**

The “Eccovision” acoustic pharyngometer from sleep group solutions is being used widely for evaluating pharyngeal airway (Fig. 4). It utilizes AR technology to assess cross-sectional area and volume from the oral cavity through the hypopharynx by calculating changes in acoustic impedance that occur with cross-sectional changes along the airway. It has a wave tube connected to a processor and the other end of this wave tube terminates in a narrow neck to which a mouthpiece is attached. The mouthpiece is made of rubber and is placed against the teeth with the lips covering the flange to form an acoustic seal.<sup>4-6</sup>

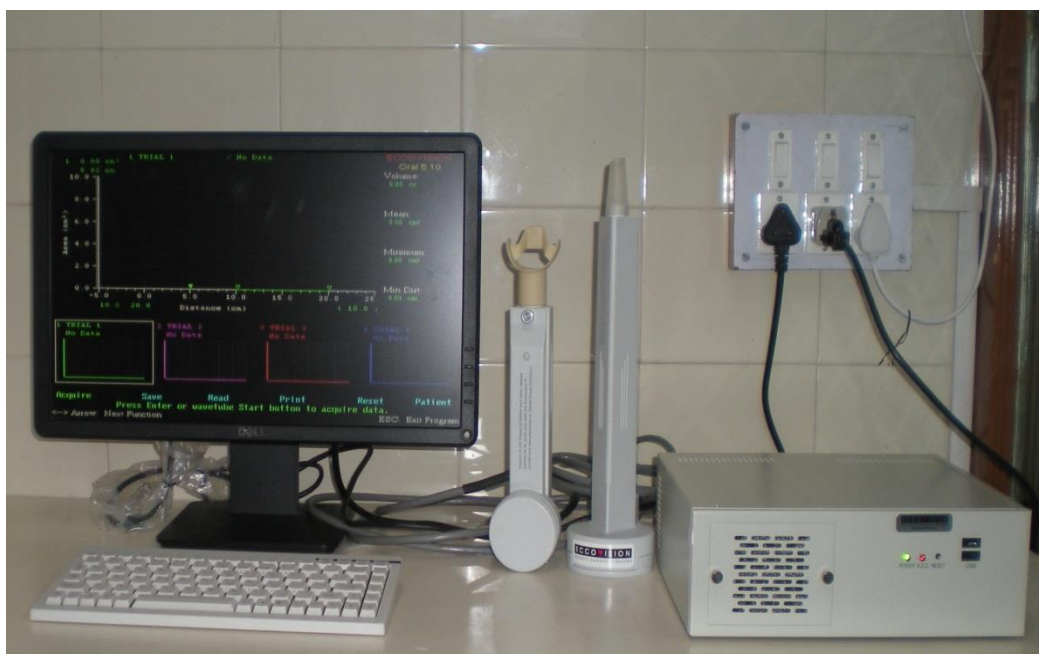
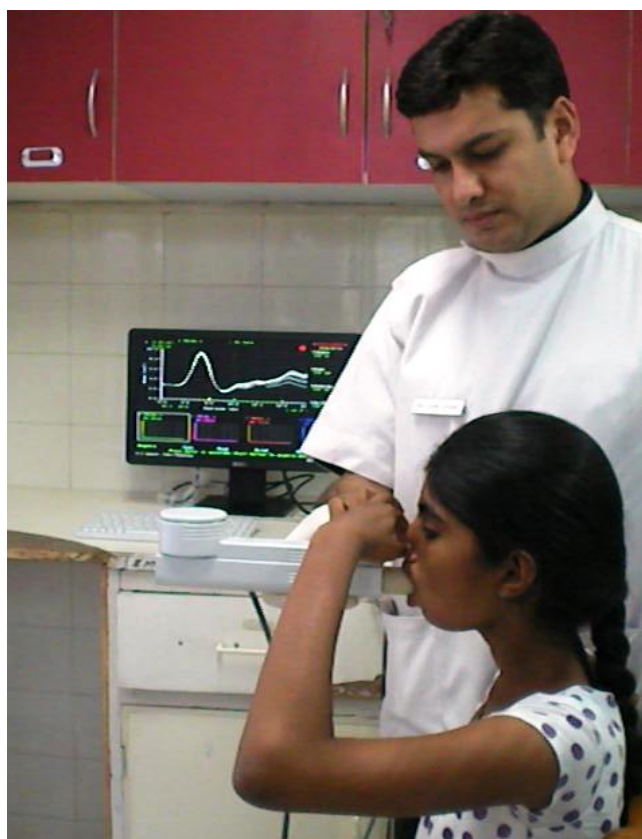
Fig 4: Acoustic Pharyngometer

### Pharyngometry Procedure

Patient should be relaxed, comfortable and seated on straight back chair looking forward at a fixed point during the exam (Fig 5). The wave tube, which should always be horizontal, is placed close to the mouth. The patient closes his mouth over this tube during the examination, avoiding sound wave loss. The patient is guided not to move, to maintain head still, and to slowly breathe through their mouth. Nasal breathing should be avoided as the opening of the velopharyngeal space during nasal breathing increases the calculated volume. The nostrils should be compressed externally throughout the exam. It is important that flexion of the neck or elevation of the shoulders should be avoided as it may compress the pharynx and decrease its cross-section resulting in reduced measurements.<sup>5</sup> The common source of erroneous readings could be:

- Change of head position in relation to cervical spine (extension or flexion).
- Shoulder position.
- Uncontrolled tongue position.
- Malpositioning of wave tube.
- Patient awareness of his or her breath or an excited patient with a change in respiratory rate and volume.



**Fig 5:** Pharyngometry procedure

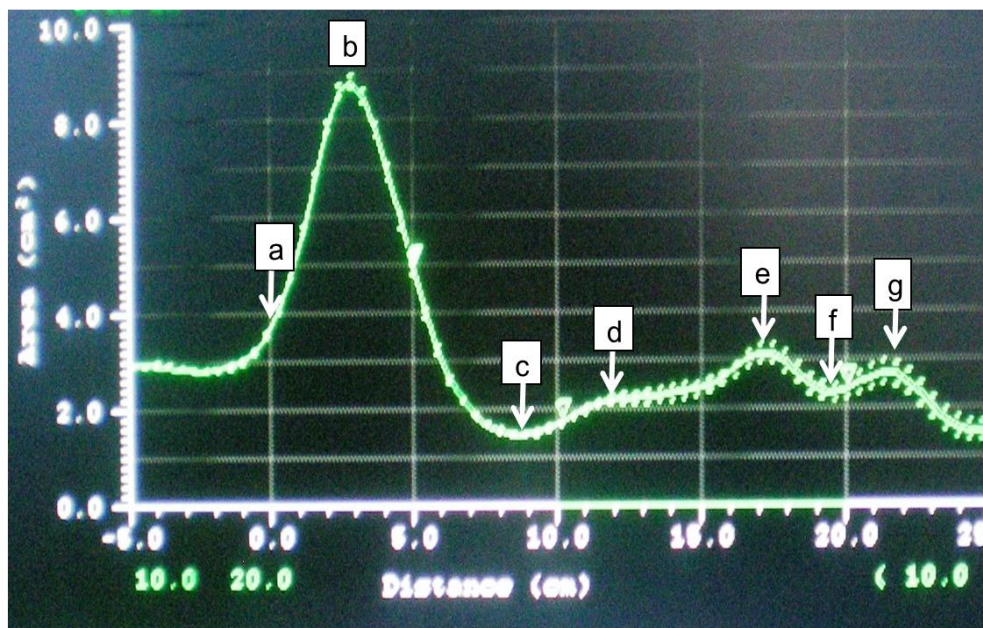
### Pharyngogram

The shape of the pharyngogram is directly related to the anatomy of the oral and pharyngeal cavities. Airway is described on the normal pharyngogram, where the x-axis is the airway distance (calculated in cm) and the y-axis is the

airway area (calculated in  $\text{cm}^2$ ). Pharyngogram is divided into three regions (Fig. 6):

- 1) "Oral region" from the incisors to the soft palate
- 2) "Pharyngeal region" from the soft palate to the hypopharynx
- 3) "Laryngeal region"





**Fig 6:** Pharyngogram

The distance zero on the graph is the end piece of the tube placed over the incisors. The first wave originates from this point and indicates the beginning of the mouth (a); peak of this wave (b) indicates the maximum area of the oral cavity. The first wave amplitude identifies the volume of the oral cavity. Patients with macroglossia have a significant wave I amplitude reduction. This is an important sign indicative of enlarged tongue as currently there are few objective and specific signs of increased tongue size. The curve then shows a deflection reaching a minimal area which is mostly at a distance between 5 to 8 cm (c), and represents the anterior margin of the soft palate (oropharyngeal junction). The curve on the graph begins to move up reaching its peak (e) at hypopharynx. This region of wave segment between (c) and (e) shows a small secondary peak (d) and represents the posterior oropharynx, which is usually not visible. The distal deepest curvature on the pharyngogram (f) is the glottic region which is followed by an area (g) that shows subglottic expansion.<sup>3, 4</sup>

#### Acoustic Reflection

A number of investigators have studied the pharyngeal airway in the past using acoustic reflection (AR). The technique for evaluating the airway with AR was first demonstrated by Jackson et al over 37 years ago in animal model.<sup>7</sup> Fredberg and coworkers compared airway measurements obtained from radiographic projections of the trachea with those obtained by AR in six subjects.<sup>8</sup> In another study Brooks, et al. also found an accurate and reproducible result in measuring airway dimensions using the same technique.<sup>9</sup> In a subsequent study, D'Urzo and coworkers demonstrated excellent agreement between glottic area measurements of pharyngeal

cross sectional area measured acoustically as compared to those obtained through computed tomography.<sup>10</sup> Marshall et al. acoustically evaluated the pharyngeal dimensions of 10 normal human subjects using room air rather than helium/oxygen gas and compared these measurements to those obtained through MRI.<sup>11</sup> Kamal investigated 350 normal adult subjects using the latest version of the pharyngometer, and found a mean pharyngeal area of 3.194 cm<sup>2</sup> in males and a mean of 2.814 cm<sup>2</sup> in females. The coefficient of variation for intra-subject pharyngeal volume was 5 to 7%.<sup>4</sup> In another study, Kamal examined 50 snorers using AR and concluded significant correlation between apnea index and pharyngeal area which further adds to the scope of pharyngometry in assessing the pharyngeal airway in patients with obstructive sleep apnea.<sup>5</sup>

A recent study using AR evaluated the correlation between the severity of obstructive sleep apnea and primary hypertension and concluded that severity of obstructive sleep apnea (OSA) can be determined objectively by this technique and blood pressure in the OSA patients might gradually decrease after uvulopalatopharyngoplasty.<sup>12</sup>

#### Clinical Usefulness.<sup>13</sup>

##### 1. Patient screening

AR can establish the pharyngeal characteristics of individuals in the general population and may be in high-risk groups which help in identifying those who require further evaluation through polysomnography, ultimately reducing the burden on current medical facilities.

##### 2. Positional Therapy Evaluation

AR has been used to evaluate airway response to positional therapy. AR is used to assess the effect

of head extension through cervical repositioning on airway caliber.

### 3. Surgery Candidacy

The preoperative investigation of upper airway is necessary in order to establish candidacy for uvulopalatopharyngoplasty. Although site of airway closure is impossible to demonstrate in the awake patient using AR, it precisely describes the cross-sectional area and abnormal upper airway narrowing caudal to the velopharynx. AR has also been used to evaluate upper airway function in awake OSA patients both before and after weight loss.

4. Candidacy for mandibular advancement device (MAD) for OSA and non-apneic snoring  
AR has been used to evaluate hypopharyngeal changes produced by mandibular advancement in the awake patient. Following advancement, no change in volume is 95% predictive of failure and an increase in volume by 60% is predictive of a successful treatment outcome.

5. Accurate bite recording factoring in precise vertical opening and sagittal advancement

With the help of bite jigs which give an accurate vertical opening and advancement, it is possible to access the outcome of oral appliance therapy and correct construction of bite.

### 6. Titration of mandibular advancement device

As per current protocol, the mandibular advancement should be done until subjective relief of symptoms and then verified objectively through standard polysomnography. Inaccurate mandibular advancement may lead to increased patient discomfort and ultimately lower compliance to therapy. Acoustic evaluation of the airway's response to mandibular manipulation with the MAD in place helps in its titration, thus results in the most ideal management of the airway. This would help to minimize the possibility of inadvertent advancement past the ideal point of effectiveness into a position that would unnecessarily strain the masticatory and cervical muscles and/or reduce the effectiveness of the MAD.

### Advantages.<sup>13</sup>

1. AR accurately evaluates the airway in three dimensions which, allows for correct recording of caliber and volume over a given length of airway.
2. It is non-invasive, accurate, reproducible, quick and Inexpensive.
3. It is possible to take readings at 0.2 second intervals which allows for dynamic assessment of the airway.

### Limitations.<sup>13</sup>

It cannot distinguish airway narrowing caused by impingement of surrounding tissues from reduced neuromuscular compensation.

1 Acoustic pharyngometry provides no information regarding nasopharyngeal

dimensions, which may be a relevant region for collapse in many patients with OSA.

- 2 Does not provide high resolution anatomic representation of the airway or soft-tissue structures.
- 3 The conventional AR technique cannot be used during sleep.

### CONCLUSION

The acoustic reflection technique is being used to assess pharyngeal cross-sectional area for the past few decades. The technique has been previously applied to study the pharynx, glottis, and trachea in humans in vivo. The technique has been validated against computed tomography scans and in experimental models. Moreover the test is quick and gives an accurate size and volume of airway. More reliable and repeatable results can be achieved with this technique, if a standard operating protocol is utilized and maintained.

### REFERENCES:

1. Gavish A, Vardimon AD, Rachima H, Bloom M, Gazit E. Cephalometric and polysomnographic analyses of functional magnetic system therapy in patients with obstructive sleep apnea. *Am J Orthod Dentofacial Orthop.* 2001;120:169-77.
2. Yucel A, Unlu M, Haktanir A, Acar M, Fidan F. Evaluation of the upper airway cross-sectional area changes in different degrees of severity of obstructive sleep apnea syndrome: cephalometric and dynamic CT study. *Am J Neuroradiol.* 2005;26:2624-29.
3. Gelardi M, Giudice AMD, Cariti F et al. Acoustic pharyngometry: clinical and instrumental correlations in sleep disorders. *Rev Bras Otorrinolaringol.* 2007;73:257-65.
4. Kamal I. The normal standard curve for acoustic pharyngometry. *Otolaryngol Head Neck Surg.* 2001;124:323-30.
5. Kamal I. Acoustic pharyngometry patterns of snoring and obstructive sleep apnea patients. *Otolaryngol Head Neck Surg.* 2004;130:58-66.
6. Kamal I. Test-retest validity of acoustic pharyngometry measurements. *Otolaryngol Head Neck Surg.* 2004;130:223-8.
7. Jackson AC, Butler JP, Millet EJ, Hopin FG, Dawson SV. Airway geometry by analysis of acoustic pulse response measurements. *J Appl Physiol.* 1977;43:523-36.
8. Fredberg JJ, Wohl ME, Glass GM, Dorkin HL. Airway area by acoustic reflections measured at the mouth. *J Appl Physiol.* 1980;48:749-58.
9. Brooks LJ, Castile RG, Glass GM, Griscom NT, Wohl ME, and Fredberg JJ. Reproducibility and accuracy of airway area by acoustic reflection. *J Appl Physiol.* 1984;57:777-87.
10. D'Urzo AD, Lawson V, Vassal K, Rebuck AS, Slutsky AS, Hoffstein V. Airway area by acoustic response measurements and computerized tomography. *Am Rev Respir Dis.* 1987; 135:392-95.

11. Marshall I, Marin NJ, Martin S, Jan MA, Rimmington JE, Best JJ, et al. Acoustic reflectometry for airway measurements in man: implementation and validation. *Physiol Meas.* 1993;14:157-69.
12. Badee S, Kazem N, Khalid H. Determination of the correlation between the severity of obstructive sleep apnea and primary hypertension by using acoustic pharyngometry. *ZUMJ.* 2014; 20(1):112-18.
13. Viviano JS. Acoustic Reflection: review and clinical applications for sleep-disordered breathing. *Sleep And Breathing.* 2002; 6: 129-49.

**How to cite this Article:** Kumar S, Jayan B, Bansal AK. Acoustic pharyngometry: An objective assessment tool for determining pharyngeal airway. *J Dent Specialities,* 2015;3(1):102-108

**Source of Support:** NIL

**Conflict of Interest:** None Declared