

## Case Report


# Anomalous origin of superior laryngeal artery from external carotid artery - A case report

Billakanti Prakash Babu<sup>1\*</sup>, Huban Thomas<sup>2</sup>

<sup>1</sup>Associate Professor, <sup>2</sup>Senior Lecturer,

Department of Anatomy, Kasturba Medical College, Manipal University, Manipal, Karnataka, India

\*Corresponding author email: [billakantibabu@yahoo.co.in](mailto:billakantibabu@yahoo.co.in)

	International Archives of Integrated Medicine, Vol. 2, Issue 9, September, 2015.	
	Copy right © 2015, IAIM, All Rights Reserved.	
	Available online at <a href="http://iaimjournal.com/">http://iaimjournal.com/</a>	
	ISSN: 2394-0026 (P)	ISSN: 2394-0034 (O)
	Received on: 26-08-2015	Accepted on: 02-09-2015
	Source of support: Nil	Conflict of interest: None declared.

## Abstract

During routine dissection in Anatomy Department, KMC Manipal, anomalous origin of superior laryngeal artery arising from external carotid artery was observed on the right side in an adult male cadaver. Superior laryngeal artery normally is a branch of superior thyroid artery. It supplies laryngeal muscles, mucosa and glands. The origin of lingual and facial arteries from external carotid artery was normal. The courses of nerves in the carotid triangle are also normal. No variations were observed in the left carotid arterial system. Variations in the origin of the superior laryngeal artery are very rare. It may arise from lingual, facial, ascending pharyngeal, external carotid artery or even from the common carotid artery. There are reports of rare variation of the common trunk of origin of superior laryngeal and inferior thyroid artery from the external carotid artery at the same level as origin of common linguofacial trunk. Though embryogenesis of this variation is not clear, but may be important for reconstruction surgery of the larynx, laryngeal transplantation and it will also be useful to the surgeons in minimizing the post-operative complications in a bloodless surgery. Clinicians must be aware of these variations in the super selective intra arterial chemotherapy for laryngeal and hypo laryngeal cancers.

## Key words

Superior laryngeal artery, Right side, External carotid artery.

## Introduction

Knowledge of anatomical variations of the common carotid (CCA) and external carotid arteries (ECA) and their branches are of great

importance, especially during radiological examinations and surgery of the neck region [1]. ECA normally is a branch of CCA begins at the level of upper border of thyroid cartilage at the

level between C3 and C4 vertebra. The superior laryngeal artery (SLA) normally is a branch of superior thyroid artery. It runs horizontally in the carotid triangle along with the internal laryngeal nerve, and pierces the thyrohyoid membrane and supplies laryngopharynx, laryngeal muscles, piriform fossa, quadrangular membrane, glands and the mucosa of larynx till the level of vestibular fold. It terminates by anastomosing with artery of the opposite side and with inferior laryngeal artery [2, 3]. Variations in the SLA are very rare. It may arise from lingual, facial, ascending pharyngeal, external carotid artery or even from common carotid arteries [4].

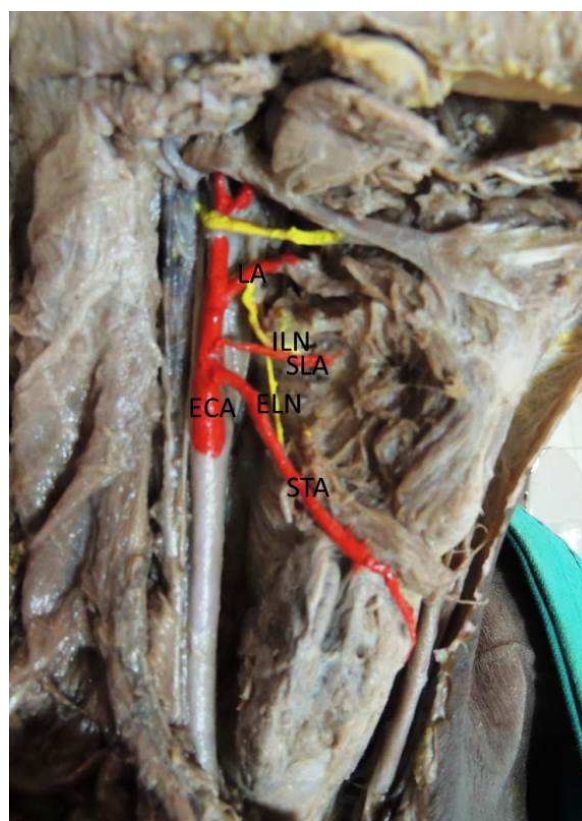
In the present case we report a variant origin of the right SLA from the ECA. The CCA did not give off any other branches in the neck except its terminal branches, external and internal carotid arteries. A rare variant origin of understanding the surgical anatomy of the SLA is necessary for successful radical neck dissection and to minimize postoperative complications in a bloodless surgery. Also, knowledge of variations in the origins of these arteries is important for surgical procedures in the neck, such as emergency cricothyroidotomy, radical neck dissection, catheterization, reconstruction of aneurysms and carotid endarterectomy [5].

### Case report

During routine dissection of a formalin-fixed adult male cadaver utilized for educational purposes in the Department of Anatomy, Kasturba Medical College, Manipal, variations were observed unilaterally in the anterior triangle of the neck on right side. ECA were normal in origin. The arterial system was carefully dissected and photographed (**Figure - 1**). The nerves of the carotid triangle were normal in course. The superior laryngeal artery (SLA) which normally is a branch of STA was arising from the ECA. The SLA was accompanied by the internal laryngeal nerve and both these structures pierced the thyrohyoid membrane. The origin and course of lingual, ascending pharyngeal, occipital, posterior auricular and

terminal branches of external carotid artery were normal. The external laryngeal nerve was running posteriorly and was supplying cricothyoid muscle. Similarly, there were no variations among these arteries on the left side of the neck.

**Figure - 1:** Photograph showing variant origin of the superior laryngeal artery from external carotid in an adult male cadaver on the right side. ECA: external carotid artery; STA: superior thyroid artery; SLA: superior laryngeal artery; LA: lingual artery; ILN: internal laryngeal nerve; ELN: External laryngeal nerve.



### Discussion

Superior laryngeal artery usually arises from superior thyroid artery but sometimes it takes direct origin from external carotid artery in 32% of cases [5]. Macalister 1833 reported 'a rare variation of common special trunk of SLA and inferior thyroid artery taking origin from ECA at the same level as origin of common linguofacial trunk. Satheesha Nayak 2008 has reported a rare case of double superior laryngeal arteries, one

from superior thyroid and other directly from external carotid artery [6]. Roberto Bastos Silva 2005 has reported the presence of an anomalous foramen in thyroid cartilage lamina through which SLA was passing [7]. Nayak SR, et al. [8] have studied the have studied the origin of superior laryngeal artery and classified the pattern in to four types. Type: I: Subtype 1a: Superior laryngeal artery originates from superior thyroid artery (superior laryngeal artery with a transverse course), Subtype 1b: The superior laryngeal artery originates from the superior thyroid artery (Superior laryngeal artery initially with an ascending in course). Type II. The superior laryngeal artery originates from lingual artery. Type III: The superior laryngeal artery originates directly from the external carotid artery. Type IV: The superior laryngeal artery originates from the linguo-facial trunk. Lang, et al. [9] found that the superior laryngeal artery was a branch from the external carotid artery only in 6.8% of cases of 44 hemi sections of neck. Rusu, et al. [10], 2007 found the superior laryngeal artery was taking origin from external carotid artery in 32% cases in 100 hemi sections of neck. Terayama, et al. [11], gives the incidence of origin of superior laryngeal artery from external carotid artery in 6.8% cases in 68 hemi sections of the neck. Harsha B. R., et al. [12] have reported the bilateral origin of superior laryngeal artery from the external carotid artery. Rao Mohandas, et al. [13] have found the superior laryngeal artery arising from the external carotid artery. Dr. Padmalatha K, et al. [14] have found the superior laryngeal artery taking origin from the main trunk of external carotid artery between superior thyroid artery and common linguofacial trunk. The bulk of the blood to the human larynx is delivered via the superior laryngeal artery. The variation in the superior laryngeal artery origin and morphology is important during the partial laryngectomy and reconstruction surgery of the larynx, laryngeal transplantation.

The knowledge of variations in the branching of external carotid artery and their identification is very important for the procedures like carotid

catheterization, reconstruction of aneurysms, carotid endoplasty, carotid endarterectomies and diagnostic carotid angiograms. Surgeons should aware of these abnormal branching of external carotid artery while performing radical neck dissections, thyroidectomy, laryngectomy, glossectomy and ligation of external carotid artery during uncontrollable epistaxis. We the anatomists feel proud to add the additional information to the existing knowledge in the text books which helps surgeons mainly.

### **Development**

Embryologically, SLA coincides with the development of the ECA in the early stages of intrauterine life. ECA proximal part sprouts head wards as a new vessel from third aortic arch (Susan Stranding [2] 2005) and distal branches are developed from: Primitive hyoid artery from 2<sup>nd</sup> aortic arch and Primitive stapedial artery from 1<sup>st</sup> aortic arch. The failure of proper synchronization of signals involved in annexation and regression will lead to the variations of branching pattern of the ECA [15].

### **Conclusion**

The knowledge of surgical anatomy of superior laryngeal artery and its relationship with other structures are important in the microsurgery of anterior neck and larynx. The knowledge of variable origin of SLA will help the surgeons in successful radical neck dissection and will also assist them in minimizing postoperative complication in a bloodless surgery. The detailed anatomy of SLA can also help in the treatment of partial laryngectomy, reconstructive surgery of larynx and also laryngeal transplantation. Finally as SLA is the dominant artery to laryngeal and hypolaryngeal region. The knowledge regarding SLA variation can also help the clinicians in super selective intra arterial chemotherapy for laryngeal and hypo laryngeal cancers in which chemotherapeutic drugs administered through the feeding artery to tumor site directly achieve a greater therapeutic effect and reduces systemic side effects.

## References

1. Gluncic V, Petanjek Z, Marusic A, Gluncic I. High bifurcation of common carotid artery, anomalous origin of ascending pharyngeal artery and anomalous branching pattern of external carotid artery. *Surg Radiol Anat.*, 2001; 23: 123-5.
2. Susan Standring. *Gray's anatomy: anatomical basis of clinical practice* 40<sup>th</sup> edition, Churchill Livingstone Elsevier; 2008, p. 444-447.
3. Michael Gleeson. *Scott-Brown's Otolaryngology Basic Sciences*. 6<sup>th</sup> edition. Volume 1. Butterworth – Heinemann Int. Edinburgh: London, 1997, p. 12-14.
4. Ronald A Bergman. *Compendium of Human anatomic variations*; Urban & Schwarzenberg; Baltimore, 1988, p. 65.
5. Anu VR, Pai MM, Rajalakshmi R, Latha VP, Rajanigandha V, D'Costa S. Clinically-relevant variations of the carotid arterial system. *Singapore Med J*, 2007; 48: 566-9.
6. Satheesha NB, Soumya KV. Neurovascular variations in the carotid triangle. *Int J Anat Variations*, 2008; 1: 17-8.
7. Roberto Bastos Silva. A unilateral anomaly of the superior laryngeal artery passing through the thyroid cartilage lamina. *Braz.J Morphol. Sci*, 2005; 22(I): 41-42.
8. Soubhagya R. Nayak, Ashwin Krishnamurthy, Latha V. Prabhu, Bhagath Kumar Potu, Ishwar B. Bagoji, Jiji PJ and Ganesh Kumar Chettiar. Variable Origin of the Superior Laryngeal Artery and Its Clinical Significance. *Al Ame en J Med Sci*, 2011; 4(1): 69-74.
9. Lang J, Nachbaur S, Fischer K, Vogel E. The superior laryngeal nerve and the superior laryngeal artery. *Acta Anat (Basel)*, 1987; 130: 309–318.
10. Rusu MC, Nimigean V, Banu MA, Cergan R, Niculescu V. The morphology and topography of the superior laryngeal artery. *Surg Radiol Anat*, 2007; 29: 653-60.
11. Terayama N, Sanada J, Matsui O, Kobayashi S, Kawashima H, Yamashiro M, et al. Feeding artery of laryngeal and hypopharyngeal cancers: role of superior thyroid artery in superselective intrarterial chemotherapy. *Cardiovas Intervent Radiol.*, 2006; 29: 536-43.
12. Harsha. B. R, Dakshayani. K.R A Bilateral Anomalous Origin of Superior Laryngeal Artery from External Carotid Artery. *Anatomica Karnataka*, 2012; 6(3): 94-97.
13. Rao Mohandas K.G., Rao Asutosh S. Unusual Origin of the Arteries in the Carotid Triangle of the Neck: A Case Report and Literature Review, *The Open Anatomy Journal*, 2009; 1: 24-27.
14. Padmalatha K., Prakash S., Balachandra N., Mamatha Y., B.R. Rarnesh. Multiple variations in the branching pattern of external carotid artery. Case report. *Anatomica Karnataka*, 50-5.
15. Altman F. Anomalies of the internal carotid artery and its branches; Their embryological and Comparative anatomical significance. Report of a new case of persistent stapedia artery in man. *Laryngoscope*, 1947; 57: 131.