


Original Research Article

Radiographic analysis of thyroid lesions using USG and CT scan

Anup Kurele^{1*}, Aniruddh Patel², P J Zala³

¹2nd year Resident, ²MD – Radio diagnosis, ³Professor and Head
Radiology Department, SBKS Medical Institute & Research Centre, Sumandeep Vidyapeeth,
Vadodara, Gujarat, India

*Corresponding author email: dranupkurele@gmail.com

	International Archives of Integrated Medicine, Vol. 2, Issue 7, July, 2015. Copy right © 2015, IAIM, All Rights Reserved. Available online at http://iaimjournal.com/	
	ISSN: 2394-0026 (P)	ISSN: 2394-0034 (O)
	Received on: 11-06-2015	Accepted on: 07-07-2015
	Source of support: Nil	Conflict of interest: None declared.

Abstract

Background: To establish diagnosis of thyroid lesions using USG as the modality of choice, sonographically characterize those lesions as regards to their nature (benign v/s malignant), to define the spatial extent of these lesions and their relationship to the surrounding structures using USG and CT scan and to guide FNAC of these lesions whenever indicated and establish their pathological correlation.

Aim: To estimate the role of USG and CT in evaluation of thyroid lesions.

Material and methods: The present study was a prospective and observational (non interventional) type of study. This study aimed at evaluating patients came to the Radiology Department of Dhiraj General Hospital, by using USG and CT scan. This study comprised of 97 patients, sonographic evaluation was carried out in all 97 patients while CT scan was used in evaluation of 22 patients. Sonography with color doppler examination was carried out by PHILIPS HD9 AND GE LOGIC P5 and using 7.5 MHZ transducers. CT Scanning was done by using Siemens 16 slice CT Scanner.

Results: Largest group of patients were in 31-40 years with sex ratio of M: F = 1:4.7. The most common clinical feature that patient complained of was asymptomatic lump in the neck (55%), which correlates with the most common pathology which was Goiter. The largest group comprised of non toxic goitre followed by thyroid neoplasms. All patients of grave's disease had diffusely hypoechoic thyroid gland with prominent thyroid septae and capsule, the gland was enlarged in 4 cases and of normal size in one patient. Colour Doppler study showed all patients exhibited increased vascularity referred to as thyroid inferno pattern at colour flow imaging.

Conclusion: High resolution USG is recommended as the primary imaging modality in the evaluation of thyroid diseases. It has a high sensitivity and specificity in the diagnosis of thyroid diseases. CT scan plays a role in evaluation of retrotracheal and retrosternal goiters, large thyroid masses and staging of thyroid malignancies.

Key words

Benign thyroid lesions, Malignant thyroid lesions, High resolution USG, FNAC thyroid lesions.

Introduction

Thyroid lesions are the most common abnormality in the endocrine system. Thyroid cancer accounts for only 0.4% of all cancer deaths and for about 5-6 deaths per 1 million population. Thyroid gland can be imaged with multiple modalities including radionuclide studies, high resolution sonography (USG), thin section computed tomography (CT) and magnetic resonance imaging (MRI) [1, 2]. The importance of imaging is to differentiate the carcinoma of thyroid gland from much more frequent benign adenomas and multi-nodular goiters. The differential diagnosis of thyroid nodules is now accomplished by fine needle aspiration cytology. High-resolution ultrasound (US) is the most sensitive imaging test of the thyroid gland. The role of thyroid US may be resumed into 3 main issues [3, 4, 5].

- To detect thyroid and cervical masses, including relapse in the thyroid bed and cervical adenopathy after thyroidectomy.
- To differentiate between possible benign and probably malignant masses, based on their sonographic appearance.
- To guide the performance of FNA biopsy and percutaneous treatment [6].

Computed tomography (CT) is inferior to ultrasound in the differential diagnosis of thyroid nodules. The purpose of performing CT examination is preoperative evaluation of tumours too large to be assessed by USG and to determine the presence of extra-capsular or mediastinal invasion. MRI is non invasive and useful modality for assessment of thyroid pathologies but it is less specific than USG in differentiating benign from malignant tumours and to establish cystic, calcified areas within it [7, 8, 9].

Radionuclide studies have proved unsatisfactory in assessing the nature of hypofunctioning thyroid and nodular thyroid disease.

The aim of this study was to analyze the role of high resolution USG in evaluation of thyroid diseases, and to evaluate those thyroid tumours by CT scan, too large to be evaluated by USG, to know the extra thyroid spread of tumor to adjacent structures such as the larynx, trachea and vessels within the carotid sheath and provide evidence of regional or distant metastases.

Material and methods

The study was carried out in the Department of Radiodiagnosis, S.B.K.S. Medical Institute and Research Centre, Waghodia, Vadodara.

Study design

Type of the study: An observational, descriptive hospital based study.

Sample size: 97 patients.

Inclusion criteria

- Only those patients who were willing to participate in study were included.
- Patients referred to the Radiology Department for USG and/or CT scan thorax investigations, and found to have thyroid lesion, were included in this study.
- Already diagnosed cases of such thyroid disease which needed follow up radiological investigations and were referred to Radiology Department were included in study.

Exclusion criteria

Patients presented to Radiology Department having thyroid lesion in past and were cured completely were excluded from the study.

Equipments used

- Sonography with colour doppler examination was carried out by Phillips HD7 and GE Logic P5 and using 7.5 MHZ transducers.

- CT Scanning was done using Siemens 16 slice CT Scanner

Pathologic correlation was obtained in all cases with radiologically detected thyroid nodules. In diffuse thyroid conditions diagnosis was made on the basis of either serum biochemistry or pathologic correlation.

Results

The present study was observational type of study. A total of 97 patients evaluated for thyroid diseases in the Department of Radiology, SBKS MI & RC, Vadodara.

Largest group of patients were in 31-40 years age group as per **Table – 1** and **Figure - 1**. The overall sex ratio was M: F = 1:4.7. Female preponderance was noted in all age group except in 61-70 years age group where there was equal number of male and female patients as per **Table – 2** and **Figure - 2**.

Table - 1: Age distribution of patients with thyroid diseases detected by radiologic investigations.

Age range (in years)	Total	%
0-10	4	4.1
11-20	7	7.2
21-30	16	16.6
31-40	28	29
41-50	24	25
51-60	8	8.3
61-70	6	8.3
>71	4	4.1

Table - 2: Sex specific distribution.

	Frequency	Percentage
Female	80	82.0
Male	17	18.0
Total	50	100.0

The most common clinical feature that patient complained of was asymptomatic lump in the neck (55%), which correlates with the most

common pathology which was Goiter. There were 2 % asymptomatic patients in whom thyroid disease was detected accidentally as per **Table – 3** and **Figure - 3**. The largest group comprised of non toxic goitre followed by thyroid neoplasms as per **Table – 4** and **Figure - 4**. 42.5 % of patients diagnosed as STN clinically were found to have Multi-nodular thyroid disease at high resolution Sonography as per **Table - 5**.

Figure - 1: Age distribution.

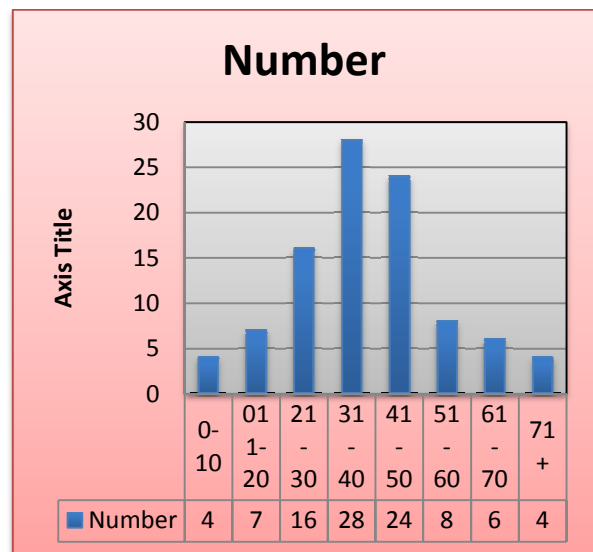
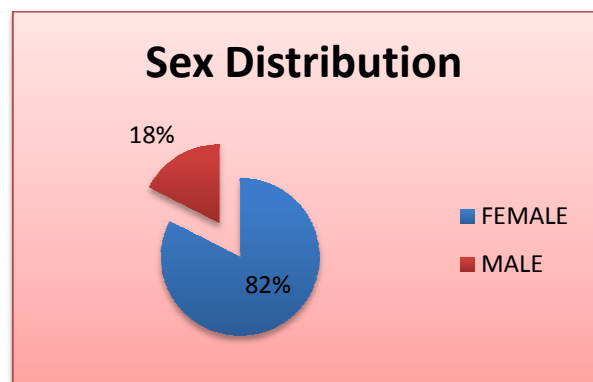


Figure - 2: Sex distribution.



Maximum number of patients was proved to have multi nodular type goiter followed by solitary nodular goiter. Simple diffuse goiter was seen only on 10.5 % cases as per **Table – 6** and **Figure – 5**. Majority of the patients showed mixed consistency, followed closely by solid consistency as per **Table – 7** and **Figure – 6**. As

mentioned above most of the nodules of colloid goiter were isoechoic with cystic degeneration being present in 70% cases. A thin well defined complete halo was seen in 69.5% cases as per **Table - 8**. Only one patient with STN had intra nodular flow pattern on color doppler study. 78.3% STN showed peripheral vascularity as per **Table - 9** and **Figure - 7**.

Table - 3: Clinical features in various thyroid disorders.

Clinical features	Number of cases	%
Asymptomatic	02	2
Lump in the neck	57	55
Dysphagia, Dysphonia or Stridor	07	7
Sudden increase in size	08	8
Local pain and tenderness	05	5
Symptoms of thyrotoxicosis	15	14
Symptoms of hypothyroidism	10	9

Table - 4: Incidence of various thyroid diseases by pathologic examination.

Pathology	M	F	M+F	%
Non toxic goitre	08	39	47	48.5
Toxic nodular goitre	1	9	10	10.4
Grave's disease	01	04	05	5.1
Hashimoto's thyroiditis	02	08	10	10.3
Thyroglossal cyst	00	01	01	1
Ectopic thyroid	00	01	01	1
Thyroid adenoma	01	07	08	8.2
Thyroid neoplasm	04	11	15	15.5
Total	17	79	96	100

Again most of the nodules of colloid goiter were isoechoic with cystic degeneration being present in 60% cases. A thin well defined complete halo was seen in 75% cases. Calcification was

observed in 32% cases in which 25% had coarse and 7% had rim calcification as per **Table - 10**. Majority of the cases of MNG showed inter nodular vascularity with mild to medium velocity as per **Table - 11** and **Figure - 8**.

Figure - 3: Clinical features.

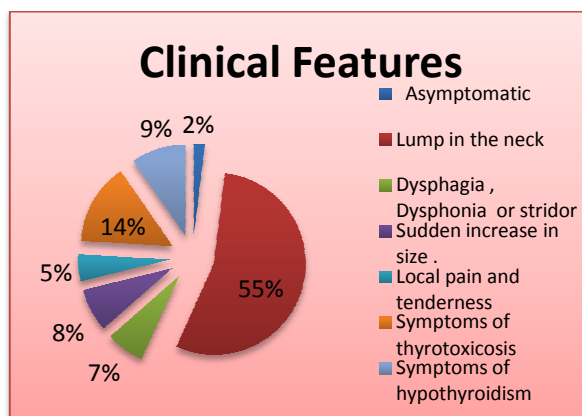


Figure - 4: Incidence of various pathologies.

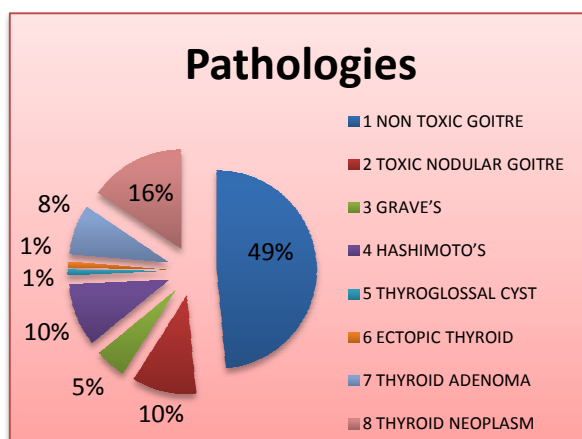


Table - 5: Clinical versus high resolution sonography in detection of thyroid nodularity.

Nodularity		No. of cases
Clinically	STN	40
	Sonographically	STN 23 (57.5 %)
	MNG	17 (42.5%)

All six patients with non nodular diffuse thyroid involvement had heterogeneous parenchymal echotexture composed of iso echoic areas in 5 cases and hyperechoic in 1 and areas of cystic

degeneration in 4 cases as per **Table - 12**. Coarse calcification was observed in one case.

Table - 6: Type of involvement of thyroid parenchyma in toxic and non toxic goiter.

USG abnormality	No. of cases	%
Diffuse	06	10.5
Nodular	51	89.5
• STN	23	45.1
• MNG	28	54.9
Total	57	100

Figure - 5: Type of involvement.

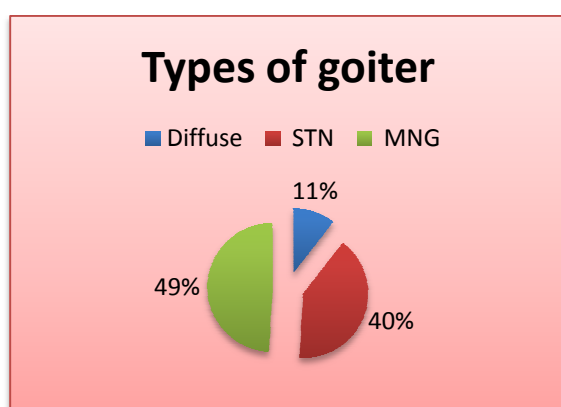


Table - 7: Consistency of nodular goiter lesions as seen at sonography.

USG consistency	No. of cases	%
Solid	18	35.2
Mixed	22	43.1
Predominantly cystic	07	13.7
Entirely Cystic	04	7.8
Total	51	100

All patients had diffusely hypoechoic thyroid gland with prominent thyroid septae and capsule, the gland was enlarged in 4 cases and of normal size in one patient. Colour Doppler study showed all patients exhibited increased vascularity referred to as thyroid inferno pattern at colour flow imaging. In addition high velocity flow was noted during systole as per **Table - 13**. Sonographic appearances of thyroid in patients

of Hashimoto's thyroiditis were as per **Table - 14**.

Figure - 6: Consistency of goiter nodules.

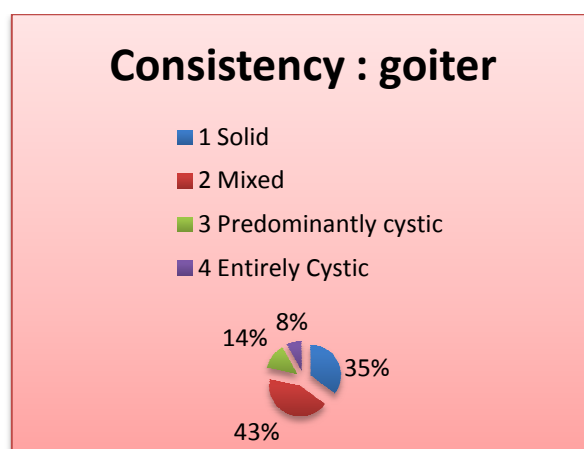


Table - 8: USG features of hyperplastic goiter presenting as STN.

USG features	Cases	%
Consistency		
• Solid	07	30.4
• Mixed	09	39.1
• Predominantly cystic	04	17.3
• Entirely cystic	03	13.0
Echo pattern		
• Isoechoic	15	65.2
• Hyperechoic	01	04.3
• Hypoechoic	01	04.3
• Heteroechoic	04	17.3
• Anechoic	02	08.7
Calcification		
• Coarse	5	21.7
• Micro-calcification	0	---
• Rim Calcification	0	---
Halo		
• Thin, complete, well defined.	16	69.5
• Incomplete/ irregular/ thick	-	-
• Absent	07	30.4
Margins		
• Well defined	23	100
• Ill defined	-	-

Table - 9: Color flow features of colloid goiter presenting as STN.

Colour flow imaging	No. of cases	%
Halo vessels only	18	78.3
Avascular	04	17.3
Intra nodular flow	01	4.4

Table - 10: Sonographic findings of multi-nodular goiter.

USG features	Cases	%
Consistency		
• Solid	11	39.3
• Mixed	13	46.4
• Predominantly cystic	03	10.7
• Entirely cystic	01	03.5
Echo pattern		
• Isoechoic	15	53.5
• Hyperechoic	01	03.5
• Hypoechoic	01	03.5
• Heteroechoic	04	14.2
• Anechoic	02	07.1
Calcification		
• Coarse	7	25
• Micro-calcification	0	-
• Rim Calcification	2	7.1
Halo		
• Thin, complete, well defined.	21	75
• Incomplete/ irregular/ thick	01	3.5
• Absent	06	21.4
Margins		
• Well defined	28	100
• Ill defined	-	-

Table - 11: Color flow imaging in multi-nodular goiter.

Color flow imaging	Cases	%
Inter nodular flow	22	78.5
Avascular	00	0
Intra nodular flow	06	21.5

Figure - 7: Color flow features of colloid goiter presenting as STN.

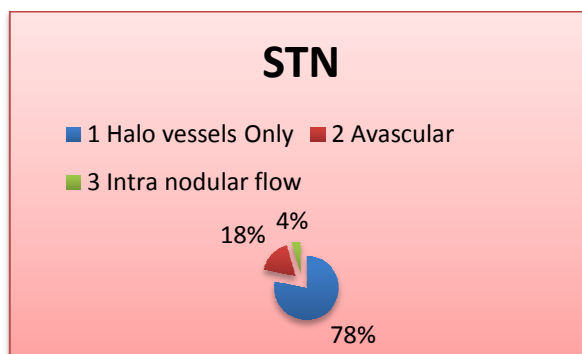


Figure - 8: Color flow imaging in MNG.

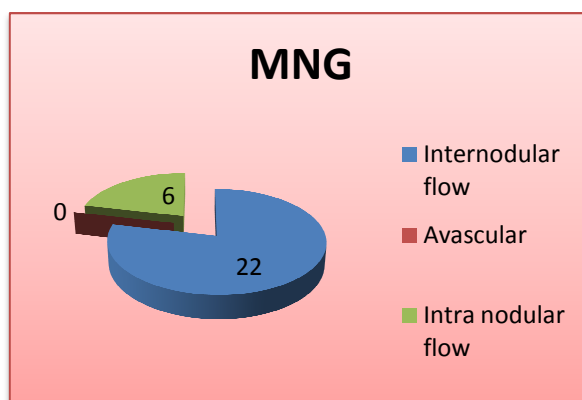


Table - 12: Sonographic appearances of thyroid in patients with simple diffuse goiter.

USG features	Cases	%
Gland size		
• Increased	06	100
• Normal	00	-
• Reduced	00	-
Echopattern		
• Hypoechoic	00	-
• Hyperechoic	01	16.7
• Isoechoic	05	83.3
Cystic degeneration	04	33.3
Calcification	01	16.7
Vascularity		
• Increased	00	-
• Normal	06	100
• Reduced	00	-

Table - 13: Sonographic appearances of thyroid in patients of grave's disease.

USG features	Cases	%
Gland size		
• Increased	04	80
• Normal	01	20
• Reduced	00	---
Echopattern		
• Hypoechoic	05	100
• Hyperechoic	00	---
• Isoechoic	00	---
Cystic degeneration	01	20
Nodularity.	00	---
Vascularity		
• Increased	05	100
• Normal	00	---
• Reduced	00	---

Table - 14: Sonographic appearances of thyroid in patients of Hashimoto's thyroiditis.

USG features	Cases	%
Gland size		
• Increased	10	100
• Normal	00	---
• Reduced	00	---
Echopattern		
• Hypoechoic	10	100
• Hyperechoic	00	---
• Isoechoic	00	---
Cystic degeneration	00	---
Nodularity	04	40
Vascularity		
• Increased	00	00
• Normal	08	80
• Reduced	02	20
Cervical Lymphadenopathy	3	30

Discussion

High resolution sonography is now increasingly being used to evaluate thyroid diseases. It demonstrates thyroid abnormalities with remarkable clarity due to its superficial location

in the neck. It has been used to distinguish normal from abnormal thyroid and to classify the abnormalities as focal or diffuse. Sonography has also been used to characterize the morphology of the lesion and suggest a pathologic diagnosis [10, 11, 12]. The role of high resolution sonography has expanded to assess the local extent of the lesions and guide FNAC wherever indicated. In the present study, 97 patients with clinically suspected thyroid diseases were evaluated by high Resolution USG and/ or CT scan. Pathologic correlation was obtained in all cases to evaluate the diagnostic accuracy of USG [13, 14].

Age and sex distribution

The age range of the patients in the study was 8 years to 78 years. Largest numbers of patients were in the 31-40 years age group. The female preponderance was noted in patients and the overall sex ratio was M: F = 1: 4.7. In present study, there was higher incidence of all thyroid diseases in females. In metastatic lesions the sex distribution was equal and a solitary case of lymphoma was found in a male patient. One study in 1985 had also observed similar female preponderance in both benign and malignant thyroid nodular lesions [15].

Hyperplastic goitre

The commonest pathology encountered in the study was hyperplastic goiter (58.9%). Of them, the majority were nontoxic 48.5%, while 10.4% accounted for toxic nodular goitre. A variable incidence of thyroid pathologies has been reported in literature. One study in 1992 reported hyperplasia of thyroid as the commonest thyroid pathology [16]. One study in 1982 reported follicular adenoma as the commonest thyroid pathology in their study group. Of the 57 cases of hyperplastic goiter, 10.5% patients showed diffuse involvement while rest 89.5% patients had nodular hyperplasia [17].

Variable consistency was noted in later group, the majority of the patients had mixed lesions i.e. both solid and cystic. Variable echo pattern was noted with majority of the lesions being

isoechoic while hypoechoic pattern was noted in least number of cases. All six patients with diffuse thyroid involvement showed heteroechoic parenchymal echotexture. Similar patterns of consistency and echo pattern were observed by various studies [18, 19, 20].

Calcification was noted in 27.4% cases with nodular goiter of which coarse calcification were noted in 12 and rim type in 2 cases. Microcalcification was not noted in any case of hyperplastic goiter. A thin well defined and complete halo was seen in 69.5% of patients presenting as sonographic STN and 75% of multi nodular goiter MNG. About 24.9% cases with MNG had absent of irregular thickened peripheral halo.

Lymphadenopathy and local invasion were not noted in any patient with hyperplastic goitre. Similar gray scale findings have been reported by various authors [21, 22, 23, 24, 25].

Color doppler scan showed peripheral vascularity in 78% cases of STN and 79% of MNG nodules. 18% cases were avascular while 13.7% showed intra-nodular flow in the dominant nodule. Similar colour Doppler findings have been reported in literature [26, 27, 28, 29].

CT scan was done in cases which showed retro sternal extension of the thyroid mass with well defined and clear planes around it. It had inhomogeneous low density in NCCT while marked inhomogeneous enhancement was noted in post contrast study.

Hence CT scan plays an essential role for evaluation of larger goitre which could not be evaluated completely on USG either because of its size or for its retro sterna extension. Similar role of CT scanning was documented in previous studies.

Grave's disease (Diffuse toxic goiter)

All patients of grave's disease included in the study showed solid and diffusely hypoechoic thyroid parenchyma. Thyroid was bulky in 4 out

of 5 cases with prominent thyroid septae and capsule, one patient had no parenchymal changes with no prominence of septae or capsule which was concurrent other studies [30, 31]. These findings were consistent with other similar studies [32, 33].

Color doppler revealed increase flow in all cases, which is referred to as thyroid inferno pattern. Such appearance was not seen in any other thyroid diseases. Findings were concurrent with other studies [34, 35].

Hashimotos's thyroiditis

There were 10 cases of autoimmune thyroiditis in the study all had solid, hypoechoic parenchymal echopattern. There was evidence of nodularity in four patients and it was not possible to distinguish them sonographically from multi nodular colloid goiter (MNG). Three patients had reactive neck lymphadenopathy. Two patients had typical diffusely heterogeneous echotexture with multiple small hypoechoic areas interspersed throughout the thyroid parenchyma. Calcification was not seen in any of the cases. Similar gray scale findings have been reported by various authors [36, 37, 38]. Color doppler was done in 10 patients. It revealed diffuse parenchymal flow of low to medium velocity in all the patients. Similar colour Doppler findings have been documented by various authors [38, 39].

Thyroid neoplasms

A total of 23 patients comprised of this subgroup. Benign lesion adenoma was noted in 8 patients while 15 patients had malignant thyroid neoplasm.

Papillary carcinoma

It was the commonest primary thyroid malignancy encountered in this study comprising of 53% cases. The majority of the lesions had solid consistency. One patient had exclusively cystic consistency; various authors have documented the manifestations of papillary carcinoma in the form predominantly cystic lesion. Heteroechogenicity was noted in most

lesions with predominant hypoechoic echo pattern. Hyperechoic echo pattern which has been documented in literature [38]. Multi nodularity was seen in 2 cases of papillary neoplasms. Thick, irregular or incomplete halo was noted in 6 cases while a complete well defined halo was noted in 1 patient. Coarse calcification was not noted in any patient but micro calcification less than 1mm was observed in 2 cases and rim calcification was seen in one case. In 71.5% cases margins of the lesions were irregular or ill defined and in 28.5% cases they were well defined. Color flow imaging showed predominantly intra lesional flow in 6 cases while in 1 patient we observed predominant perilesional flow. Extra thyroid involvement was noted in the form of lymphadenopathy in all cases while muscle infiltration, tracheal extension and retrosternal extension were noted in one case each. CT scan was able to delineate the exact extent of these locally invasive and huge tumors which emphasizes the limitation on High resolution Sonography in evaluating large tumours and signifies the role of CT scanning in evaluating large thyroid masses and also staging of thyroid malignancies.

Follicular carcinoma

There were three cases of follicular carcinoma, all lesions were of solid consistency and hypoechoic echotexture except one, where the nodule was isoechoic and had a thick but complete halo with well defined margins radiologically the lesion was labeled as benign but later it was proved to be malignant on histopathology. Coarse calcification was observed in one case. The mass in two cases had clustered intra nodular flow on colour Doppler study which was not seen in any benign lesion and hence this appearance is considered to be an important sonographic feature in diagnosing thyroid malignancy. Extra thyroid involvement was not noticed in any case.

Follicular adenoma

They were noted as well defined solid lesions with variable parenchymal echotexture and thin, complete halo surrounding the lesion in 80%

cases. Coarse calcification was noted in 2 cases while rim calcification in one case of benign follicular adenoma. Mixed consistency with solid and cystic areas was noticed in one case. CT scan imaging of adenoma was that of a well defined hypodense nodule on NCCT which showed uniform intense enhancement on post contrast studies. On color doppler examination showed perilesional vascularity in 71.5% cases. In one case the nodule was avascular while in one there was intra nodular flow along with peripheral flow producing the characteristic spoke wheel pattern on colour doppler.

Medullary carcinoma

There was one case of medullary carcinoma that had solid, hypoechoic echogenicity with ill defined and irregular margins. Coarse calcification was noted in this case. Extra thyroid infiltration in the form of cervical lymphadenopathy was noted. Color flow imaging showed intra lesional flow. CT scan showed coarse calcification in an irregular and in homogeneously enhancing nodule.

Anaplastic carcinoma

One case of anaplastic carcinoma was included in the study. Patient was of elderly age. There was diffuse involvement of the thyroid by a solid, hypoechoic lesion. Extra thyroid involvement in the form of cervical lymphadenopathy, muscle infiltration and carotid engulfment was noted. One study described the common presentation of anaplastic carcinoma in elderly as solid hypoechoic mass [28]. One study in 1991 described the sonographic findings in four cases of anaplastic carcinoma which included a poorly marginated hypoechoic mass or masses associated with calcification and invasion of surrounding structures [30].

Metastasis

There were two cases of metastasis to the thyroid. One presented as an ill defined, solid hypoechoic lesion with substernal extension. It was evaluated using CT scanning which showed revealed direct infiltration of thyroid by an oesophageal mass. The other patient had multiple

hypo nodules on USG and on CT scan. FNAC was done which showed metastatic adenocarcinoma from carcinoma lung. Metastasis lesions to the thyroid are rare with limited case reports in literature. One study in 1982 reported two cases of metastasis to thyroid from breast and colon in a study group of 550 patients. One study in 1985 described one case of metastasis to thyroid as having mixed consistency [40].

Lymphoma

One solitary case of secondary lymphoma was encountered which appeared as solid hypoechoic mass with extension into the superior mediastinum and enlarged lymph nodes showing perlesional and intra lesional flow on color doppler studies.

Sonographic distinction between malignant and benign lesions

The majority of malignant thyroid lesions were found to be solid in consistency. Predominant Cystic component was noted in one case.

Higher percentage of solid component in malignant lesions has been reported in many studies [35, 36, 37]. Predominant echopattern observed in malignant lesions was hypoechoic. Similar observations have been documented by various authors [37, 38, 39].

Microcalcification was observed in 2 cases of thyroid malignancy which was not observed in any other thyroid pathologies. A high specificity of microcalcification for malignancy has documented by various authors [40, 41].

Ring or egg shell calcification has been documented by various authors to be reliable indicator of benignancy [42, 43]. Four cases were encountered in our study which showed nodules with rim calcification. One case was revealed to be a benign adenomatous nodule other two cases were diagnosed on pathology as hyper plastic goiter nodule and one patient with papillary carcinoma had rim calcification inside the lesion. This is consistent with other studies that stated

that rim calcification is a reliable indicator of benignity. The non specificity of perinodular halo in distinguishing benign and malignant lesions has been documented by various authors [43, 44]. However the presence of halo has been observed more often in benign lesions by various authors in their study group [44, 45]. Similar observations were made in the present study which revealed halo in 74 % of benign lesions while 20 % of malignant nodules also demonstrated a halo.

As many as 66.7% malignant nodules showed illdefined margins while all benign lesions had well defined margins. Higher incidence of ill defined, irregular margins in malignant lesions Has been reported by various aauthors [41, 42].

Additional Nodule was found at USG in 42 % cases of patients clinically diagnosed as STN. Multi nodulaity was noted in 33% cases of thyroid malignancy. Of the sonographic STN 85 % were proved benign while 15% as malignant, while 26.4 % multi-nodular lesions were proved to be malignant. Similar results were observed in previous studies [42, 43].

Invasion of anatomic structures around the thyroid was observed in 20% cases. Large size in 4 cases and irregular contours of masses precluded a satisfactory sonographic examination. CT Scanning proved vital for evaluation of such malignant lesions. Hence local invasion was found to be highly specific for thyroid malignancies in one study [43]. Cervical adenopathy was seen in 80% cases of malignancy which was not observed in any cases of STN or benign adenoma. However lymphadenopathy was noted in 30% cases with autoimmune thyroiditis (Hashimoto's). One study described cystic degeneration as pathognomic for metastatic nodes from malignant carcinoma which was seen in 1 case of papillary carcinoma in my study group [44].

Thyroglossal cyst

One case was included in our study which appeared as well defined cystic lesion in the

midline of the neck above thyroid cartilage. No tract was seen in either USG, CT or at surgery. These findings were concurrent with other authors [44, 45].

Ectopic thyroid

One case in our study had sublingual location of thyroid gland which was not detected on USG but CT scan revealed a well defined intensely enhancing oval ectopic thyroid gland in sublingual location

Conclusion

In our study 97 patients were radiologically evaluated for thyroid pathology using high resolution USG and/or CT scan.

- High resolution sonography is a useful modality for distinguishing thyroidal from extrathyroidal neck masses.
- It is reliable in distinguishing normal from abnormal thyroid.
- Thyroid sonography is useful in defining whether the patient has a diffuse abnormality, a multinodular pathology or a solitary nodule.
- It is an excellent modality for morphological characterization of thyroid lesions.
- USG is better than CT scan in characterization of thyroid lesions.
- High resolution sonography can differentiate benign from malignant thyroid nodules in most of the cases.
- Highresolution USG is better than CT scan in differentiating benign from malignant thyroid nodules and masses.
- Sonography is very sensitive in detecting local invasion by thyroid malignancies. Tracheal and strap muscles infiltration and carotid sheath entrapment can be accurately diagnosed.
- Sonography can predict retrosternal and substernal extension of the thyroid masses. However, the substernal and retro tracheal components of the thyroid

masses cannot be adequately imaged due to technical constraints.

- CT scan plays an important role in evaluating thyroid masses with substernal or retro tracheal extension which can't be adequately imaged by high resolution USG.
- High resolution USG is useful in diagnosis and follow up of diffuse diseases i.e. Grave's disease, Thyroiditis and simple diffuse goiter.
- High resolution USG can be used precisely to guide FNAC from impalpable thyroid lesions.
- Colour flow imaging alone doesn't add to the sensitivity of high resolution sonography in detection of lesions
- CT scan is complimentary to high resolution USG in evaluation of thyroid masses and in detecting local invasion by thyroid malignancies.
- CT scan is superior to sonography in staging of thyroid malignancies.

High resolution USG is recommended as the primary imaging modality in the evaluation of thyroid diseases. It has a high sensitivity and specificity in the diagnosis of thyroid diseases. CT scan plays a role in evaluation of retrotracheal and retrosternal goiters, large thyroid masses and staging of thyroid malignancies.

References

1. Gharib H, Papini E, Valcavi R, Baskin HJ, Crescenzi A, Dottorini ME, et al. American association of clinical endocrinologists and association medical endocrinology medical guidelines for clinical practice for the diagnosis and management of thyroid nodules. *Endocr pract* 2006; 12(1):63-102.
2. Cooper D.S., Doherty G.M., Haugen B.R. The american thyroid association guidelines taskforce, et al: Management guidelines for patients with thyroid nodules and differentiated

- thyroid cancer. *Thyroid*, 2006; 16: 109-142.
3. Ahuja A, chick W, king W, Metreweli C. Clinical significance of the comet-tail artefact in thyroid ultrasound. *J clin ultrasound*, 1996; 24(3): 129-133.
 4. Shreedevi B Patel. Pictorial essay: Ultrasound features of thyroid and Parathyroid lesions. *Indian Journal of imaging*, 2005; 15(2): 211-215.
 5. Richard Hopkins, Carl C Reading. *Rumack Diagnostic Ultrasound*, Volume 1, edition 2, p. 731-741.
 6. Kim EK, Park CS, Chung WY, et al. New sonographic criteria for recommending fine-needle aspiration biopsy of nonpalpable solid nodules of the thyroid. *AJR Am J Roentgenol*, 2002; 178: 687-91.
 7. Moon WJ, Jung SL, Lee JH, et al. Benign and malignant thyroid nodules: US differentiation—multicenter retrospective study. *Radiology*, 2008; 247: 762-70.
 8. Frates MC, Benson CB, Doubilet PM, et al. Prevalence and distribution of carcinoma in patients with solitary and multiple thyroid nodules on sonography. *J Clin Endocrinol Metab.*, 2006; 91: 3411-17.
 9. Hong YJ, Son EJ, Kim EK, et al. Positive predictive values of sonographic features of solid thyroid nodule. *Clin Imaging*, 2010; 34: 127-33.
 10. Koike E, Noguchi S, Yamashita H, et al. Ultrasonographic characteristics of thyroid nodules: Prediction of malignancy. *Arch Surg*, 2001; 136: 334-37.
 11. Iannuccilli JD, Cronan JJ, Monchik JM. Risk for malignancy of thyroid nodules as assessed by sonographic criteria: The need for biopsy. *J Ultrasound Med*, 2004; 23: 1455-64.
 12. Frates MC, Benson CB, Doubilet PM, et al. Can color Doppler sonography aid in the prediction of malignancy of thyroid nodules? *J Ultrasound Med*, 2003; 22: 127-31.
 13. Papini E, Guglielmi R, Bianchini A, et al. Risk of malignancy in nonpalpable thyroid nodules: Predictive value of ultrasound and color-Doppler features. *J Clin Endocrinol Metab*, 2002; 87: 1941-46.
 14. Lee MJ, Kim EK, Kwak JY, et al. Partially cystic thyroid nodules on ultrasound: probability of malignancy and sonographic differentiation. *Thyroid*, 2009; 19: 341-46.
 15. Shimura H, Haraguchi K, Hiejima Y, et al. Distinct diagnostic criteria for ultrasonographic examination of papillary thyroid carcinoma: A multicenter study. *Thyroid*, 2005; 15: 251-58.
 16. Frates MC, Benson CB, Charboneau JW, et al. Management of thyroid nodules detected at US: Society of Radiologists in Ultrasound consensus conference statement. *Radiology*, 2005; 237: 794 - 800
 17. Cooper DS, Doherty GM, Haugen BR, et al. for the American Thyroid Association (ATA) Guidelines Taskforce on Thyroid Nodules and Differentiated Thyroid Cancer. Revised American Thyroid Association management guidelines for patients with thyroid nodules and differentiated thyroid cancer. *Thyroid*, 2009; 19: 1167-214.
 18. Moon WJ, Baek JH, Jung SL, et al. Ultrasonography and ultrasound-based management of thyroid nodules: Consensus statement and recommendations. *Korean J Radiol*, 2011; 12: 1-14.
 19. MacDonald L, Yazdi HM. Nondiagnostic fine needle aspiration biopsy of the thyroid gland: A diagnostic dilemma. *Acta Cytol*, 1996; 40: 423-28
 20. Yoon JH, Kwak JY, Kim EK, et al. How to approach thyroid nodules with indeterminate cytology. *Ann Surg Oncol*, 2010; 17: 2147-55.

21. Kim DW, Lee EJ, In HS, et al. Sonographic differentiation of partially cystic thyroid nodules: A prospective study. *AJNR Am J Neuroradiol*, 2010; 31: 1961–66.
22. Ahuja AT, Chow L, Chick W, et al. Metastatic cervical nodes in papillary carcinoma of the thyroid: ultrasound and histological correlation. *Clin Radiol*, 1995; 50: 229–31.
23. Kessler A, Rappaport Y, Blank A, et al. Cystic appearance of cervical lymph nodes is characteristic of metastatic papillary thyroid carcinoma. *J Clin Ultrasound*, 2003; 31: 21–25.
24. Yokozawa T, Miyauchi A, Kuma K, et al. Accurate and simple method of diagnosing thyroid nodules by the modified technique of ultrasound-guided fine needle aspiration biopsy. *Thyroid*, 1995; 5: 141–45.
25. Kwak JY, Han KH, Yoon JH, et al. Thyroid imaging reporting and data system for US features of nodules: A step in establishing better stratification of cancer risk. *Radiology*, 2011; 260: 892–99.
26. Horvath E, Majlis S, Rossi R, et al. An ultrasonogram reporting system for thyroid nodules stratifying cancer risk for clinical management. *J Clin Endocrinol Metab*, 2009; 94: 1748–51.
27. Lee YH, Kim DW, In HS, et al. Differentiation of benign and malignant solid thyroid nodules using an US classification system. *Korean J Radiol*, 2011; 12: 559–67.
28. Kim BM, Kim MJ, Kim EK, et al. Sonographic differentiation of thyroid nodules with eggshell calcifications. *J Ultrasound Med*, 2008; 27: 1425–30.
29. Park M, Shin JH, Han BK, et al. Sonography of thyroid nodules with peripheral calcifications. *J Clin Ultrasound*, 2009; 37: 324–28.
30. Jeh SK, Jung SL, Kim BS, et al. Evaluating the degree of conformity of papillary carcinoma and follicular carcinoma to the reported ultrasonographic findings of malignant thyroid tumor. *Korean J Radiol*, 2007; 8: 192–97.
31. Fukunari N, Nagahama M, Sugino K, et al. Clinical evaluation of color Doppler imaging for the differential diagnosis of thyroid follicular lesions. *World J Surg*, 2004; 28: 1261–65.
32. Brander A, Viikinkoski P, Nickels J, Kivisaari L. Thyroid gland: US screening in a random adult population. *Radiology*, 1991; 181: 683–687.
33. Harach HR, Franssila KO, Wasenius VM. Occult papillary carcinoma of the thyroid: A “normal” finding in Finland - A systematic autopsy study. *Cancer*, 1985; 56: 531–538.
34. Tan GH, Gharib H. Thyroid incidentalomas: management approaches to nonpalpable nodules discovered incidentally on thyroid imaging. *Ann Intern Med*, 1997; 126: 226–231.
35. Hoang JK, Lee WK, Lee M, Johnson D, Farrell S. US Features of thyroid malignancy: Pearls and pitfalls. *Radiographics*, 2007; 27: 847–865.
36. Nam-Goong IS, Kim HY, Gong G, et al. Ultrasonography-guided fine needle aspiration of thyroid incidentaloma: Correlation with pathological findings. *Clin Endocrinol (Oxf)*, 2004; 60: 21–28.
37. Leenhardt L, Hejblum G, Franc B, et al. Indications and limits of ultrasound-guided cytology in the management of nonpalpable thyroid nodules. *J Clin Endocrinol Metab*, 1999; 84: 24–28.
38. Titton RL, Gervais DA, Boland GW, Maher MM, Mueller PR. Sonography and sonographically guided fine-needle aspiration biopsy of the thyroid gland: indications and techniques, pearls and pitfalls. *AJR Am J Roentgenol*, 2003; 181: 267–271.
39. Kovacevic DO, Skurla MS. Sonographic diagnosis of thyroid nodules: correlation with the results of sonographically

- guided fine-needle aspiration biopsy. *J Clin Ultrasound*, 2007; 35: 63–67.
40. Shimura H, Haraguchi K, Hiejima Y, et al. Distinct diagnostic criteria for ultrasonographic examination of papillary thyroid carcinoma: A multicenter study. *Thyroid*, 2005; 15: 251–58.
41. Ezzat S, Sarti DA, Cain DR, et al. Thyroid incidentalomas: Prevalence by palpation and ultrasonography. *Arch Intern Med*, 1994; 154: 1838–1840.
42. Jemal A, Murray T, Ward E, et al. Cancer statistics, 2005. *CA Cancer J Clin*, 2005; 55: 10–30. [Erratum in *CA Cancer J Clin* 2005; 55:259]
43. Kountakis SE, Skoulas IG, Maillard AA. The radiologic work-up in thyroid surgery: Fine-needle biopsy versus scintigraphy and ultrasound. *Ear Nose Throat J*, 2002; 81: 151–154.
44. Chan BK, Desser TS, McDougall IR, et al. Common and uncommon sonographic features of papillary thyroid carcinoma. *J Ultrasound Med*, 2003; 22: 1083–1090.
45. Reading CC, Charboneau JW, Hay ID, Sebo TJ. Sonography of thyroid nodules: A “classic pattern” diagnostic approach. *Ultrasound Q*, 2005; 21: 157–165.