

**Case Report**

# Epidermolytic Hyperkeratosis - A rare case report

**Usha Kataria<sup>1\*</sup>, Dinesh Chhillar<sup>2</sup>, S.K. Dhatarwal<sup>3</sup>**

<sup>1</sup>Assistant Professor, Department of Dermatology, BPS Govt. Medical College for Women, Khanpur Kalan, Sonapat (Haryana), India

<sup>2</sup>Resident, Department of Forensic Medicine, Pt. BDS. PGIMS, Rohtak, India

<sup>3</sup>Senior Professor and head, Department of Forensic Medicine, Pt. BDS. PGIMS, Rohtak, India

\*Corresponding author email: [ushachillar@gmail.com](mailto:ushachillar@gmail.com)

**How to cite this article:** Usha Kataria, Dinesh Chhillar, S.K. Dhatarwal. Epidermolytic Hyperkeratosis - A rare case report. IAIM, 2015; 2(6): 232-235.

**Available online at [www.iaimjournal.com](http://www.iaimjournal.com)**

**Received on:** 27-05-2015

**Accepted on:** 14-06-2015

## Abstract

A 20 year old boy presented to the dermatology department for treatment of a congenital ichthyosis with a history of generalized erythroderma and trauma related blistering since birth. At the time of presentation he was noted to have red hyperkeratotic plaques all over the body. Lesions were corrugated over the joint flexures, elbows, knees, and dorsal of hands. In the subsequent months after birth erythema and blistering improved but patient developed hyperkeratotic scaling that was especially prominent over the joint flexures neck, hands and feet. Treatment options include urea or alpha-hydroxy acid containing creams as well as topical and systemic retinoids.

## Key words

Hyperkeratosis, Erythroderma, Congenital, Trauma related blister.

## Introduction

Epidermolytic hyperkeratosis (EHK) is a rare autosomal dominant disorder of Keratinization caused by mutations in either KRT1, or KRT10 gene that presents at birth with generalized erythema, blisters and erosions. EHK is a form of congenital ichthyosis with a prevalence of 1 in 2-3 lakh people [1]. Epidermolytic hyperkeratosis is also known as bullous congenital ichthyosiform erythroderma.

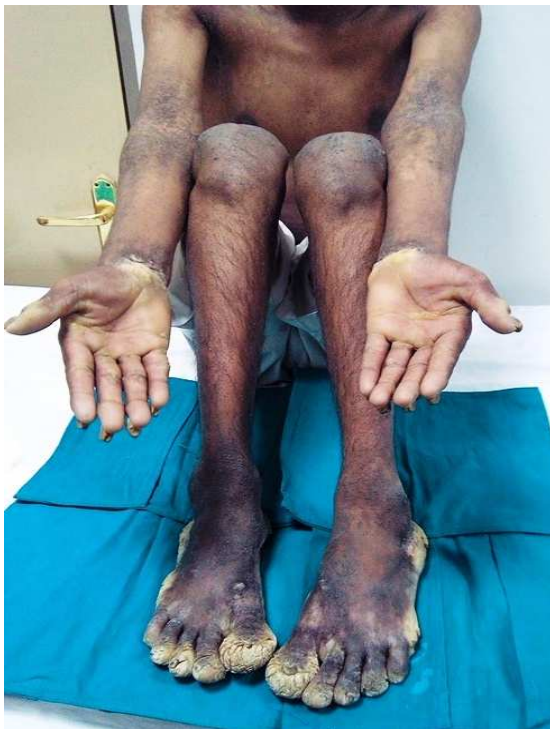## Case report

A 20 years old boy presented to dermatology department with complains of erythroderma and palmo-plantar keratoderma. He had congenital ichthyosis that presented as trauma related blistering after few days of birth. By the age of 3 years, he had developed red hyperkeratotic plaques distributed mainly over his joints. Although he continued to develop erythema and blisters, such episodes had

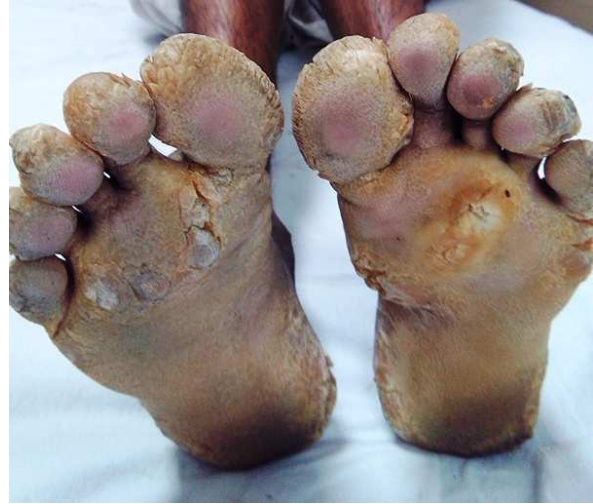decreased in severity and frequency. As the hyperkeratosis became more prominent, the skin developed a foul odor resembling rotten eggs. The patient had thick and curved nails since birth. There was no such disease in the siblings or in other family members. Child was born out of non- consanguineous marriage.

Now after few years of birth he started thickening of palms and soles, were so much thickened that he was unable to walk properly. Patient developed knock Knee problem. On physical examination patient was of short stature and having knock-knee. He had erythematous hyperkeratotic plaques all over the body. Lesions were corrugated mainly involving the flexures, elbows, knees and neck (**Figure - 1**). Palms and soles were involved with yellowish, thickened and macerated skin with foul odor (**Figure - 2**). Toe nails were destroyed and finger nails were thickened with subungual hyperkeratosis (**Figure - 3**). Bilateral knock knee were present.

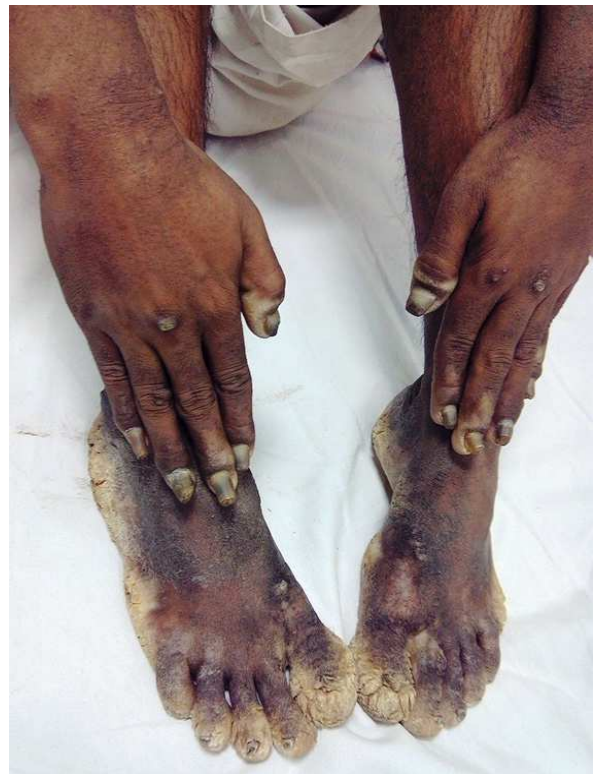**Figure - 1:** Hyperkeratotic lesions over the flexor of elbow and knee joints.



**Figure - 2:** Bilateral involvement of soles with thickened, macerated and yellowish skin.



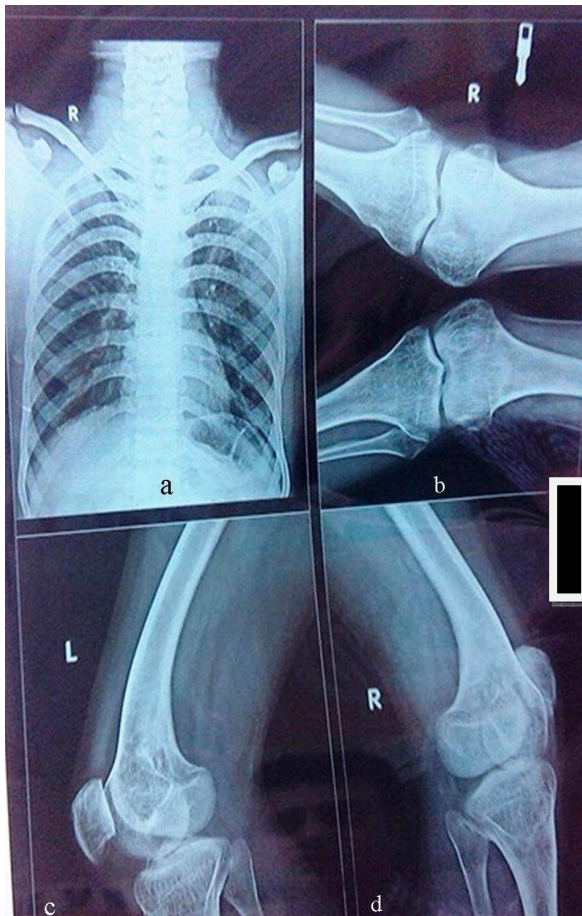
**Figure - 3:** Curved and thickened finger nails with subungual hyperkeratosis and dystrophic toe nails.



Routine laboratory investigations were within normal limits. Radiographs of knee joints were showing knock knee deformity (**Figure - 4**). The patient underwent treatment with a variety of topical and systemic therapies. Keratolytic creams, systemic isotretinoin and systemic

antibiotics were prescribed. Bath with antibacterial soap was advised to remove the odor. The patient is currently being managed with topical keratolytic agents and 20% urea cream.

**Figure - 4:** Radiographs of patient. **a).** Chest (normal), **b).** Knee joints in antero-posterior view showing knock knee deformity, **c).** Left knee joint in lateral view, **d).** Right knee joint in lateral view.



## Discussion

The first clinical description of EHK was made by Broq in 1902 [2]. He coined the term bullous ichthyosiform erythroderma, which is distinguished from the non-blistering condition NBIE. EHK presents at birth with generalized erythroderma. Skin fragility causes blisters and peeling, even with mild trauma. Superficial ulceration develops on the flexural surface;

gradually the erythroderma and blisters improve.

After a few months verrucous hyperkeratotic plaques become more prominent in the Joint flexures. Bacterial colonization of the macerated scales causes a distinct foul odor, which can be partially responsive to topical antimicrobial cleansers. Several phenotypes of EHK have been identified. Involvement of the palm and soles occurs in about 60% of patient with EHK, resulting in recurrent painful fissures and contractures that can lead to functional impairment. In 1994, Digiovanna and Bale described two main clinical categories of EHK. The first type involves the palms and soles and the second type spares the palm and soles [3]. The P S type of EHK has three subtypes: PS-1, PS-2, PS-3. These subtypes present with hyperkeratosis of the palmer and plantar surfaces and varying degrees of erythroderma, scaling and blistering. EHK is inherited as an autosomal dominant trait, but 50% of cases result from spontaneous mutations. Defects in Keratin are responsible for EHK.

Keratin 1 and 10 proteins interact to secure the epithelial cell cytoskeleton. Defects in this protein network causes weakness of keratinocytes that lead to blistering, hyperproliferation and hyperkeratosis. A diagnosis of EHK can usually be made clinically but at times may also require laboratory investigations. Prenatal diagnosis can be obtained by chorionic villous sampling and fetal skin biopsy [4].

## Conclusion

Bullous congenital ichthyosiform erythroderma is an unusual type of inherited ichthyosis by mutations in the gene K1 and K10. Close follow up of the patient and siblings should be done. So we have reported this case for its rarity.



## References

1. Digiovanna J J, Bale S J. Clinical Heterogeneity in epidermolytic hyperkeratosis. Arch dermatol, 1966; 94: 113-26.
2. Broqa L. Erythodermier congenital ichthysioforme avec hyperepidermotrophie. Ann dermatol syphiligr., 1902; 4: 1-31.
3. Digiovanna JJ, Bale SJ. Clinical heterogeneity in epidermolytic hyperkeratosis. Arch Dermatol, 1994; 130(8): 1026-35.
4. Rothnagel JA, Lin MT, Longley MA, Holden RA, Hazen PG, Levy ML, Roop DR. Prenatal diagnosis for keratin mutations to exclude transmission of epidermolytic hyperkeratosis. Prenat Diagn., 1998; 18(8): 826-30.

**Source of support:** Nil

**Conflict of interest:** None declared.