



Case Report

Deeply infiltrating endometriosis in an young woman - A case report

Gayathri A¹, Vani I^{2*}, Nagamani T², Sreevalli M³

¹Assistant Professor, ²Associate Professor, ³PG Student
Dept of OBG, AMC, Visakhapatnam, Andhra Pradesh, India

*Corresponding author email: ivani-20@yahoo.com

How to cite this article: Gayathri A, Vani I, Nagamani T, Sreevalli M. Deeply infiltrating endometriosis in an young woman - A case report. IAIM, 2015; 2(5): 205-209.

Available online at www.iaimjournal.com

Received on: 28-04-2015

Accepted on: 07-05-2015

Abstract

Endometriosis is one of the most important causes of chronic pelvic pain in both adolescent and adult woman. Deeply infiltrated endometriosis is tough case with poor response to medical treatment and associated with complication of visceral damage after surgical treatment. Retroperitoneal fibrosis subsequent to deeply infiltrating endometriosis lesion may encase the ureter and can present as obstructive uropathy. In such cases it is necessary and the only option to free the ureter or else the function of the affected kidney compromises. Such expensive surgeries require skill and competence with a team work in the urological surgeries. Such rare case of gross pelvic endometriosis with left obstructive uropathy was successfully managed and treated by our team.

Key words

Deeply seated endometriosis, Superficial endometriosis, Endometriotic cysts.

Introduction

Endometriosis is a tricky gynaecological problem with no proper etiopathogenesis to explain the lesion and no complete cure seen in the best available treatment option [1]. There are 3 anatomopathological types of endometriotic lesions.

- Superficial endometriotic lesion (peritoneal and/or ovarian)

- Endometriotic cysts(ovarian endometriomas, (OMA)
- Deeply infiltrating lesion (DIE).

DIE is a specific entity defined histologically as lesions that penetrate to depth of 5 mm or more [2]. DIE presents two essential specifications.

- DIE is the multifocal pathology.
- DIE is been often associated with other endometriotic lesion in at least 61% [3].



In 25% of cases DIE are associated with ovarian endometriomas.

The DIE lesion are associated with OMA's the multifocality nature of the DIE lesion is greater. Moreover the lesion is more severe with significant association with intestinal and ureteral lesion. In this situation surgical treatment will require more difficult procedure to be carried out, which is not without risk. Ovarian endometriomas must be considered as marker for severity of DIE [4].

These two characteristic are crucial when defining the modalities for surgical treatment. Because success of surgery is correlated to the radicality of the exercises [5], it is necessary to make a precise diagnosis of the location and type of endometriotic lesions prior to making the slightest decision.

To make a correct diagnosis of DIE, questioning, clinical examination and imaging should be carefully done. In cases of DIE pelvic pain is the chief symptom. The varying grades of clinical symptoms of dysmenorrhoea, dyspareunia, chronic pelvic pain, and bowel and or bladder functional symptoms are present. Detailed questioning gives the gynaecologist the topography of the endometriotic lesions. Clinical examination may reveal bluish puckered lesions in the posterior vaginal fornix on speculum examination [6]. During vaginal examination cobblestone feeling in the posterior fornix is standard finding but is not an absolute rule [7]. In certain cases only the most classical signs like lateral deviation of the cervix, asymmetry of uterosacral ligament with an irregular hardened and tense presentation instead of nodule are evident. The essential semiological point is that from palpation of these lesions causes pain. The accuracy of clinical examination can be increased by carrying out the examination during menstruation [8].

Radiological workup can accurately map the DIE preoperatively. Rectal endoscopic ultrasonography (REUS) is a reliable means of diagnosing infiltration of the bowel wall [9]. MRI presents the great advantage of providing a complete workup of both the anterior and posterior pelvic compartments at one time [9]. This point is important in the view of multifocality of the lesions.

This point makes MRI a key means of Investigation in the preoperative workup of DIE patients. In ureteral involvement, large lateralized posterior DIE lesions MRI offers the possibility of diagnosing ureteral DIE in the uro MRI. Today there is no indication for IVP in cases of suspected ureteral endometriosis. TVUS also is efficient in diagnosing rectal and pelvic endometriosis. But controversial points are that firstly TVUS is operator dependant and right bowel lesions are missed on TVUS [10, 11]. Anatomical distribution of DIE lesions are as per

Table – 1.

Table - 1: Anatomical distribution of DIE lesions.

USL	32.2%
Vagina	14.3%
Bladder	5.9%
Intestine	40.2%
Ureter	7.4%

The treatment modalities are numerous like Expectant Management, Hormonal treatment, Medical treatment for pain and surgical treatment depending on clinical context [12, 13]. DIE Proportion for surgical treatment as per Chappron, et al. [12] is mentioned as below.

- A. Anterior DIE: Laparoscopic partial cystectomy
- P. Posterior DIE
 - P1 USL: Laparoscopic resection USL
 - P2 Vaginal: Lap. Resection of DIE Infiltrated posterior Fornix

- P3 Intestinal
 - P3 a. solely intestinal (V): Intestinal resection with vaginal infiltration. (V+): Lap. Assisted vaginal intestinal resection.
 - P3b. Multiple: Intestinal resection on Laparotomy.

Medical treatment is indicated when [14]

- There is doubt in diagnosis
- Patient refuses surgery
- Recurrent lesion
- As complement to surgery

In the context of infertility, surgery and ART are the only possibilities.

Case report

A 26 years old nulliparous lady of West Godavari District in Andhra Pradesh, suffering from intractable dysmenorrhea since 5 years, not relieved with any analgesics was seen at a private hospital locally in June 2014. USG Abdomen revealed Left ovarian endometriosis and left hydroureteronephrosis Grade-III with chronic cystitis. CECT Abdomen also confirmed left ovarian cyst with compression on ureter with hydro ureteronephrosis on left side and also on right side mild distension. Left ovarian cystectomy was done and the report on histopathology stated as endometriotic cyst.

Later the woman had retention of urine several times for which bladder catheterization was done. DTPA scan reported as moderate hydro nephrosis of left kidney with parenchymal dysfunction and obstructive changes. MR imaging shows gross pelvic endometriosis with retroperitoneal extension chiefly on left side around the ureter.

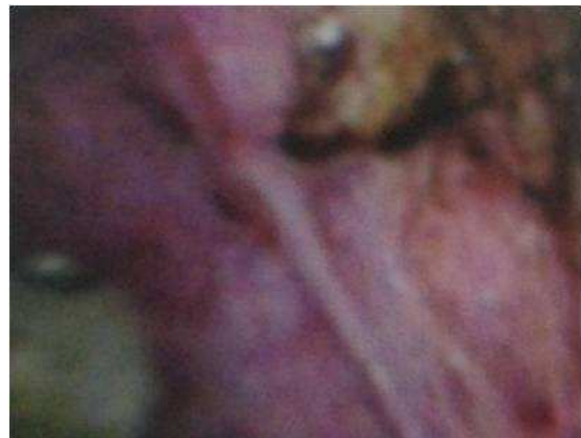She was then referred to our Medical College Hospital for expert management. On General

Examination the woman is normal. Pelvic examination revealed a stony hard vaginal mass in the posterior vaginal fornix and left fornix with puckering and nodularity. All haematological parameters are normal. Renal function test are normal.

On consultation with urologist, ureteral stenting was done on left side to release the compression. Two weeks later the left hydronephrosis resolved partially. The woman was taken up for exploration laparotomy with intention of clearing the pelvic endometriosis as far as possible. Adhesiolysis and clearance of the pouch of Douglas and left parametrium was done to the extent possible. Later an adjuvant therapy she was supplemented with Depot medroxy progesterone acetate injections since she could not afford GnRH treatment.

The woman is under our follow up the ureteral stent removed and left hydroureteronephrosis cleared. HPE of the tissues reported as endometriosis. (Figure – 1, 2, 3, 4, 5)

Figure – 1: Surgical photograph showing DIE.

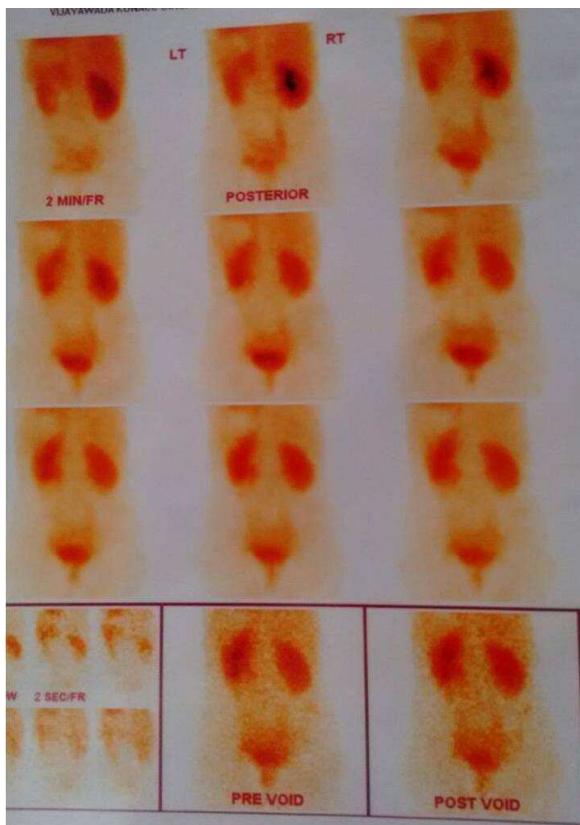


Discussion

When retroperitoneal fibrosis extends around the ureter, it is necessary to free the ureter and adjacent fibrotic tissues. Retroperitoneal fibrosis can extend from invasive disease of USL or from endometrioma adherent peritoneum overlying the ureter. Preoperative insertion of ureteral

catheter is not necessary to improve the surgical skill. Ureterolysis begins with incising normal peritoneum adjacent to the fibrosis. The ureter is identified and then dissected out of the fibrosis by blunt dissection. The dissection process should be thoroughly and better the ureter is tightly grasped as the fibrosis is unroofed from it. If extensive fibrosis which cannot be tackled with blunt dissection are encountered electrocautery with monopolar energy source applied with smallest possible .tip .necessary to break the fibrotic entrapment. The dissection should proceed down the ureter as far as necessary. Invasion of the ureter is rare, but many require resection of a portion of the wall of the ureter or removal of a segment with repair over a stent [15].

Figure – 2: Renal malfunction.



In our case, we could successfully clear the adhesions in POD and in the periureteric area

without difficulty and the patient got relieved of the obstructive uropathy later.

Figure – 3: Ureteral stent.

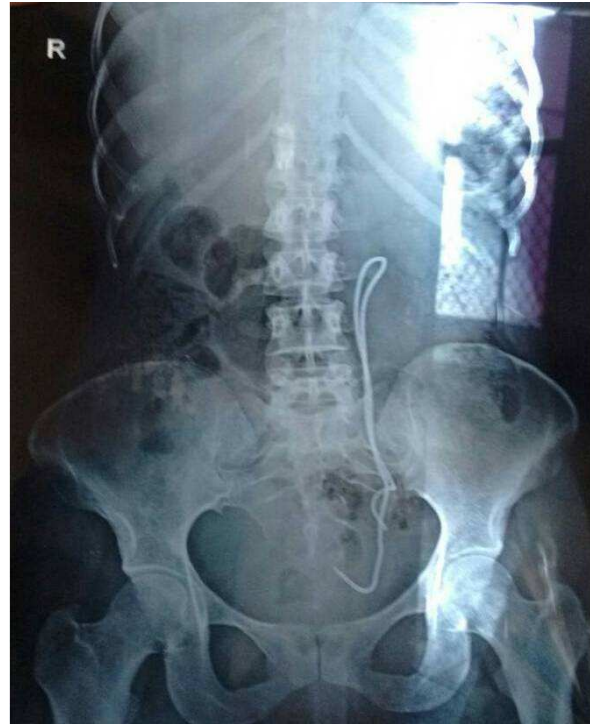
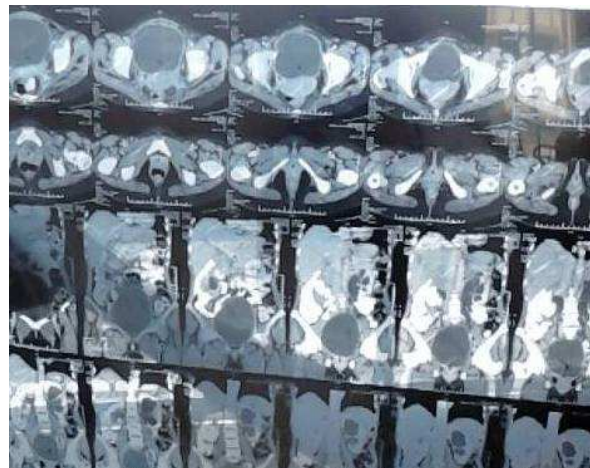
Figure – 4: Ovarian endometrioma on MRI.

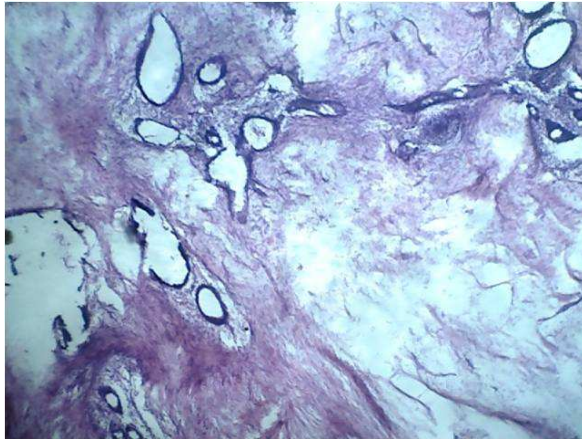


Conclusion

A work up to establish the extent of disease is indispensable. The goal is to establish or precise map of the lesion preoperatively. DIE treatment may be surgical or medical, each of these having

specific indications. In case of surgery, success of treatment depends on how radical the exercise is.

Figure – 5: Histopathological examination (HPE).



Multifocality of the DIE lesion prompts us to give adjuvant treatment even after successful surgery. Defining the appropriate surgical procedure is difficult in DIE Cases, because of the multifocally and open to other treatment options.

References

1. Cornilie FJ, Oosterlynk D. Deeply infiltrating endometriosis histology and clinical significance. *Fertil Steril*, 1990; 53: 98-83.
2. Sampson JA. Peritoneal endometriosis due to premenstrual dissemination of endometrial tissue into peritoneal cavity. *Am J Obstet Gynecol*, 1927; 14: 422-69.
3. Somigliana E, Infantino M. Pathogenic implications of deep endometriosis. *Hum Rep*, 2004; 19: 169-71.
4. Chappron C, Pietin Vialle C. Ovarian endometrioma as marker for DIE, *Fertil Steril* (in press).
5. Chopin N, Viera M. Surgical classification of DIE. *Min invasive Gyn*, 2005; 12: 106-12.
6. Chaperon C, Dubision JB. Routine clinical evaluation not sufficient for DIE. *J Am assoc gynec lap*, 2002; 9: 115-19.
7. Chaperon, Barakat H, Freital X. Presurgical diagnosis of posterior DIE based on standard questionnaire. *Human rep*, 2005; 20: 507-13.
8. Fedele L, Bianche S. Pre surgical evaluation of bladder endometriosis. *Human rep*, 2007; 22: 2698-01.
9. Chappron C, Douset B. Rectal sonography for deep endometriosis. *Human rep*, 1998; 13: 2266-70.
10. Kinkel K, Chappron C. MRI in DIE. *Human rep*, 1999; 14: 1080-86.
11. Donnez J, Nisolle M. Ureteral endometriosis and complications. *J Am gynec lap*, 2002, 77: 32-37.
12. Chaperon C, Fauconier A. Anatomical distribution and surgical implications and proposed classification. *Human rep*, 2003; 18: 157-61.
13. Hurd WW. Criteria that indicate endometriosis as cause of pelvic pain. *J obs gyn J*, 1998; 92: 1029-32.
14. *Obstetrics and Gynecology perspective*, edited by N D Motashaw. Orient Longmann publication, 1998.
15. Bazot M, Thomassin I. Diagnostic accuracy of TVUS in DIE. *Ultrasound in obs gyn J*, 2004; 24: 180-85.

Source of support: Nil

Conflict of interest: None declared.