



Case Report

Macronodular hepatic tuberculosis mimicking hydatid cyst: A case report

Ali CIFTCI¹, Cagri TIRYAKI¹, Murat Burc YAZICIOGLU^{2*}, Mustafa
Celaletin HAKSAL¹, Murat COSKUN¹, Selim Yigit YILDIZ¹, Ibrahim
KUSKONMAZ³

¹General Surgeon, Department of General Surgery, Kocaeli Derince Training and Research Hospital,
Kocaeli, Turkey

²General Surgeon, Department of General Surgery, Medipol University, Faculty of Medicine,
Department of Surgery, Istanbul, Turkey

³Pathologist, Department of Pathology, Kocaeli Derince Training and Research Hospital, Kocaeli,
Turkey

*Corresponding author email: mbyazicioglu@gmail.com

How to cite this article: Ali CIFTCI, Cagri TIRYAKI, Murat Burc YAZICIOGLU, Mustafa Celaletin HAKSAL, Murat COSKUN, Selim Yigit YILDIZ, Ibrahim KUSKONMAZ. Macronodular hepatic tuberculosis mimicking hydatid cyst: A case report. IAIM, 2015; 2(4): 203-206.

Available online at www.iaimjournal.com

Received on: 31-03-2015

Accepted on: 07-04-2015

Abstract

Isolated hepatic tuberculosis is called hepatic tuberculoma. It is a very rare granulomatous liver disease and constitutes less than 1% of all tuberculosis cases. Its clinical features are non-specific. Imaging-guided fine needle aspiration biopsy by ultrasonography or computed tomography (CT) is the best way to confirm the diagnosis. The patients are treated with a combination of medicine such as rifampicin, isoniazid, ethambutol, and pyrazinamide. Here, we have reported a case of 42-year old male patient with macronodular hepatic tuberculosis. His CT imaging was reported as type IV hydatid cyst and also had a positive indirect hemagglutination test.

Key words

Macronodular Hepatic Tuberculosis, Hydatid Cyst, Granulomatous Liver Disease, Isolated Hepatic Tuberculosis.

Introduction

Tuberculosis (TB) basically a lung infection, but can be affect several organ systems. Tuberculous infection of liver is uncommon in

the clinical practice but relatively well described in patients with widespread military TB. However, isolated hepatic tuberculosis (IHT) called hepatic tuberculoma is very rare granulomatous liver disease [1, 2], and may be

missed. Here, we have reported a case of IHT in 42-year-old male patients who had a positive indirect hemagglutination test and CT images mimicked type IV hydatid cyst.

Case report

42-year-old male patient was admitted to our clinic with right upper quadrant pain. He complaint of dyspeptic problems was first started 6-7 months ago. In his past medical history, he had no systemic disease or drug use habits. Physical examination revealed a minimal tenderness in the right upper quadrant other than was normal and no pathological breath sounds were heard. He had a normal blood count. However minimal increase in alkaline phosphatase was found while others were totally normal. An elevation in sedimentation rate and CRP was found (44 mm / h (normal: 0-15) and 9.82 mg/L respectively). Tumor markers such as AFP, CEA and CA 19-9 were within normal ranges. Indirect hemagglutination test for hydatid cyst was reported as 1/4096 that was accepted as positive titer values. The ultrasonographic examination was reported as a stage III-IV hydatid cyst with calcific wall, occupied nearly entire of right lobe of liver. MRI imaging of abdomen was performed and reported as a mass in the anterior and posterior segments of right liver lobe with irregular contours, cystic area in the central part and showed an extension to superior. **(Photo - 1)** The dimension of the mass was calculated as 182x91 mm and established no pathological holding of contrast after intravenous injection of contrast agent.

The patient was operated with the diagnosis of hepatic hydatid cyst in the right lobe. A right subcostal incision was performed and a cystic mass in size 20x15 cm with white calcified wall which was completely filled the right lobe of the liver was found. The liver was wrapped with 3% hypertonic saline impregnated pads. Cystic

cavity was filled with 3% NaCl and after 5 minutes cyst wall was opened and aspirated. The wall of cyst was so firm and 3 cystic cavities were seen in it. Apart of anterior surface of the cyst wall was resected for pathological examination but we should not able to resected calcified cyst wall totally. The cavity was washed again with 3% NaCl. The patient was discharged on the postoperative 4th day uneventfully. The pathological examination was reported as a calcified granulomatous reaction which is compatible with tuberculosis. **(Photo - 2)** The patient was referred to outpatient chest disease clinics for further medical treatment.

Photo - 1: MRI view of 182x91 mm mass.

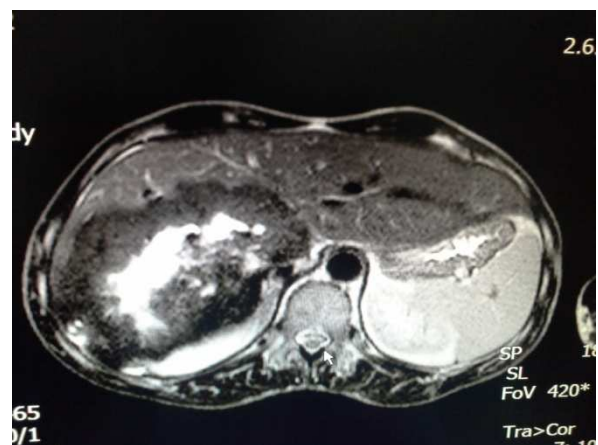
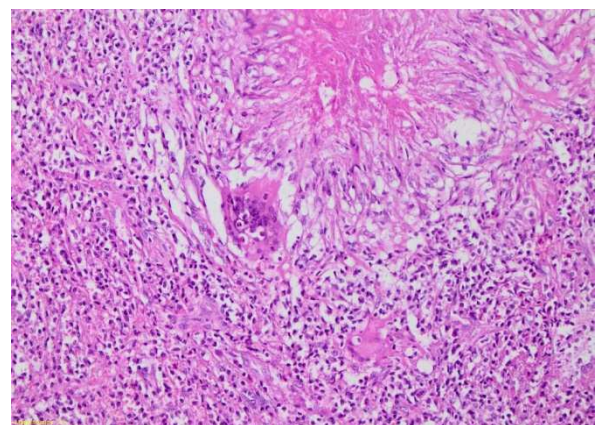


Photo - 2: Granulomatous lesion characterized with Histocyte, Mononuclear inflammatory cells and Giant cells accompanying around caseous necrosis. (H&E stain, 200X)





Discussion

Tuberculosis (TB) is still an important health problem of developing countries. Although most of the cases come up as pulmonary tuberculosis, hepatic tuberculosis is rare and constitutes less than 1% of all patient cases of tuberculosis [1, 2]. IHT is extremely rare with less than 30 cases being reported in the literature [3]. Hepatic tuberculosis is classified by Levine as miliary tuberculosis, primary acute pulmonary tuberculosis with hepatic involvement, chronic pulmonary tuberculosis with hepatic involvement, primary liver tuberculosis, focal tuberculoma (or abscess) and tuberculous cholangitis [4]. If the size of the hepatic nodules is greater than 2 mm, they are generally diagnosed as macronodular hepatic tuberculosis [5]. In our case, the right liver lobe was nearly filled with a mass of 20x15 cm size so is accepted as patient as macronodular hepatic tuberculosis.

The clinical feature of hepatic tuberculosis is usually insidious and often non-specific that may results in diagnostic delay. The main signs of hepatic tuberculosis include right upper abdominal pain, upper abdominal tenderness, low-grade fever, night sweat, weight-loss and fatigue, abdominal mass, hepatomegaly and jaundice. Hepatomegaly is the most common clinical feature among these signs [6, 7, 8]. The laboratory investigation generally shows an increase in alkaline phosphatase, with normal transaminases [9]. But in our case these laboratory tests were normal however the significant increased of indirect hemagglutination test was considered as false positive.

The diagnosis of hepatic macronodular tuberculosis is often difficult because lots of diseases can mimic this pathology [5, 9, 10]. According to the related domestic reports, hepatic tuberculosis is often misdiagnosed as

liver cancer, liver abscess, benign tumor of liver, liver cysts, liver hydatid and so on. The average rate of misdiagnosis is 93.1% [11].

The gold standard in the diagnosis of tuberculosis disease is isolating the bacilli in the culture specimens [12]. In extra pulmonary tuberculosis, acid resistant bacilli (ARB) examination of sputum has no aid in diagnosis because of no pulmonary contribution. Therefore definitive diagnosis of isolated macronodular hepatic tuberculosis can be done with ultrasound or CT guided liver biopsy or histopathologic examination of surgical specimen [12]. In our case, we did not performed an ultrasound guided liver biopsy because of hydatid cyst of the liver could not be ruled out. The disease usually treated with different procedures such as liver segmentectomy, cystectomy or cystotomy because it mimics other diseases [13]. We applied cystotomy, biopsy from the cyst wall and external drainage. Medical treatment of IHT is similar to that of pulmonary tuberculosis because it is accepted as a part of systemic tuberculosis. The drugs combined with rifampicin, isoniazid, ethambutol, and pyrazinamide are used in the medical treatment as well. So that the patients who was diagnosed IHT by postoperative pathological examination of specimens should be treated with same medical protocol [14]. In case of tubercular abscess formation, computed tomography and ultrasonography guided drainage can be used for drainage [15].

Conclusion

As a conclusion, the macronodular hepatic tuberculosis may confused with several diseases especially hepatic metastases and liver carcinoma, may also be confused with advanced stage hydatid cyst. The macronodular hepatic tuberculosis should also be kept in mind in



differential diagnosis of mass or cystic lesions such as liver hydatid cysts especially in a high TB prevalence.

References

1. Kok KY, Yapp SK. Isolated hepatic tuberculosis: Report of five cases and review of the literature. *J Hepatobiliary Pancreat Surg*, 1999; 6: 195-198.
2. Mert A, Ozaras R, Tabak F, et al. Localized hepatic tuberculosis. *Eur J Intern Med*, 2003; 14: 511-512.
3. Bikhchandani J, Malik VK, Kumar V, Sharma S. Hepatic tuberculosis mimicking carcinoma gall bladder. *Indian J Gastroenterol*, 2005; 24: 25.
4. Levine C. Primary macronodular hepatic tuberculosis: US and CT appearances. *Gastrointest Radiol*, 1990; 15: 307-309.
5. Zipser RD, Rau JE, Ricketts RR, et al. Tuberculous pseudotumors of the liver. *Am J Med*, 1976; 61: 946-951.
6. Chong VH. Hepatobiliary tuberculosis: A review of presentations and outcomes. *South Med J*, 2008; 101: 356-61.
7. Fang SG, Yang JZ. Diagnosis of hepatic tuberculosis. *Shijie Huaren Xiaohua Zazhi*, 1999; 7: 412-413.
8. Li YH, Chi J. Clinical and pathological features of hepatospleic tuberculosis. *J Chin Med Univ*, 1996; 25: 193-194.
9. Brookes M.J., Field M., Dawkins D.M., et al. Massive primary hepatic tuberculoma mimicking hepatocellular carcinoma in an immunocompetent. *MedGenMed*, 2006; 8(3): 11.
10. Küçükmetin, et al. Isolated hepatic tuberculosis and mass lesions. *Turk J Gastroenterol*, 2014; 25: 110-2.
11. Liao JR, Zhang D, Wu XL. Pulmonary tuberculosis combined with hepatic tuberculosis: A case report and literature review. *The Clinical Respiratory Journal*, 2014.
12. Hopewell PC. Tuberculosis and Other Mycobacterial Diseases. In: Mason RJ, Murray JF, Broaddus VC, Madel JA, editors *Murray and Nadel's Textbook of Respiratory Medicine*, 4th edition, Elsevier- Saunders Philadelphia, 2005; p. 979-1043.
13. Xing X, Li H, Liu WG. Hepatic segmentectomy for treatment of hepatic tuberculous pseudotumor. *Hepatobiliary Pancreat Dis Int*, 2005; 4(4): 565-568.
14. Plumber ST, Pipalia DH, Vora IM, Bhambhure N, Naik SR. Hepatic granulomas: Profile and follow up of 10 cases responding to antituberculous therapy. *J Assoc Physician India*, 1987; 35: 207.
15. Wilde CC, Kueh YK. Tuberculous hepatic and splenic abscess. *Clin. Radiol*, 1991; 43: 215-6.

Source of support: Nil

Conflict of interest: None declared.