



Case Report

# **Malignant gastrointestinal stromal tumors (GISTs) of the duodenum – A rare occurrence: Case report**

**Kandukuri Mahesh Kumar<sup>1\*</sup>, Ch. Krishna Reddy<sup>1</sup>, T. Divyagna<sup>1</sup>, R. Swarupa<sup>2</sup>, Chintakindi Sravan<sup>3</sup>, K. Shashi Kiran<sup>4</sup>**

<sup>1</sup>Assistant Professor, Malla Reddy Institute of Medical Sciences (MRIMS), Hyderabad, Telangana State, India

<sup>2</sup>Assistant Professor, Malla Reddy Medical College for Women (MRMCW), Hyderabad, Telangana State, India

<sup>3</sup>Pathologist, Vijaya Diagnostic Center, Hyderabad, Telangana State, India

<sup>4</sup>Pathologist, Omega Cancer Hospital, Hyderabad, Telangana State, India

\*Corresponding author email: [doctormaheshgoud@gmail.com](mailto:doctormaheshgoud@gmail.com)

**How to cite this article:** Kandukuri Mahesh Kumar, Ch. Krishna Reddy, T. Divyagna, R. Swarupa, Chintakindi Sravan, K. Shashi Kiran. Malignant gastrointestinal stromal tumors (GISTs) of the duodenum – A rare occurrence: Case report. IAIM, 2015; 2(3): 188-192.

**Available online at [www.iaimjournal.com](http://www.iaimjournal.com)**

**Received on:** 17-02-2015

**Accepted on:** 23-02-2015

## **Abstract**

Gastrointestinal stromal tumors (GISTs) are the most common mesenchymal tumors of the gastrointestinal (GI) tract. Most of the cases are located in the stomach followed by the small intestine. They arise from the interstitial cells of cajal, which are located in the wall of the intestine. Malignant GISTs are rare type of tumors in GIT. Small intestine GIST is more likely to be malignant compared to stomach. Here we reported such a rare case of malignant GIST in a 54 years old female patient who came to the hospital with complaints of pain and mass in abdomen. Ultrasound revealed a mass originating from the duodenum. Provisional clinical diagnosis of duodenal carcinoma was considered preoperatively. Patient underwent complete surgical excision of the tumor. Histopathological examination confirmed the diagnosis of malignant GIST. As the recurrence rate for malignant GIST is high, patient was kept on follow up.

## **Key words**

GIST, Malignancy, Mesenchymal, Small intestine, C-KIT, DOG-1.

## Introduction

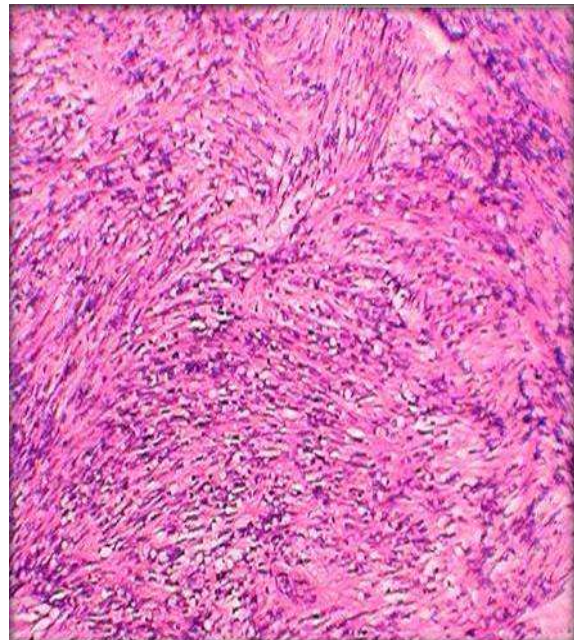
The gastrointestinal stromal tumor (GIST) is the most common mesenchymal neoplasm of the gastrointestinal (GI) tract. GIST accounts for approximately 0.1-3% of all gastrointestinal tract tumors [1, 2]. They occur mostly in stomach followed by the small intestine. However, they may occur anywhere in the GI tract including the mesentery, retroperitoneum and omentum [2, 3]. These tumors arise from the interstitial cells of cajal, pace maker cells located between myenteric plexus cells and smooth muscle cells of the GIT [3]. Gastrointestinal stromal tumors (GISTs), were formerly classified as leiomyomas or leiomyosarcomas, are mesenchymal tumors of the gastrointestinal tract (GIT). The definition of GIST was first proposed by Mazur and Clark (1983) [1, 2]. Malignancy in GIST is common in cases occurring in small intestine compared to the stomach. Several factors are taken into consideration for diagnosing malignancy potential of GIST.

## Case report

A 54 years old female patient came to our hospital with complaints of pain and mass in the abdomen since 1 year and complaints of loss of appetite and loss of weight since 5 months. There were three episodes of vomiting since last 2 months. She was a known case of hypertension and on medication regularly. Other than that she had no significant past history. On examination, there was a lump noted in the right hypochondriac region measuring 6x2 cm. Routine blood investigation were normal. Ultrasound abdomen revealed mass originating from the duodenum. Clinical diagnosis of the duodenal carcinoma was made and patient posted for surgery. Complete excision of the mass was done and specimen was sent for histopathological examination. Sections were made from the tissue, stained with hematoxylin and eosin and examined under microscope. On

microscopy, tumor tissue was arranged in fascicles and interlacing bundles with increased cellular content and thin stroma. **(Photo – 1)** Individual cells were aggressive looking spindle to oval cells with high nuclear cytoplasmic ratio and coarse dispersed chromatin. **(Photo - 2)** Mitotic index was very high per field. At few areas there were areas of necrosis noted. Diagnosis of malignant GIST was made.

**Photo – 1:** Photomicrograph showing tumor tissue arranged in fascicles and interlacing bundles with increased cellular content and thin stroma. (Low power view)

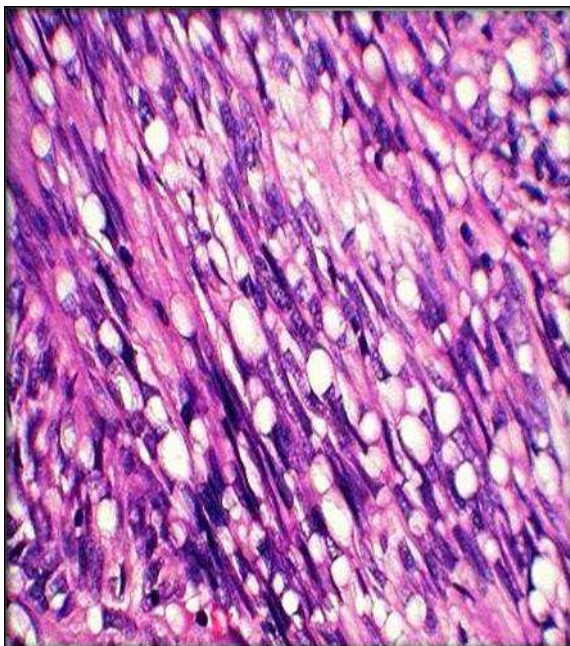


## Discussion

Gastrointestinal stromal tumors (GIST) are the most common non-epithelial tumors of gastrointestinal tract arising from the interstitial cells of cajal and constitute 80% of mesenchymal neoplasm of the gastrointestinal tract and represents about 5% of all sarcomas [4]. On ultra structural examination, the cells of Cajal show both smooth muscle and neural differentiation, accounting for different variants of GIST. GIST most commonly arises from the stomach (60 - 70%) and small intestine (20 - 30%) with < 10%

arising from the rest of the gastrointestinal tract like esophagus, colon, rectum or extra intestinal sites such as omentum, mesentery and retroperitoneum [2, 4]. The peak incidence of GIST was found in the 4<sup>th</sup> and 5<sup>th</sup> decades with a male preponderance in a ratio of 3: 1 [5] but our case was seen in female patient. Most GISTs (95%) have a mutation in the c-kit proto-oncogene, leading to the constitutive expression of KIT protein and 5% of cases have activating mutation in the PDGFRA gene [6].

**Photo – 2:** Photomicrograph showing aggressive looking spindle to oval cells with high nuclear cytoplasmic ratio and coarse dispersed chromatin. High mitotic index was present.



Clinical symptoms are related to the size and location of the GISTs. GISTs of the esophagus typically present with dysphagia. Gastric and small intestinal GISTs often present with vague symptoms, but sometimes they cause upper gastrointestinal bleeding. Colorectal GISTs may manifest with lower gastrointestinal bleeding, colonic perforation, pain, obstruction or combination [2, 5]. In present case patient presented with abdominal pain and mass. The

clinical and ultrasonographic findings of GISTs are non-characteristic and therefore a preoperative presumptive diagnosis based on these features is difficult [2]. Definitive diagnosis made only by the histopathological examination.

Microscopically, GISTs are well-circumscribed smooth lobulated, unencapsulated tumors. They are composed of spindle cells or epithelioid cells, or a mixture of both, and may show areas of cystic degeneration, necrosis or focal hemorrhage [2, 5]. Most of the GIST cases are of benign or of low malignant potential, but cases arising from small intestine are highly malignant and aggressive when compared to stomach.

Histological criteria have not been well established to predict the malignant potential of GIST. Prognosis of the GIST correlated well with mitotic count, tumor size, tumor cellularity, tumor necrosis, anatomical location, invasive growth and expression of Ki-67 and PCNA index [7]. Most pathologists use a combination of tumor size and mitotic rate to assess the malignant potential of these tumors. Features favoring malignancy are: size > 5 cm, mitotic rate > 5/50 hpf (high power field), high cellularity, nuclear pleomorphism, and necrosis [8]. Our case showed size >5 cm, high cellularity, mitotic activity >10/50 hpf, nuclear pleomorphism and high proliferative rate, hence classified under malignant category.

The differential diagnosis of spindle cell tumors of gastrointestinal tract consists of leiomyoma, schwannoma, and fibromatosis. The immunohistochemical marker, c-Kit (CD117) identifies tumors originating from the pacemaker cells of Cajal, seems to be the most specific diagnostic marker, and helps in differentiation from tumors.

Five percent of the tumors with morphological features of GIST were negative for CD117, which



is attributed to the presence of activating mutation of platelet-derived growth factor receptor alpha (PDGFRA) and they are identified by the immunostaining with PDGFR marker. Recently, a new marker was discovered on GIST (DOG-1) expressed independently of c-KIT or PDGFRA status and can therefore be useful for the identification of CD117-negative tumors [1].

GIST mostly metastasizes within the abdomen, and the most common sites for the development of metastasis are the liver and peritoneum however, rare metastasis to central nervous system [9] has also reported. Lymph nodal metastasis is rare hence, nodal resection during surgery is not mandatory.

The treatment of choice for malignant GISTs should be surgical resection, along with imatinib mesylate therapy [8, 9]. Recently, however, imatinib mesylate has been introduced as a molecular-targeted chemotherapeutic agent. Imatinib mesylate is the first effective systemic therapy for locally unresectable or metastatic GIST. Following resistance to imatinib mesylate, sunitinib, a multi targeted small-molecule tyrosine kinase inhibitor that selectively blocks vascular endothelial growth factor receptors (VEGFRs) with potent activity against KIT and PDGFA, has proven effective as a second-line therapy [4, 9].

Recurrences are extremely rare for low malignant potential GISTs, while >80% of high malignant potential GISTs will recur and hence close follow-up by imaging techniques is required [8].

## Conclusion

GISTs are the most common mesenchymal tumors of gastrointestinal tract. They arise mostly in the stomach followed by the small intestine. As malignancy is common with small

intestine GISTs, they have to be evaluated carefully. Definite criteria are followed for diagnosing malignancy, which include tumor size, cellularity, mitotic count, necrosis, pleomorphism and proliferative index. Treatment includes surgical excision and targeted therapy with Imatinib mesylate. Patient with malignant GIST have high recurrence hence, followed regularly.

## References

1. Qi Y, Zhao W, Wang Z, Li T, Meng X. Tumor sites and microscopic indicators are independent prognosis predictors of gastrointestinal stromal tumors. *Tohoku J Exp Med.*, 2014; 233(1): 65-72.
2. Varras M, Vlachakos N, Akrivis C, Vasilakaki T, Skafida E. Malignant gastrointestinal stromal tumor presenting with hemoperitoneum in puerperium: Report of a case with review of the literature. *World J Surg Oncol.*, 2010; 8: 95.
3. Agaimy A. Gastrointestinal stromal tumors (GIST) from risk stratification systems to the new TNM proposal: More questions than answers? A review emphasizing the need for a standardized GIST reporting. *Int J Clin Exp Pathol.*, 2010; 3(5): 461-71.
4. Bayraktar UD, Bayraktar S, Rocha-Lima CM. Molecular basis and management of gastrointestinal stromal tumors. *World J Gastroenterol.*, 2010; 16(22): 2726-34.
5. Lakshmi VA, Chacko RT, Kurian S. Gastrointestinal stromal tumors: A 7-year experience from a tertiary care hospital. *Indian J Pathol Microbiol.*, 2010; 53(4): 628-33.
6. Hou YY, Lu SH, Zhou Y, Qi WD, Shi Y, Tan YS, et al. Stage and histological grade of gastrointestinal stromal tumors based





- on a new approach are strongly associated with clinical behaviors. *Mod Pathol.*, 2009; 22(4): 556-69.
7. Wang X, Mori I, Tang W, Utsunomiya H, Nakamura M, Nakamura Y, et al. Helpful parameter for malignant potential of gastrointestinal stromal tumors (GIST). *Jpn J Clin Oncol.*, 2002; 32(9): 347-51.
  8. Shukla S, Singh SK, Pujani M. Multicentric malignant gastrointestinal stromal tumor. *Saudi J Gastroenterol.*, 2009; 15(1): 45-8.
  9. Sato K, Tanaka T, Kato N, Ishii T, Terao T, Murayama Y. Metastatic cerebellar gastrointestinal stromal tumor with obstructive hydrocephalus arising from the small intestine: A case report and review of the literature. *Case Rep Oncol Med.*, 2014; 2014: 343178.

**Source of support:** Nil

**Conflict of interest:** None declared.