

A congenital anterior urethral diverticulum associated with obstructive urinary symptoms in a 1-year-old male child: A case report and review of the literature

Mehmet Hanifi Okur, Bahattin Aydogdu, Serkan Arslan, Erol Basuguy

Department of Pediatric Surgery, Faculty of Medicine, Dicle University, Diyarbakir, Turkey

Abstract Congenital anterior urethral diverticula are rarely found in children. We present the case of a 1-year-old male child with a congenital anterior urethral diverticulum. This condition can lead to obstructive lower urinary tract symptoms and urosepsis. The clinical presentation, diagnosis, and management of this rare condition are discussed in this report. The diagnosis was made using retrograde urethrography. Patient was treated with open diverticulectomy and urethroplasty.

Key Words Anterior urethral diverticulum, child, urinary obstruction

Copyright © 2015 pediatricurologycasereports.com.

Corresponding Author: Mehmet Hanifi Okur, M.D.,

Department of Pediatric Surgery, Faculty of Medicine,

Dicle University, Diyarbakir, Turkey

E mail: mhanifi-okur@hotmail.com

Accepted for publication: 10 February 2015

INTRODUCTION

Congenital anterior urethral diverticula are an uncommon entity in children, and they have congenital and acquired forms. Over the past 20 years, 260 cases have been reported [1]. Several possible causes of the

congenital diverticulum have been suggested, including a developmental defect of the corpus spongiosum, cystic dilatation of the urethral glands, and sequestration of an epithelial nest after closure of the urethral folds [2].

We describe an uncommon presentation of an anterior urethral diverticulum causing obstructive urinary symptoms that were not associated with the anterior urethral valve in a 1-year-old child. We also describe possible

diagnoses of the condition and its successful management with open surgery. A brief review of the literature is also presented.

CASE REPORT

A 1-year-old male child presented with a history of dribbling urine since birth, swelling on the ventral surface of penis, and recurrent urinary tract infections. Additionally, his parents noticed that he had never had a good urinary stream. The diverticulum was at the ventral surface of the mid-penile urethra and measured about 3 cm in length (Fig. 1 and 2).

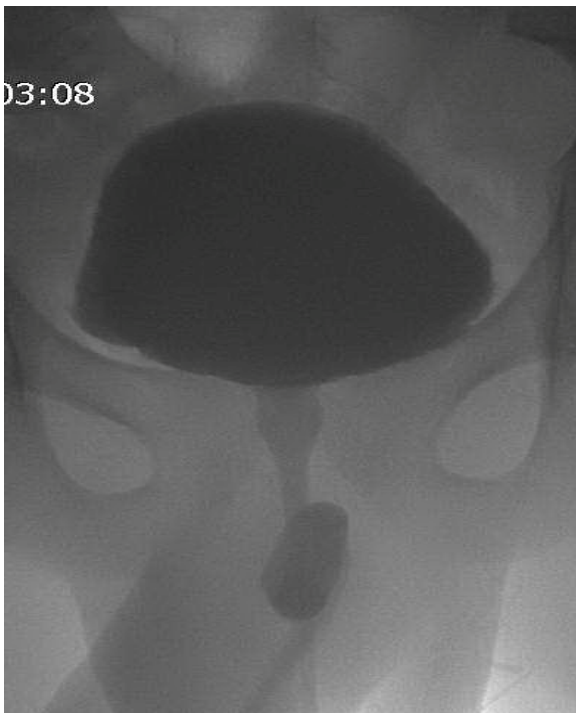

Fig. 1. RGU showing diverticulum at urethra.

An examination revealed no abnormalities. The urinalysis, routine blood counts and blood urea, and serum creatinine were

normal. Ultrasonography (US) of the urinary tract showed a normal size and shape of both kidneys and a normal urinary bladder.

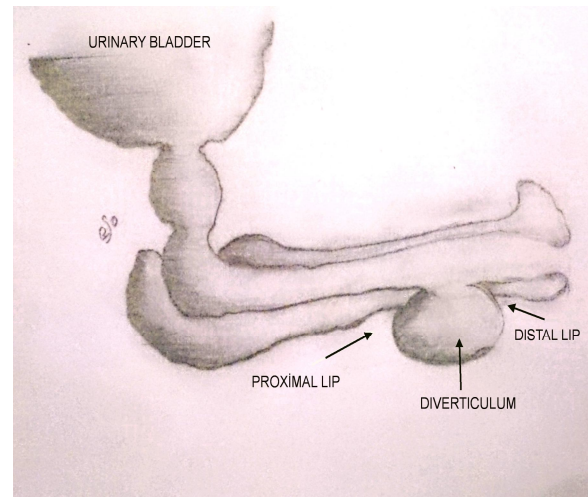


Fig. 2. Anatomical appearance of congenital diverticula.

A retrograde urethrogram (RGU) showed the presence of a diverticulum in the urethra at the penile urethra level (Fig. 1). Urethroscopy revealed the presence of a midline urethral diverticulum and mild trabeculation of the bladder. The patient underwent open diverticulectomy and urethroplasty due to the rather large size of the diverticulum. The post-operative period was uneventful, and the catheter was removed after 10 days. At the six-month follow-up, the patient had a normal urinary stream and no urinary complaints, and a urethrogram showed no urethral abnormalities.

DISCUSSION

Congenital anterior urethral diverticulum is a rare condition, and the embryology remains unclear. Diverticula are frequently found on the ventral surface and in the anterior urethra. Their diameter is typically 3–5 cm [3]. Diverticula can be described as saccular or diffuse. The saccular type is a localized protrusion from the urethral lumen into the ventral wall of the anterior urethra, and the diffuse type is a generalized dilatation of the entire anterior urethra. A congenital saccular diverticulum may produce anterior urethral obstruction by a valve-like mechanism of its distal lip, which obscures the urethral lumen during filling [4, 5]. Different theories have been suggested to describe the development of congenital anterior urethral diverticula. One theory is that they are the result of a partial lack of spongy body, which is associated with hypospadias. Another is that they are associated with the valves of the anterior urethra. A third theory is that they are caused by the spontaneous rupture of paraurethral cysts toward the lumen of the urethra [2,6,7]. Additionally, diverticula may be present in the anterior urethral valve. In this case, they would not be true diverticula. In a true congenital anterior

urethral diverticulum, an acute angle is formed between the proximal part of the dilated portion and the ventral floor [8].

The clinical symptoms are associated with the patient's age and the presence of obstruction. Newborns and infants present with symptoms such as fever, diarrhea, and vomiting. The main symptoms in older children are a thin urinary stream, frequent urination, dysuria, urinary incontinence, urine retention, and stone formation. Additionally, obstruction of the urethral lumen and swelling in the penis during micturition are two other important findings in infants and older children [3,9,10].

Clinical examination and retrograde urethrography with micturating cystourethrography are sufficient for diagnosing most patients. Additionally, sonourethrography is now also being used as help processes [11,12]. Cystourethroscopy is therapeutic for the diagnosis of a congenital urethral diverticulum. Diverticula typically are an outpouching from the ventral wall of the urethra and have a proximal and distal rim [14].

The management of congenital anterior urethral diverticula depends on their type, size, and associated complications. They can

be managed by endoscopic or open surgical excision. For small anterior diverticula, transurethral resection of the distal obstructing lip with a pediatric resectoscope is a good treatment approach [3,14,15]. However, this does not always eliminate urinary stasis or the bulging of the diverticulum; in this case, treatment with open surgery should be performed. For large diverticula, open surgical excision is required [1,16]. If the patient has urosepsis or obstructive nephropathy, a temporary urinary diversion by way of suprapubic catheterization can be performed before any definitive reconstruction is done [1,3]. The primary differential diagnostic considerations are the anterior urethral valve and dilatation of the Cowper's gland ducts. Additionally, saccular dilatation of the distal ventral urethra is also commonly seen after hypospadias repair [4,5]. This study presented the case of a 1-year-old with a congenital anterior urethral

diverticulum with obstructive symptoms and a history of recurrent urinary tract infections. The diverticulum was 3 cm in diameter. Based on these findings, the patient was treated surgically. The patient's symptoms disappeared after successful treatment made by open diverticulectomy and urethroplasty. When a patient with diverticulum has a clinical such as urosepsis or obstructive nephropathy, a temporary urinary diversion by way of a suprapubic catheterization can be applied before surgical treatment [1]. Quoraishi et al. adopted an endoscopic approach with incision of the lip of the diverticulum. However, in these patients can again develop a flap, requiring repeat procedures [17].

Acknowledgements

The author(s) declare that they have no competing interests and financial support.

REFERENCES

1. Paulhac P, Fourcade L, Lesaux N, Alain JL, Colombeau P. Anterior urethral valves and diverticula. *BJU Int.* 2003;92(5):506-9.
2. Rawat J, Khan TR, Singh S, Maletha M, Kureel S. Congenital anterior urethral valves and diverticula: diagnosis and management in six cases. *Afr J Paediatr Surg.* 2009;6(2):102-5.
3. Rafique M. Congenital anterior urethral diverticulum in an adolescent boy with obstructive urinary symptoms. *Int Urol Nephrol.* 2007;39(2):437-40.
4. In: Walsh P, Retik A, Vaughan Jr E, Wein A, eds. *Campbell's Urology*, WB Saunders Elsevier; 8th edition, 2002, pp 2225-2226
5. Barnewolt CE, Paltiel HJ, Lebowitz RL, Kirks DR. *Genitourinary tract*. In: Donald R, Kirks, N, Thorne Griscom (Eds). *Practical pediatric imaging; Diagnostic radiology of infants and children*. Philadelphia, Lippincott-Raven; Third Ed.1998, pp 1009-1170.
6. Dorairajan T. Defects of spongy tissue and congenital diverticula of the penile urethra. *Aust N Z J Surg.* 1963;32(3):209-14.
7. Boissonnat P and Duhamel B. Congenital diverticulum of the anterior urethra associated with aplasia of the abdominal muscles in the male infant. *Br J Urol.* 1962;34:59-69.
8. Huang CJ, Bai JW, Liang RX and Sun N. Congenital anterior urethral valves and diverticulaanalysis of 50 cases. *Ann Acad Med Singapor* 1989;18(6): 665–8.
9. Ortlip SA, Gonzalez R and Williams RD. Diverticula of the male urethra. *J Urol* 1980;124(3): 350–5.
10. Smith SE. Unexpected anterior urethral diverticula. *Clin Radiol.* 1986;37(1):55-8.
11. Bhadury S, Parashari UC, Singh R, Kohli N. MRI in congenital duplication of urethra. *Indian J Radiol Imaging.* 2009;19(3):232-4.
12. Goyal M, Sharma R, Gupta DK, Sharma A, Berry M. Congenital anterior urethral diverticulum: sonographic diagnosis. *J Clin Ultrasound.* 1996;24(9):543-4.
13. Zia-ul-Miraj M. Congenital anterior urethral diverticula in children. *Pediatr Surg Int.* 1999;15(8) 567–9.
14. Heaton BW, Snow BW, Cartwright PC. Repair of urethral diverticulum by plication. *Urology* 1994;44(5):749-52.

15. Tank ES. Anterior urethral valves resulting from congenital urethral diverticula. *Urology* 1987;30(5):467–9
16. Kajbafzadeh A. Congenital urethral anomalies in boys. Part II. *Urol J.* 2005;2(3):125-31.
17. Quoraishi SH, Khan F, Besarani D, Patil K. Congenital anterior urethral diverticulum in a male teenager: a case report and review of the literature. *Case Rep Urol.* 2011;2011:738638.

Access this article online

<http://pediatricurologycasereports.com>

Quick Response Code

