

Research and Reviews: Journal of Dental Sciences

Clinical Management of Ankyloglossia with Lasers.

Shipra Gupta¹, Vandana Gupta^{2*}, and Arun K Garg³

¹Department of Periodontics, Dr. Harvansh Singh Judge Institute of Dental Sciences and Hospital, Panjab University, Chandigarh, India.

²Department of Prosthodontics, Dr. Harvansh Singh Judge Institute of Dental Sciences and Hospital, Panjab University, Chandigarh, India.

³Department of Orthodontics, Dr. Harvansh Singh Judge Institute of Dental Sciences and Hospital, Panjab University, Chandigarh, India.

Research Article

Received: 14/09/2013
Revised: 28/09/2013
Accepted: 02/10/2013

*For Correspondence

Department of Prosthodontics,
Dr. Harvansh Singh Judge
Institute of Dental Sciences and
Hospital, Panjab University,
Chandigarh, India.

Keywords: Ankyloglossia,
Frenectomy, LASER, Kotlow

ABSTRACT

Ankyloglossia, commonly known as tongue tie, is a congenital oral anomaly which may decrease the mobility of the tongue tip. The different surgical techniques for treatment of this condition are frenotomy, frenectomy and frenuloplasty done with scalpels, electrocautery or Light Amplification by Stimulated Emission of Radiation, commonly known as 'LASERS'. There is no sufficient evidence in the literature concerning surgical treatment options for ankyloglossia to favor any one of the three main techniques. Presented here is a case report of a 26-year-old male patient with tongue-tie who reported with the chief complaint of speech difficulty and was treated with frenectomy carried out with LASER under local anesthesia without any post treatment complications.

INTRODUCTION

"Ankyloglossia" is a condition in which the tip of the tongue cannot be protruded beyond the lower incisors because of short frenum linguae. "Ankyloglossia" originates from the Greek words "agkilos" (curved) and "glossa" (tongue). The term free-tongue is defined as the length of tongue from the insertion of the lingual frenum into the base of the tongue to the tip of the tongue. Clinically acceptable normal range of free tongue is greater than 16 mm. Interestingly, the same term is used for very different clinical situations like when the tongue is fused to the floor of the mouth; but has also been used, if the lingual frenum is only short and thick with slight impairment of tongue mobility. Symptoms of Ankyloglossia include: interference with feeding in infants who cannot suck, toddlers who cannot chew, children who cannot lick ice creams, and children and adults who are disadvantaged by their poor speech. It is more common in males.

CLASSIFICATION

Based upon the length of tongue, ankyloglossia can be classified into 4 classes (*Kotlow's assessment*)^[1] which is as follows:

Class I: Mild ankyloglossia: 12 to 16 mm

Class II: Moderate ankyloglossia: 8 to 11 mm

Class III: Severe ankyloglossia: 3 to 7 mm

Class IV: Complete ankyloglossia: Less than 3mm^[2]

Class III and Class IV tongue-tie category should be given special consideration because they severely restrict the tongue's movement. The prevalence of ankyloglossia reported in the literature varies from 0.1% to 10.7%. The prevalence of ankyloglossia has been reported to be higher in neonates (1.72% to 10.7%)^[3] than in children,

adolescents, or adults (0.1% to 2.08%)^[4]. Ankyloglossia was also found associated in cases with some rare syndromes such as X-linked cleft palate syndrome,^[5] Kindler syndrome,^[6] van der Woude syndrome, oral manifestations of which also include congenital adhesion of the jaws, narrow high arched palate, and ankyloglossia.^[7] and Opitz syndrome.^[8] Nevertheless, most ankyloglossias are observed in persons without any other congenital anomalies or diseases.

Tongue tie can be clinically diagnosed by having the patient stick out his tongue. If the patient cannot do so or if when he does so, the tip is held back- looking like the letter W shaped, at the tip rather than a V shape, and then probably the patient is tongue tied. In most of the patients there is difficulty in articulation for consonants and sounds like 's, z, t, d, l, j, zh, ch, th, dg' and specifically to roll out tongue to pronounce word 'r'.^[9]

MANAGEMENT OPTIONS

If there is no feeding difficulty in the infant, it would be best to have a wait-and-see approach since the frenum naturally recedes during the process of an individual's growth between six months and six years of age. After completion of growth and also during infancy, if the individuals have a history of speech, feeding, or mechanical/social difficulties; surgical intervention should be carried out. Therefore, surgery should be considered at any age depending on the patient's history of speech, feeding, or mechanical/social difficulties.

Surgical Techniques: Most commonly used surgical techniques for the therapy of tongue-ties can be classified into three procedures:

- **Frenotomy** is a simple cutting of the frenum.
- **Frenectomy** is defined as complete excision, i.e., removal of the whole frenum.
- **Frenuloplasty** involves various methods to release the tongue-tie and correct the anatomic situation.

These surgical procedures can be done with scalpels, scissors, electro-cautery or LASERS. Out of all these methods of performing these surgical procedures, surgical procedures carried out with LASER Shave been found to be very effective and minimally invasive procedure with immediate improvement in speech. Many LASERS are available including Er:YAG, CO₂, and Nd:YAG.^[10] Each of these LASERS exhibits specific properties depending on their position in the electromagnetic spectrum.

CASE REPORT

A 26years old male patient reported to the Department of Periodontics, Dr. Harvansh Singh Judge Institute of Dental Sciences and Hospital, Panjab University, Chandigarh (India); with the chief complaint of 'not having clarity of speech and difficulty in protruding his tongue completely. While history taking, the patient revealed that as a consequence, he was having a severe emotional and social stigma perceived by the patient mainly because of this difficulty in pronunciation of certain words. Medical history was not contributory. On oral examination, patient was found to have thick, short fibrotic lingual frenum with a restrictive tongue movement. It was observed that when the mouth was open, it was impossible for the patient to touch the roof of the mouth with the tip of tongue. After thorough examination, it was confirmed that the patient had Class III ankyloglossia (Figure 1) and frenectomy of the lingual frenum was planned with diode LASER970nm (Figure 2) with maximum power output of 4Watt, was planned. After taking informed consent, local anaesthesia was administered with 2% Lignocaine Hydrochloride and 1:80000 Adrenaline. The patient was asked to retrace the tongue to the back of the palate which would make the lingual frenum prominent and also helps determine the extent of frenum. As the frenum became prominent, a haemostat was used to clamp it. Using the diode LASER with the settings of wavelength of 970nm, power 4 Watt in continuous contact mode the frenum was released along the sides of haemostat (Figure 3). A rhomboidal shaped defect was observed following the excision (Figure 4). The favorable outcome of the procedure was apparent immediately and the extent of the release could be accessed during the intervention itself (Figure 5). Post surgical instructions were given along with a course of NSAIDs for three days. The following exercises ^[11] were advised:

- 1] To stretch the tongue up towards the nose, then down towards the chin and repeat.
- 2] To open the mouth widely and touch the upper central incisors with the tongue with mouth still open.
- 3] To close the mouth and poke it into left and right cheek to make a lump for 3-5 minutes once or twice daily.

Post operative follow up:

The post operative period was uneventful. The routine follow up at *four weeks* showed an improved tongue protrusion and normal speech.

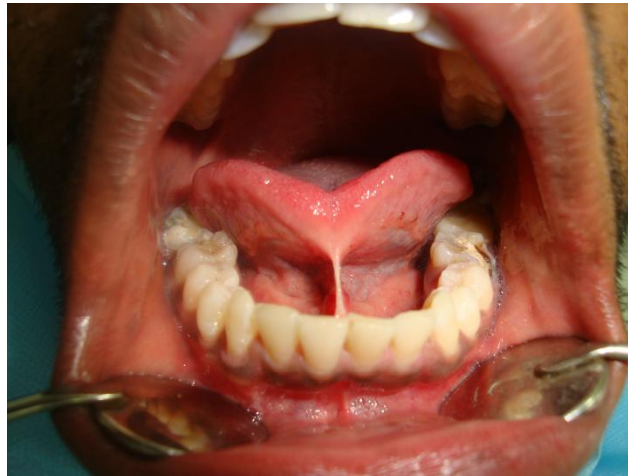

Figure 1: Pre Operative



Figure 2: Diode Laser

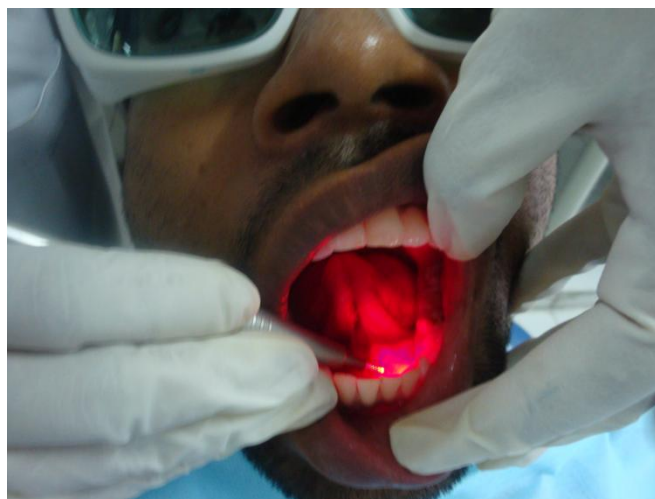

Figure 3: Excision with Lasers

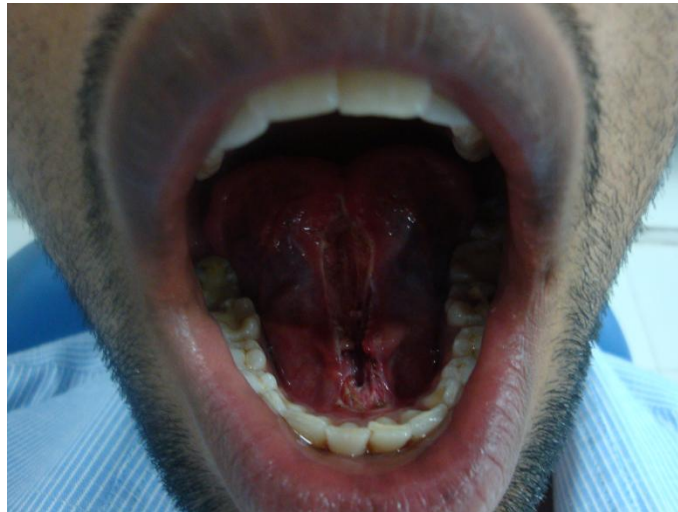

Figure 4: Immediately After Excision

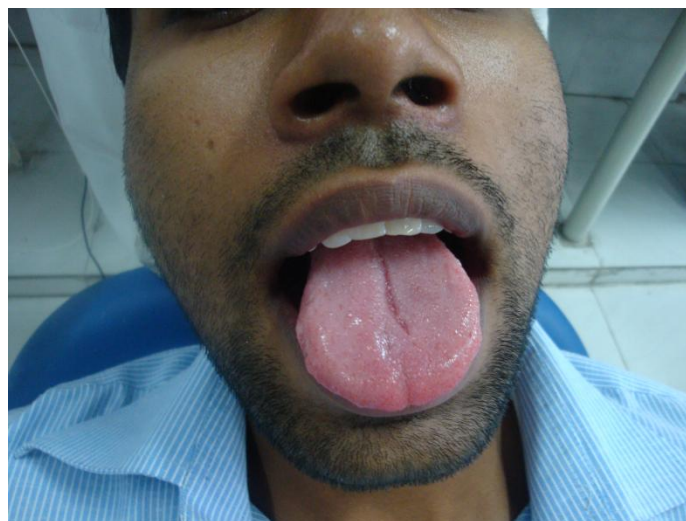


Figure 5: Post-Operative Showing Marked Protrusion of the Tongue

DISCUSSION

Full range of tongue mobility is required to form sounds correctly. If mobility of the tongue is reduced, sounds may slightly, moderately or highly deviate from proper ones. Serious deviations in articulate structure of sounds (such as non-vibrating front part of the tongue in the /r/ phoneme) are easy to notice since they change phoneme structure of the sound. Slight deviations (e.g. non-vibrational or non-mediumistic action of the tongue) may be unnoticed because speech is still comprehensible although it is formed with compensatory positions and movements of breathing, phonetic and articulation apparatus. One of the factors that restrict (to a slight, average or high degree) tongue mobility is the short frenum [12].

The advantage of LASER surgery over traditional surgical approaches includes higher precision when compared to surgical tools which result in less pain, bleeding, swelling and scarring. The procedure is not time consuming, easy to perform in an outpatient setup and no sutures are required which decreases the risk of post operative infection.[13] The authors are of strong opinion that though this procedure seems promising, but still a lot of research and clinical follow ups are required to come to any definitive conclusion.

REFERENCES

1. Kotlow LA. Ankyloglossia (tongue-tie): A diagnostic and treatment quandary. *Quintessence Int.* 1999; 30: 259-62.
2. Suter VG, Bornstein MM. Ankyloglossia: Facts and myths in diagnosis and treatment. *J Periodontol.* 2009;80:1204-19.
3. Ballard JL, Auer CE, Khoury JC. Ankyloglossia: Assessment, incidence, and effect of frenuloplasty on the breastfeeding dyad. *Pediatrics.* 2002;110:e63.
4. GarcíaPola MJ, González García M, García Martín JM, Gallas M, Seoane Lestón J. A study of pathology associated with short lingual frenum. *ASDC J Dent Child.* 2002;69:59-62.
5. Moore GE, Ivens A, Chambers J, Farrall M, Williamson R, Page DC, et al. Linkage of an X-chromosome cleft palate gene. *Nature.* 1987;326:91- 92.
6. Hacham-Zadeh S, Garfunkel AA, Opitz JM, Reynolds JF. Kindler syndrome in two related Kurdish families. *Am J Med Genet.* 1985;20:43- 48.
7. Soni R, Vivek R, Srivastava A, Singh A, Srivastava S, Chaturvedi TP. Van der Woude Syndrome Associated with Hypodontia: A Rare Clinical Entity; *Case Reports in Dentistry* 2012. doi:10.1155/2012/283946.
8. Brooks JK, Leonard CO, Coccaro PJ Jr. Opitz (BBB/G) syndrome: Oral manifestations. *Am J Med Genet.* 1992; 43:595-601.
9. Trott JR, Love B. An analysis of localized gingival recession in 766 Winnipeg High School students. *Dent Pract Dent Rec.* 1966;6: 209-13.
10. Morawala A, Musale P, Chunnawala Y, Gupta A, Hegde V. Laser treatment for ankyloglossia (tongue tie). *Solaze J Laser Dent.* 2011;5:18-20.
11. Jain S, Siddiqui N, Raisinhani J. Laser lingual frenectomy-A Case Report. *Solaze J Laser Dent* 2010;4:33-35.
12. Ostapiuk B. tongue mobility in ankyloglossia with regard to articulation. *J Indian Soc Periodontol.* 2011; 15: 270-272.
13. Makkar S, Makkar M, Dang R. LASERS- A preferred treatment option over conventional for Labial Frenectomy. *Solaze J Laser Dent.* 2010; 4: 22-24.