

## Stigmas in Orthodontics: A Review.

V Madhusudhan\*, Saqib Hassan, Sridharan K, Srinivas H, and Mahobia Yogesh.

Department of Orthodontic and Dentofacial Orthopedic, Sri Siddhartha Dental College and Hospital, Tumkur, Karnataka, India.

### Review Article

Received: 06/10/2013  
Revised: 22/10/2013  
Accepted: 03/11/2013

#### \*For Correspondence

Department of Orthodontic and Dentofacial Orthopedic, Sri Siddhartha Dental College and Hospital, Tumkur, Karnataka, India.  
Moblie: +91 9844327035

**Keywords:** stigma, othodontics, decalcification, root resorption

#### ABSTRACT

Like any other branch of medicine or dentistry, orthodontic treatment is not without potential risks. Each year number of patients seek orthodontic treatment for correction of poor esthetic, abnormal functions and speech. An orthodontist always wants that treatment should be accurate for each patient without discomforts and pain. Even after certain risks are associated with orthodontic treatment which may be either iatrogenic or inherent. The purpose of this article is to enlightens various risks and complications encountered in orthodontic practice and also describe their managements.

#### INTRODUCTION

Orthodontic treatment can improve mastication, speech and appearance, as well as overall health, comfort, and self-esteem. However, like many other interventions, orthodontic treatment has inherent risks and complications. Thus, if correcting malocclusion is to be of benefit, the advantages it offers should outweigh any possible damage [1]. The psychological aspects of orthodontic treatment should be given due consideration and must not be overlooked. Patient selection always plays a vital role in minimizing risks. Moreover, clinicians should be vigilant in assessing and monitoring every aspect of the patient during and after treatment to achieve an uneventful, secure, and successful final result [2].

#### Decalcification

Patients undergoing orthodontic therapy are at advanced risk for enamel decalcification [3]. The presence of a fixed appliance predisposes to plaque accumulation as tooth cleaning around the components of the appliance is more difficult. Decalcification during treatment with fixed appliances is a real risk, with a reported prevalence of between 2 and 96 per cent. Wisth and Nord [4] reported that daily rinsing with 0.05% NaF solution provided added protection for orthodontic patients who were also brushing 3 times yearly with 0.2% NaF solution. Muhler [5] reported a significant decrease in decalcification in orthodontic patients who received a topical application of SnF prior to band placement and used a SnF dentifrice throughout treatment.

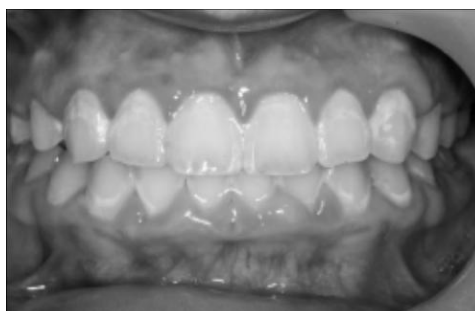

Figure 1

## Root Resorption

Resorption of root occurs as a consequence of tooth movement. On average 1mm of root length may resorb during conventional 2 years period of treatment. Resorption mainly occur on apical and lateral surface [6]. upper central incisors are more prone for resorption. Accurate radiograph in each 6 month should be taken. Light force must be used for susceptible patients [7].

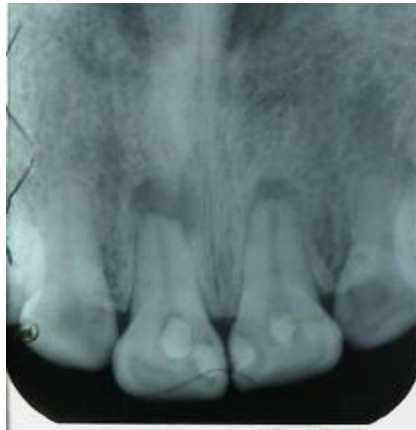

Figure 2

## Periodontal Tissue

Periodontal tissues are in risk from start of treatment to end of treatment. If placement of separator is more gingivally it may cause gingivitis. (Fig- 3a,3b) Sometime separator may go more inside to gingival tissue and patient may think that separator is missing which may lead to more damage to periodontal tissue. Gingival margin of band should be smooth to avoid soft tissue irritation. Alveolar bone loss occurs more often in orthodontic patients than in reference subjects, the difference being small but significant [8]. In most patients this is minimal, but if oral hygiene is poor, particularly in an individual susceptible to periodontal disease, more marked loss may occur. Removable appliances may also be associated with gingival inflammation, particularly of the palatal tissues, in the presence of poor oral hygiene.

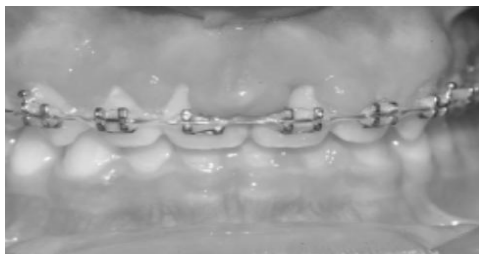
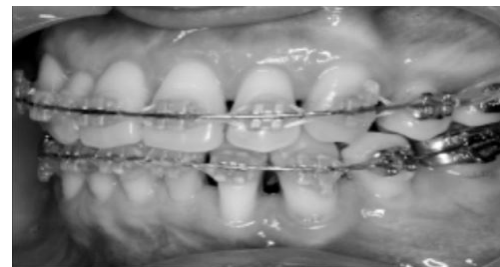

Figure 3 (a)



(b)

Advise for IOPA when suspect band is missing. Proper selection of preformed band and smooth margin of chair side prepared band can avoid such kind of problem.

## Irritation to Lips and Cheeks

New braces may irritate the patient mouth and some time inserted arch wire may protrude or bowed towards cheek mucosa and cause irritation. (fig- 4 a ,4c) Non - medicinal relief wax makes an excellent buffer between metal and mouth and relieve irritation. ( fig- 4b)

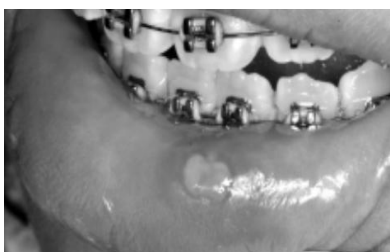
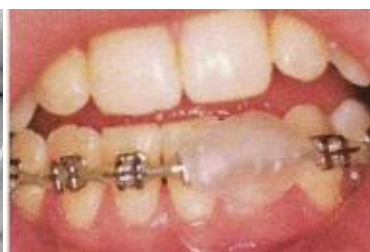
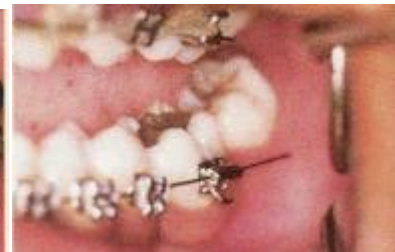Figure 4 (a)



(b)



(c)

Extraoral appliances cause both extra- and intra-oral adverse reactions. Reports of injuries with extraoral appliances have shown that out of the nearly 5000 orthodontists (responsible for treating approximately 4.5 million patients), 4% reported that headgear injury had ensued in one or more of their patients ; 40% were extraoral injuries [9].

### Allergy

Allergic reactions are not very common in orthodontics. Cases have been detected of nickel hypersensitivity to orthodontic wire. (fig- 5) Contacts with face bow and headgear strap may also cause allergic reaction. Use of sticking plaster over the areas in contact with the skin is sufficient to relieve symptoms [10].

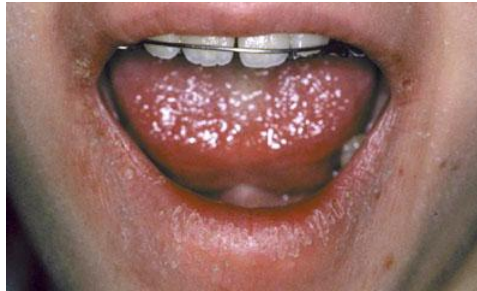

Figure 5

### Tempomandibular Joint Dysfunction

In the literature, much attention has been focused on the relationship between temporomandibular dysfunction (TMD) and orthodontic treatment. Whilst TMD is common in the general population irrespective of orthodontic treatment, there is no evidence to support the theory that orthodontic treatment causes TMD or cures it [11]. Pre-existing TMD should be recorded, and the patient advised that treatment will not predictably improve their condition and that some may suffer increased symptoms. Conservative treatment should be directed at eliminating discomfort, occlusal disharmony and joint noises and reassuring the patient. Other forms of standard treatment (e.g. soft diet, jaw exercises) may also be indicated.

### Accidental Ingestion of Appliances

Few cases of accidental ingestion of appliance like broken quad helix , transpalatal arch , twin block and orthodontic wire were found. (fig -6a, 6b ) [12,13,14]. Continuous monitoring by repeated radiograph and in severe cases surgical intervention is the choice of treatment .Inhalation cause partial or complete airway obstruction. Coughing, Heimlich manoeuvre and in sever case referral to respiratory specialist should be made. Orthodontist should always check for missing appliance in each visit of patient.

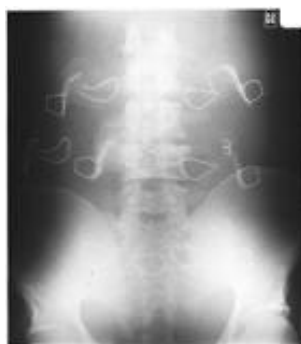
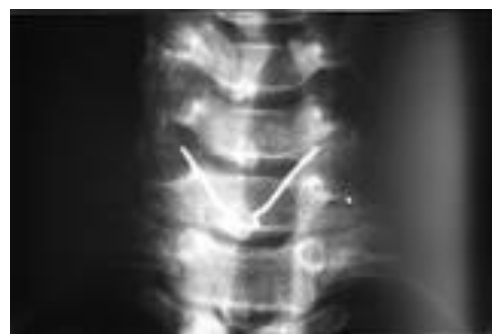
Figure 6 (a)



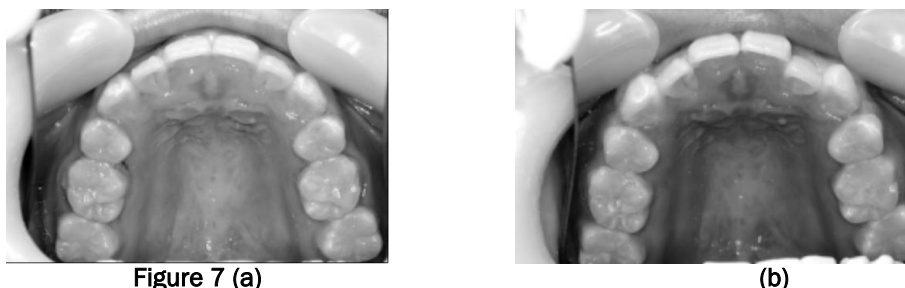
(b)

### Profile change

Due to improper torque control in anterior segment and excessive expansion of dental arch in antero-posterior direction increase the excessive fullness of lip which may cause unsatisfactory profile. Careful planning and adequate communication with patients helps to reduce the chance of the complaints. A review concluded that orthodontics does not affect facial profile adversely, whilst also highlighting areas where planning is crucial [15]. Soft tissue changes also occur naturally with age, regardless of orthodontic intervention. Proper diagnosis should take account of skeletal form, tooth position, and soft tissue form so as to negate any detrimental effect on profile due to treatment mechanics [16]. Ultimately, the patient's expectation of the finished profile dictates the choice of treatment.

## Relapse

Orthodontic treatment results are potential for instability and relapse. (fig-6a ,6b) The initial 6-month post-treatment is important, as it may take 4 to 6 months for the periodontal ligament and supporting bone to complete re-organization [17,18]. That is why teeth have a stronger tendency to move immediately after orthodontic treatment and the effect diminishes gradually after the alveolar bone and the periodontium return to their normal pattern. Most relapses are due to inadequate wearing of retainers and inadequate monitoring. Proper use of retainers can help to reduce post-treatment relapse.



## CONCLUSION

There are several sources of potential iatrogenic damage due to orthodontic treatment. When properly performed, severe damage is very rare. Each individual should be assessed for potential risks. Patient have more confidence in an orthodontist who have ability to communicate care and compassion . Patient should be aware of all the orthodontic procedure and should be explained. This helps to bring a psychological bond between patient and an orthodontist which reduces the patient anxiety and fear.

## REFERENCES

1. Shaw WC, O'Brien KD, Richmond S, Brook P. Quality control in orthodontics: risk/benefit considerations. *Br Dent J.* 1991;170:33-7.
2. Paul Yun-Wah Lau, Ricky Wing-Kit Wong. Risk and complication in orthodontic treatment. *Hong Kong Dental J.* 2006;3:15-22.
3. Shannon IL. Caries Risk in Teeth with Orthodontic Bands. *J Acad Gen Dent.* 1972;20:24-28.
4. Wisth PJ, Nord A. Caries Experience in Orthodontically Treated Individuals. *Angle Orthod.* 1977; 47:59-64.
5. Muhler JC. Dental Caries-orthodontic Appliances-SnF2. *J Dent Child.* 1970;37:218-221.
6. Brezniak N, Wasserstein A. Root resorption after orthodontic treatment: Part 1. Literature review. *Am J Orthod Dentofacial Orthop.* 1993;103:62-6.
7. Hollender L, Ronnerman A, Thilander B. Root resorption, marginal bone support and clinical crown length in orthodontically treated patients. *Eur J Orthod.* 1980;2:197-205.
8. Alstad S, Zachrisson BU. Longitudinal study of periodontal condition associated with orthodontic treatment in adolescents. *Am J Orthod.* 1979;76:277-86.
9. Postlethwaite K. :The range and effectiveness of safety headgear products. *Eur J Orthod.* 1989;11:228-34.
10. Allergic reaction to orthodontic wire: report of case. *J Am Dent Assoc.* 1989; 118(4):449-50.
11. Uther F. Orthodontics and the temporomandibular joint: where are we now? Part 1. Orthodontic treatment and temporomandibular disorders. *Angle Orthod.* 1998;68:295-30.
12. Farrell G. Hinkle. Calif. Ingested retainer. *Am J Orthoo Dentofac Ortho.* 1987;92:48-9
13. TM, Milton Hearing SD, Ireland AJ. Ingested foreign bodies associated with orthodontic treatment: report of three cases and review of ingestion/aspiration incident management. *Br Dent J.* 2001; 190: 592-96.
14. HM Abdel Kader. Broken orthodontic transpalatal arch wire stuck to the thorat of orthodontic patient: is it strange . *J Orthodont.* 2003;30;11
15. Di Biase AT, Sandler PJ. Does orthodontics damage faces? *Dent Update.* 2001;28:98-102.
16. Ackerman JL, Proffit WR. Soft tissue limitations in orthodontics: treatment planning guidelines. *Angle Orthod.* 1997;67:327-36.
17. Reitan K. : Principles of retention and avoidance of posttreatment relapse. *Am J Orthod.* 1969;55:776-90.
18. Reitan K. : Tissue rearrangement during the retention of orthodontically rotated teeth. *Angle Orthod.* 1959;29:105-1