

Case Report

Endoscopic Calcaneoplasty for Haglund's deformity

S.Appala Raju¹, M Vijay Bhushanam, G Rajasekhar Rao, M Venkateswara Rao

Abstract : Endoscopic calcaneoplasty is a minimally invasive technique for resection of inflamed retrocalcaneal bursa and resection of abnormal prominence over the postero superior part of calcaneum. In this report, we describe the treatment of Haglund's deformity by minimally invasive method to overcome wound healing problems. It also offers an advantage of shorter recovery time and proved cosmesis

Key Words : Haglund's deformity, calcaneoplasty, endoscopic surgery,

Introduction

In 1928, Swedish orthopedic surgeon Patrick Haglund described a patient with a painful hindfoot caused by a prominent posterosuperior aspect of the calcaneus in conjunction with a sharp rigid heel counter¹. The term Haglund's disease, deformity and syndrome are used interchangeably.

Haglund's disease is defined as a complex of symptoms involving the superolateral calcaneal prominence, retrocalcaneal bursitis and adventitious Achilles tendon bursitis^{2,3,4}. On physical examination, a bony prominence can be palpated at this location. This entity is described by a variety of different names such as 'pump-bump'⁵, 'cucumber heel'⁶, 'high-prow heels'⁷ and 'winter heel'⁶. Non-surgical treatment is always recommended first. If pain persists with conservative treatment and a bony exostosis is confirmed by imaging, surgery is considered. The conventional surgical treatment is an open resection^{3,4}. Recently, several authors reported good results with an endoscopic technique^{4, 8, 9, 10, 11}

Case History Mrs K M , female 38 yrs of age, has presented to the outpatient department of orthopaedics, Maharajah's Institute of Medical Sciences with complaints of pain in the left heel since 2 years for which she underwent conservative management with non-steroidal anti-inflammatory medications and physiotherapy without any relief. Clinical examination showed swelling and tenderness over the posterosuperior part of left heel (figure 1).

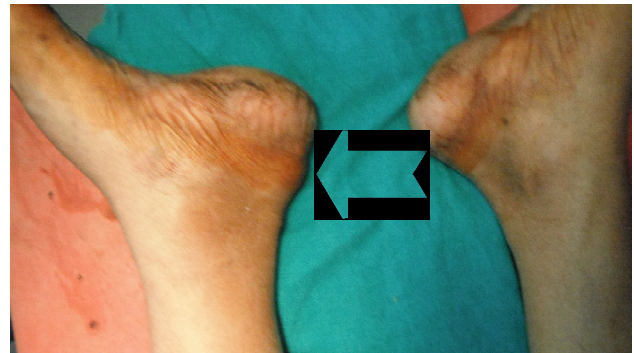


Fig 1 clinical photograph showing left sided heel bump (red arrow)

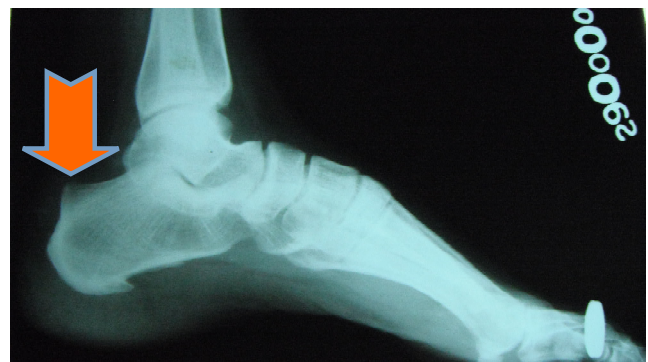

Figure 2 : Pre-op x-ray showing bony overgrowth

X-Ray of the foot showed postero-superior bony bump, suggestive of Haglund's deformity (figure2).

Surgical technique : The patient was operated under general anaesthesia with tourniquet control over the thigh. The patient was placed in prone position with the ankle hanging freely over the edge of the operating table to allow full range of movement during the procedure. A support is placed below the leg for maneuverability with instruments (figure3).

¹Assistant Professor, Department of Orthopedics, Maharajahs Institute of Medical Sciences, Vizianagaram-535217, AP.

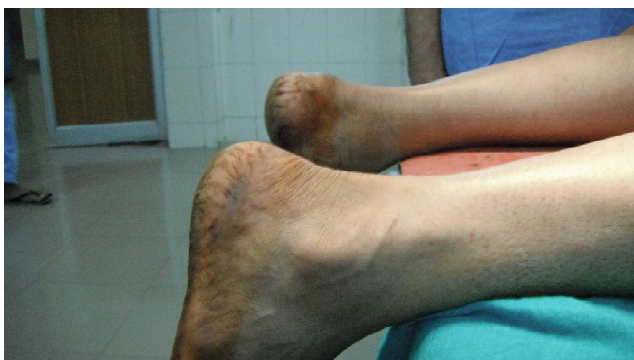

Figure 3 position on operation table

Two portals were placed adjacent to the Achilles tendon on either side. Initially a 4-mm scope is placed through the lateral portal. With a 4-mm synovial resector the soft tissue was debrided through the medial portal on the bone side and tendon side. The Achilles tendon was protected throughout the procedure by keeping the closed end of the shaver against the tendon. The bone was resected with a mastoid burr. Both the resector and scope were interchangeably used through both the portals. After resection, the Achilles tendon was inspected through scope and confirmed to be intact. At the end of the surgery, Plantarflexion of ankle was found to be satisfactory by squeeze test. Portals were closed with 2-0 ethilon (figure4)

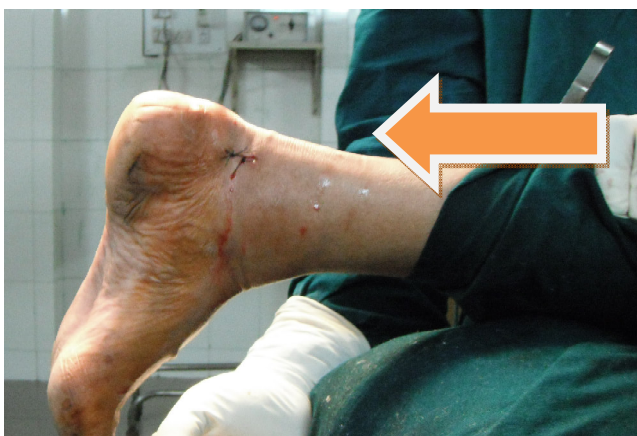

Figure 4 showing arthroscopic closure

Wound was dressed and a compression bandage was applied.

Post operative management: Post operative period was uneventful. Patient received volar slab upto below knee extent with ankle in plantarflexion. The patient was trained for nonweight bearing mobilization till 2 weeks, and later changed to neutral position of ankle and was trained for weight bearing. By 6 weeks she returned to normal activity. X-ray showed good clearance for Achilles tendon and removal of bony swelling (Figure 5 and 6)

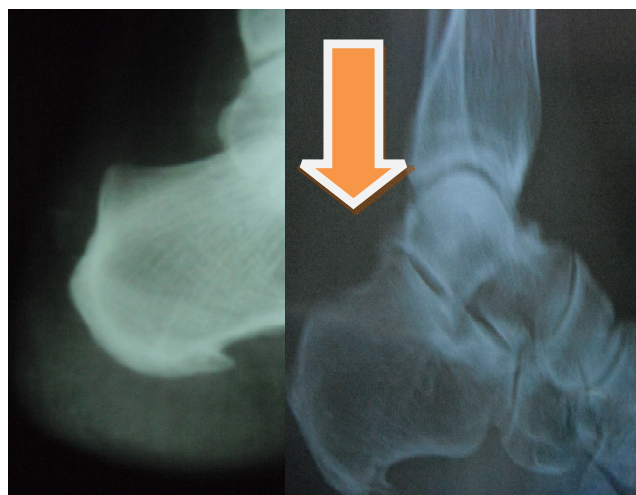


Figure 5 (left) Pre-operative x-ray showing Haglund bump and figure 6 (right) showing Post-op x-ray with removed bony bump shown by arrow head

Using the Oglive-Harris¹² score after 6 months she had excellent results (AOFAS score 98).

Discussion

In summary, whether the operation is performed by endoscopic or open surgery, enough bone has to be removed to prevent impingement between the calcaneus and Achilles tendon. The endoscopic calcaneoplasty is an excellent alternative to the open method, as it has several advantages like low morbidity, excellent scar healing, a short recovery time and quick resumption to normal activities including sports. The functional recovery is excellent and compares favourably to open method. Thus endoscopic calcaneoplasty has a definite role in the management of Haglund's deformity.

References

1. Haglund P. Beitrag zur Klinik der Achillessehne. Zeitschr Orthop Chir 1928; 49:49-58.
2. Heneghan MA, Pavlov H (1984) The Haglund painful heel syndrome. Experimental Investigation of cause and therapeutic implications. Clin Orthop 187:228-234
3. Jerosch J, Nasef NM (2003) Endoscopic calcaneoplasty—rationale, surgical technique, and early results: a preliminary report. Knee Surg Sports Traumatol Arthrosc 11:190-195
4. Van Dijk CN, van Dyk E, Scholten PE, Kort NP (2001) Endoscopic calcaneoplasty. Am J Sports Med 29:185-189

5. Dickinson PH, Coutts MB, Woodward EP, Handler D. Tendo Achillis bursitis. Report of twenty-one cases. *J Bone Joint Surg Am* 1966; 48(1): 77-81.
6. Fowler A. Abnormalities of the calcaneus a cause of painful heel: its diagnosis and operative treatment. *Br J Surg* 1945; 32: 494-498.
7. Stephens MM. Haglund's deformity and retrocalcaneal bursitis. *Orthop Clin North Am* 1994; 25(1): 41-46.
8. Jerosch J, Schunck J, Sokkar SH (2007) Endoscopic calcaneoplasty(ECP) as a surgical treatment of Haglund's syndrome. *Knee Surg Sports Traumatol Arthrosc* 15:927-934
9. Leitze Z, Sella E, Aversa J (2003) Endoscopic decompression of the retrocalcaneal space. *J Bone Joint Surg Am* 85:1488-1496
10. Morag G, Maman E, Arbel R (2003) Endoscopic treatment of hindfoot pathology. *Arthroscopy* 19(2):E13
11. Van Dijk CN, Scholten PE, Krips R (2000) A 2-portal endoscopic approach for diagnosis and treatment of posterior ankle pathology. *Arthroscopy* 16:871-876.
12. Ogilvie-Harris DJ, Mahomed N, Demaziere A. Anterior impingement of the ankle treated by arthroscopic removal of bony spurs. *J Bone Joint Surg Br* 1993; 75(3): 437-440.

Financial Support : Declared None

Conflict of Interest : Declared None