

Natal Teeth – Report of Two Cases

Nalam Sai Gautam^{1*} N. Radhika Gautham²¹Reader, Department of Pedodontics and Preventive Dentistry, GITAM Dental College, Rushikonda, Visakhapatnam, Andhra Pradesh, India.²Assistant Professor, Department of Public Health Dentistry, SIBAR Institute of Dental Sciences, Takellapadu, Guntur, Andhra Pradesh, India.

ABSTRACT

Background: Presence of Natal and neonatal teeth are a rare event in the oral cavity, which may interfere with breast feeding & may lead to numerous complications. The decision to keep or to extract these teeth should be evaluated in each case, keeping in mind the scientific knowledge, clinical common sense and parental opinion. A case of immature natal maxillary anterior teeth and a case of natal mandibular anterior tooth are reported.

Keywords: Natal Teeth, Maxilla, Mandible.

INTRODUCTION

Developmental milestones are anxiously awaited by every parent, particularly in the first year of their child's life. One such milestone is the eruption of their child's first tooth. Any untoward incident in this regard may be a cause of worry for the parents, more so, if it is a natal tooth which compromises in child's feeding¹. Natal and neonatal teeth are most commonly a part of deciduous dentition and erupt in the same position as that of deciduous teeth in the arch². According to Massler and Savara³, natal teeth are those teeth that are present at the time of birth and neonatal teeth are those that erupt within 30 days of life. Teeth erupting beyond the natal period of thirty days (i.e. erupting within 1-3.5 months) are usually referred to as early infancy teeth⁴. First deciduous tooth erupts in the oral cavity at about six-months of age⁵. Terms such as congenital teeth, foetal teeth, pre-deciduous teeth, premature teeth, precociously erupted teeth or dentitia praecox have been used to

refer this condition⁶. Natal and neonatal teeth erupt more commonly in the mandibular anterior region than in maxillary region. Natal and neonatal teeth erupt 85% in mandibular

incisor region, 11% in maxillary incisor region, 3% in mandibular canine region and 1% in maxillary canine and molar region⁷. Similarly, Kates et al⁸ in a study of 18,155 infants reported that all of 61 observed natal or neonatal teeth were mandibular central incisors. The prevalence ranges from 1:700 to 1:30,000 depending on the type of the study⁹. Among the 38 infants so affected, 61% had a pair of teeth. The exact etiology is unknown but it is thought to be due to infection, febrile states, trauma, malnutrition, superficial portion of the tooth germ, hormonal stimulation and maternal exposure to environmental toxins¹⁰.

CASE REPORT 1

A 40 day old female baby was referred to the department of Pedodontics with the chief complaint of two teeth in upper anterior region since birth. The baby appeared to be normal except for the two teeth in the upper arch. Maternal medical and social histories disclosed no significant information. There were no abnormal findings in routine examination. On intraoral examination, it was seen that there were two erupted tooth like structures in the anterior maxilla (Figure 1). The crown size and the appearance of the gingiva seemed to be normal. The natal teeth were similar in dimensions as compared to the corresponding



Received: Feb. 21, 2014; Accepted: Apr. 23, 2014

*Correspondence: Dr. Nalam Sai Gautam

Department of Pedodontics and Preventive Dentistry, GITAM Dental College, Rushikonda, Visakhapatnam, Andhra Pradesh, India.

E-mail: gautham316@rediffmail.com

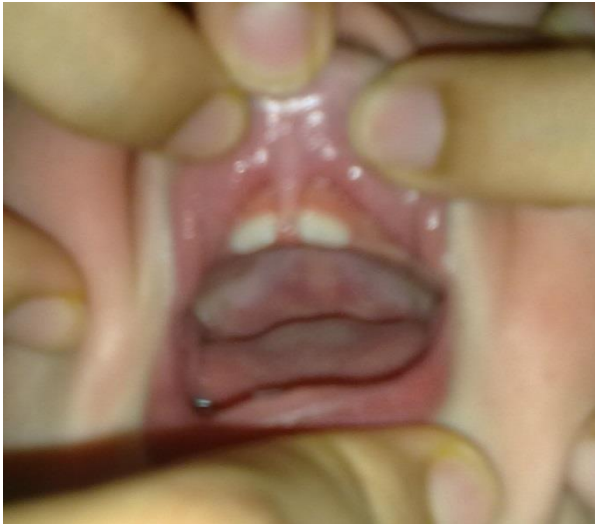


Fig 1: Natal teeth in maxillary anterior region.

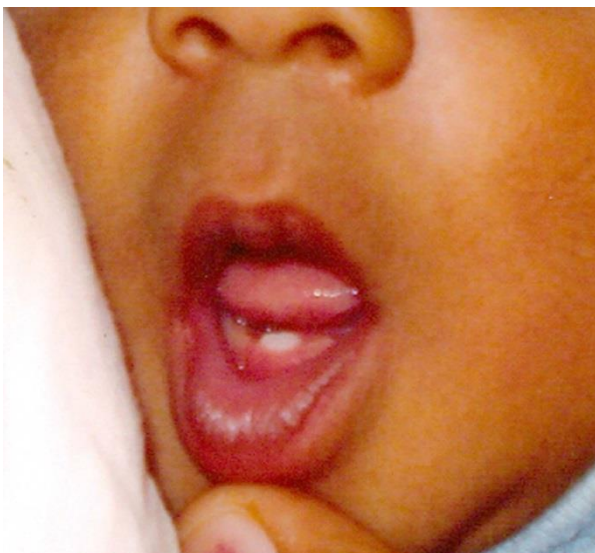


Fig 2: Natal tooth in mandibular anterior region.

primary teeth. On further examination, it was found that maxillary natal teeth had grade I mobility and there were chances of aspiration. The baby seemed to be uncomfortable and mouth was kept open during feeding and hence was spoon fed. Due to lack of co-operation from the baby, intraoral radiographs could not be taken. It was decided to extract the mobile natal teeth for two reasons: a) to prevent aspiration and b) to ensure proper feed for the baby.

The parents were explained the process in detail about the need for removal of those mobile teeth and the mother was asked to feed the baby prior to extraction. All the necessary precautions were taken. The maxillary natal teeth were

extracted. On recall the baby appeared to be much more contented and the mother reported that she was feeding normally.

CASE REPORT 2

A 2 weeks old female baby was referred to the Department of Pedodontics with the chief complaint of tooth present in lower anterior region since birth. Maternal medical and social histories disclosed no significant information. There were no abnormal findings in routine examination. On intraoral examination, a tooth like structure was seen in the mandibular anterior region with grade III mobility (Figure 2). The tooth was extracted because of difficulty in breast feeding and fear of aspiration due to its severe mobility. The extracted tooth had a crown but was devoid of root. On recall it was reported by parents that, she was feeding normally without any post-operative complications.

DISCUSSION

For past hundreds of years many cases of infants born with natal and neonatal teeth have been reported in the dental literature. The etiology of natal teeth is still unknown. Various investigators have postulated their views regarding the etiology of natal teeth. Hyperactivity of osteoblastic cells within the tooth germs during the initiation or proliferation stage of development of tooth may be one of the reason¹¹. Other reasons attributed are superior placement of the tooth germ¹². Massler and Savara³ found first order relatives with natal or neonatal teeth in 10 of 24 cases. Congenital conditions associated with premature teeth include Ellis-van Creveld syndrome¹³, Hallermann-Streiff syndrome¹³, Pierre Robin anomaly, adrenogenital syndrome, cleft palate and rickets¹⁴, craniofacial dysostosis¹⁵. In the present cases, no such syndromes were evident.

Complications related to natal and neonatal teeth include discomfort during suckling, irritation and trauma to infants' tongue, sublingual ulceration (Riga-Fede disease), laceration of the mother's breast and risk of aspiration of the mobile teeth¹⁶. Prolonged gingival irritation from natal or neonatal teeth may cause localized inflammation of the gingiva or fibrous hyperplasia¹⁷.

Classification

Spouge and Feasby¹⁶ have suggested that clinically, natal and neonatal teeth are classified according to their degree of maturity

1. A mature natal or neonatal tooth is one which is nearly or fully developed and has relatively good prognosis for maintenance.
2. The term immature natal or neonatal tooth, on the other hand, refers to a tooth with incomplete or substandard structure; it has a poor prognosis.

The appearance of each natal tooth into the oral cavity can be classified into four categories as the teeth emerge into the oral cavity¹⁸.

1. Shell-shaped crown, poorly fixed to the alveolus by gingival tissue and absence of a root.
2. Solid crown, poorly fixed to the alveolus by gingival tissue and little or no root.
3. Eruption of the incisal margin of the crown through the gingival tissues.
4. Edema of gingival tissue with an unerupted but palpable tooth.

Management

The risks of dislocation and consequent aspiration of the mobile teeth, in addition to traumatic injury to the baby's tongue and/or to the mother's breast, have been described as reasons for the extraction¹⁹. In both the cases the extraction was carried out as the children were more than 10 days old and the vitaminK/prothrombin level and IgG level are that of adult level by this time, which ruled out chances of excessive hemorrhage. If the child is below 10 days of age, prophylactic administration of vitamin K (0.5-1.0mg, IM) is advocated before and after extraction, since vitamin K is essential for the production of prothrombin in the liver as there could be risk of haemorrhage²⁰. Other management options are smoothening of the incisal margin for non-mobile teeth, by covering the incisal margins with composite resin or Glass Ionomer Cement, feeding splint¹. According to Kates et al⁸ if natal teeth survive beyond 4 months, they have a good prognosis.

CONFLICT OF INTEREST

No potential conflict of interest relevant to this article was reported.

REFERENCES

1. Sogi S, Hugar SM, Patil S, Kumar S. Multiple natal teeth: A rare case report. *Indian J Dent Res* 2011;22:169-71
2. Firoza Samadi, Prashant Babaji, Sonali Saha, Ashish Katiyar, Swati Chowdhry. Natal Teeth: Report of Two Cases and Review of Literature. *International Journal of Oral & Maxillofacial Pathology*; 2011;2(1):33-6.
3. Massler M, Savara BS. Natal and neonatal teeth: A review of 24 cases reported in the literature. *J Pediatr* 1950;36:349-59.
4. Anegundi RT, Sudha P, Kaveri H, Sadanand K. Natal and neonatal teeth: a report of 4 cases. *J Indian Soc Pedo Prev Dent* 2002;20(3):86-92.
5. Alexander KCL, William LMR. Natal Teeth: A Review. *J Natl Med Assoc* 2006;98(2):226-8.
6. Portela MB, Damasceno L, Primo LG. Unusual case of multiple natal teeth. *J Clin Pediatr Dent* 2004;29(1):37-40.
7. Kamboj M, Cougule R. Neonatal Tooth—How Dangerous Can it Be? *J Clin Pediatr Dent* 2009;34(1):59-60.
8. Kates GA, Needleman HL, Holmes LB. Natal and neonatal teeth: a clinical study. *J Am Dent Assoc* 1984;109:441-3.
9. Rao RS, Mathad SV. Natal teeth: Case report and review of literature. *J Maxillofac Path* 2009;13(1):41-6.
10. Leung AKC, Robson WLM. Natal teeth: A Review. *J Natl Med Assoc* 2006;98(2):226-8.
11. Zhu J, Kind D. Natal and neonatal teeth. *J Dent Child* 1995;62:123-8.
12. King NM, Lee AMP: Prematurely erupted teeth in newborn infants. *J Pediatr* 1989;114:807-9.
13. Chow MH: Natal and neonatal teeth. *J Am Dent Assoc* 1980;100:215-6.

14. Leung AK. Natal teeth. *Am J Dis Child* 1986;140:249-51.
15. Ohishi M, Murakami E, Haita T, Naruse T, Sugino M, Inomata H. Hallermann-Streiff syndrome and its oral implications. *ASDC J Dent Child* 1986;53:32-7.
16. Spouge JD, Feasby WH. Erupted teeth in new born. *Oral Surg Oral Med Oral Pathol* 1966;22:198-208.
17. Singh S, Subbba Reddy VV, Dhananjaya G, Patil R. Reactive fibrous hyperplasia associated with a natal tooth: A case report. *J Indian Soc Pedo Prev Dent* 2004;22:183-6.
18. Nevas RMA, Menoza MGM, Leonardo MR, Silva RAB, Herrera Hw, Herrera HP. Congenital eruption of cyst: A case report. *Braz dent J* 2010;21(3):259-61.
19. Chawla HS. Management of natal/neonatal/early infancy teeth. *J Indian Soc Pedod Prev Dent* 1993;11:33-6
20. Groeneveld X, Damme VP. Natal teeth in perspective: Literature review and report of two cases. *Ned Tijdschr Tandheelkd* 1993;100(2):49-51.