

RESEARCH ARTICLE

Morphology, Morphometry and Neuroanatomy of the Olfactory Epithelium and the Olfactory Bulb of a Featherback Fish, *Notopterus notopterus*

Patle Pratap J and Baile Vidya V

Division of Fish Neurobiology, PG Department of Zoology, RTM Nagpur University Campus, Nagpur- 440033, India.

*Corresponding author e-mail: baile.vidya@gmail.com

Manuscript details:

Received: 21 February, 2014
Revised Received: 13 March, 2014
Finally accepted: 15 March, 2014

Date of publication (online):
30 March, 2014

ISSN: 2320-964X (Online)
ISSN: 2320-7817 (Print)

Editor:

Dr. Arvind Chavhan &
Dr. Bela Volgyi.

Citation: Patle Pratap J and Baile Vidya V (2014) Morphology, Morphometry and Neuroanatomy of the Olfactory Epithelium and the Olfactory Bulb of a Featherback Fish, *Notopterus notopterus*, *International Journal of Life Sciences*, 2 (1): 1-12.

Copyright: © Patle and Baile, This is an open access article under the terms of the Creative Commons Attribution-NonCommercial- No Derivs License, which permits use and distribution in any medium, provided the original work is properly cited, the use is non-commercial and no modifications or adaptations are made.



ABSTRACT

Olfactory organs of fishes show wide range of variations depending upon the systematic groups and ecological habitats. Number, shape and arrangement of the lamellae vary considerably among different teleosts ranging from flat unfolded surface to multi-lamellar rosette. Objective of the present work was to study the organization of olfactory system of *Notopterus notopterus*. As it is demersal in habitat, olfaction is expected to play a prominent role in various life processes. With the help of Haematoxylin-Eosin and Kluver and Barrera (1953) staining techniques, organization of the olfactory epithelium and olfactory bulb was studied. In *N. notopterus*, olfactory epithelium is a multilamellar structure comprising 70-76 lamellae radiating from a median raphe. Each lamella comprises sensory and nonsensory regions. Sensory region shows ciliated, microvillous, crypt receptor cells, supporting cells and basal cells. Nonsensory region has ciliated nonsensory cells, basal cells and mucous cells. Within the median raphe, distinct melanophores innervated by axons from olfactory receptor neurons are observed. Olfactory epithelium is connected to the bulb by a short olfactory nerve. Olfactory bulb is a concentrically arranged four layered structure with olfactory nerve layer on the outermost side followed by glomerular layer, mitral cell layer and granular cell layer. Ruffed cells are observed surrounding the mitral cells. In dorsomedial region of the olfactory bulb, giant cells of nervus terminalis are prominent. In the present study, fiber projections from the olfactory receptor neurons to ventral telencephalon are clearly demonstrated histologically, indicating the pathway of chemosensory signal from olfactory receptor neurons to the higher brain areas. This work will be useful to study the neuroanatomy of the olfactory system and ultimately to understand neurobiology of fish olfaction.

Key Words: chemosensation, olfactory receptor neurons, projections, teleost

INTRODUCTION

Olfaction and gustation are chemosensory systems that support fish survival. Olfaction is involved in diverse teleost behaviors (Hara, 1992) such as food-finding (Valentinčič, 2005), reproductive behavior, detecting and avoiding danger (Farbman, 1994), kin recognition (Rajakaruna *et al.*, 2006), reproduction (Olsén and Liley, 1993), and to find home stream during spawning migration by salmon (Stabell, 1992; Ueda *et al.*, 1998; Shoji *et al.*, 2000).

Functional neuroanatomy of olfaction is interesting to study as it is the only organ in fish where nerve cells are directly exposed to the environment. The olfactory organs of fishes show wide range of variations depending upon systematic groups and ecological habitats (Zeiske *et al.*, 1992; Hansen and Reutter, 2004). In fish and other vertebrates, this system consists of peripheral part called as olfactory rosette including the olfactory nerve formed by axons of olfactory receptor neurons (ORNs) and central part comprising olfactory bulb and higher brain areas involved in processing of olfactory information (Hansen and Reuter, 2004).

In some teleost fish, the peripheral olfactory organ, known as olfactory rosette, is composed of olfactory lamellae covered with olfactory epithelia (Zeiske *et al.*, 1992; Hansen and Zielinski, 2005) situated on the floor of nasal chamber. Studies revealed that enormous diversities exist regarding the shape, number, and arrangement of olfactory lamellae, distribution of sensory and non-sensory epithelia as well as the abundance of various receptor cell types in different teleosts. The foldings or lamellae of olfactory epithelium increase the surface area of epithelium as well as the sensitivities and efficacy of olfactory organ (Zeiske *et al.*, 1976).

As in other vertebrates, teleost ORNs, the main components of sensory epithelium relay olfactory information to the brain (Satou, 1992). Their axons project to the olfactory bulb (OB), the first relay station in the brain. OB can be pedunculated or close to telencephalon. Morphology of the OB is rather consistent across the vertebrate lineage. Distinct layers of cells process the incoming information and convey it to the higher brain centers. The layers in fish from outside to inside are: 1) the olfactory nerve layer (ONL), 2) the glomerular layer (GL), 3) the mitral cell layer (MCL) and 4) the internal cell layer i.e. granular cell layer (GCL). Olfactory nerve endings branch at their very end and synapse on the second-order neurons, the mitral cells. Fish mitral cells have a large cell body and more than one dendrite. In addition to the synaptic input from ORNs, mitral cells form numerous dendro-dendritic reciprocal synapses with granule cells of the internal cell layer.

Another type of neuron occurs between the mitral cells, the ruffed cell (Kosaka, 1980; Kosaka and Hama, 1981; Patle, 2013). These cells synapse to other neurons and surround mitral cell dendrites resembling glial cell processes (Kosaka, 1980). Local interneuron's (granule cells) of the internal cell layer receive the input from centrifugal fibers from higher telencephalon (Ichikawa, 1976). Axons of the mitral cells and ruffed cells run through the olfactory tract (OT) and convey their information to the telencephalon. This is evident as fibers of the OT terminate on various brain areas (Oka *et*

al., 1982; Satou, 1990; 1992; Huesa *et al.*, 2000). The OT is divided into two bundles, the lateral olfactory tract (LOT) and the medial olfactory tract (MOT). Both bundles are divided further into smaller bundles (Sheldon, 1912). Each bundle conveys distinct classes of information (Sorensen *et al.*, 1991; Hamdani *et al.*, 2001a; Hamdani *et al.*, 2001b). Much of the information is available on Cyprinids; however, there is dearth of knowledge in some aspects of these studies relating to the olfactory system of Clupeids. An effort has been made in the present investigation to describe morphology, morphometry and neuroanatomy of the olfactory epithelium and the olfactory bulb of a fresh water teleost, *Notopterus notopterus* belonging to order Osteoglossiformes.

MATERIALS AND METHODS

Animal subject

Adult featherbacks (*N. notopterus*) of either sex (n = 12) with body weight ranging between 125g to 150g and length 24cm to 29cm were obtained from Telangkhedhi-Futala lake, Nagpur City. After transport, fishes were maintained in well-aerated glass aquaria (3×2×1.5) for a week to allow the stress from transportation to subside and to acclimatize them to laboratory conditions (photoperiod 12L: 12D; water temperature 25°C ± 1°C).

After acclimatization, fishes were anaesthetized with an aqueous solution of 2 phenoxyethanol (0.03%; P 1126; Sigma), decapitated and olfactory system with the brain was dissected out and further processed for respective studies. All experimental and animal care protocols were approved by the Institutional Animal Care and Use Committee.

Morphology and Morphometric analysis

For morphological studies, dissected tissues were observed under Leica (MS5) stereo dissecting microscope and measurements of various parts of olfactory organ were noted. All the numeral data in results were presented as mean values ± standard deviations (SD).

Neuroanatomical studies

After dissecting out, tissues were immediately fixed in aqueous Bouin's fixative for 24 hrs, dehydrated in graded series of alcohol and embedded in paraffin wax after clearing in xylene. For neuroanatomical studies, sections of olfactory epithelium, olfactory bulb and olfactory epithelium in connection with bulb were cut at 10 µm thickness in transverse as well as saggital planes on a vibratome, mounted on Mayer's albumin coated slides, and then subjected to Haematoxylin-Eosin and Kluver and Barrera (1953) staining.

Structural analysis and use of nomenclature

The stained sections were analyzed on a Nikon Eclipse E200 photomicroscope and different nuclear groups were identified according to the characteristic size, shape and staining intensity of the perikaryon, packing density as well as distribution pattern of the cell bodies. For the identification and nomenclature of various cell types in the olfactory epithelium and bulb, we mainly relied on Hansen and Zeiske (1998), Hansen and Reutter (2004), Hansen and Zielinski (2005), Bhute and Baile (2007), Baile *et al.* (2008), Patle (2009), Baile and Patle (2011) and Patle (2013).

Cell and nuclear diameter were measured with an oculometer. Cells (n = 50) were counted for each of the cell types. All the numeral data in results were presented as mean values ± standard deviations (SD).

Photo plates and images

Desired fields from various sections were photographed using Nikon (E8400) camera at different magnifications and adjusted for size, contrast and brightness in Adobe Photoshop 7.0 and Corel Photo-Paint X4 software. The line drawings and photo plates were prepared using Corel Draw X4 (version 14) software. Scale bars were expressed in terms of µm and measurements were taken by using an oculometer.

RESULTS

Featherback fish, *N. notopterus* (Fig. 1A) belongs to family Notopteridae of the order Osteoglossiformes. It is a fresh water demersal teleost, having laterally compressed body and its head is very small compared to its body size.

Morphology and Morphometry of the olfactory epithelium and bulb

In *N. notopterus*, paired olfactory organs with short olfactory nerve attached with bulb are situated on the snout region in the cavity called olfactory pits or olfactory chambers enclosed by a skin flap. Each organ is connected ventrally to the telencephalic hemisphere of brain by a long olfactory tract (Fig. 1B). It has an inlet situated at the base of short barbell just behind the mouth and an outlet at a distance from it nearer the eye. The olfactory organ is a cup shaped elongated structure possessing a series of 70-76 lamellae radiating from a central raphe on both the sides (Fig. 2A, B). The lamellae in the middle of rosette (on both sides) are the largest while they gradually taper towards anterior and posterior ends of the rosette (Fig. 2B, C). The data of morphometrics i.e. dimensions of the olfactory system are summarized in Table 1.

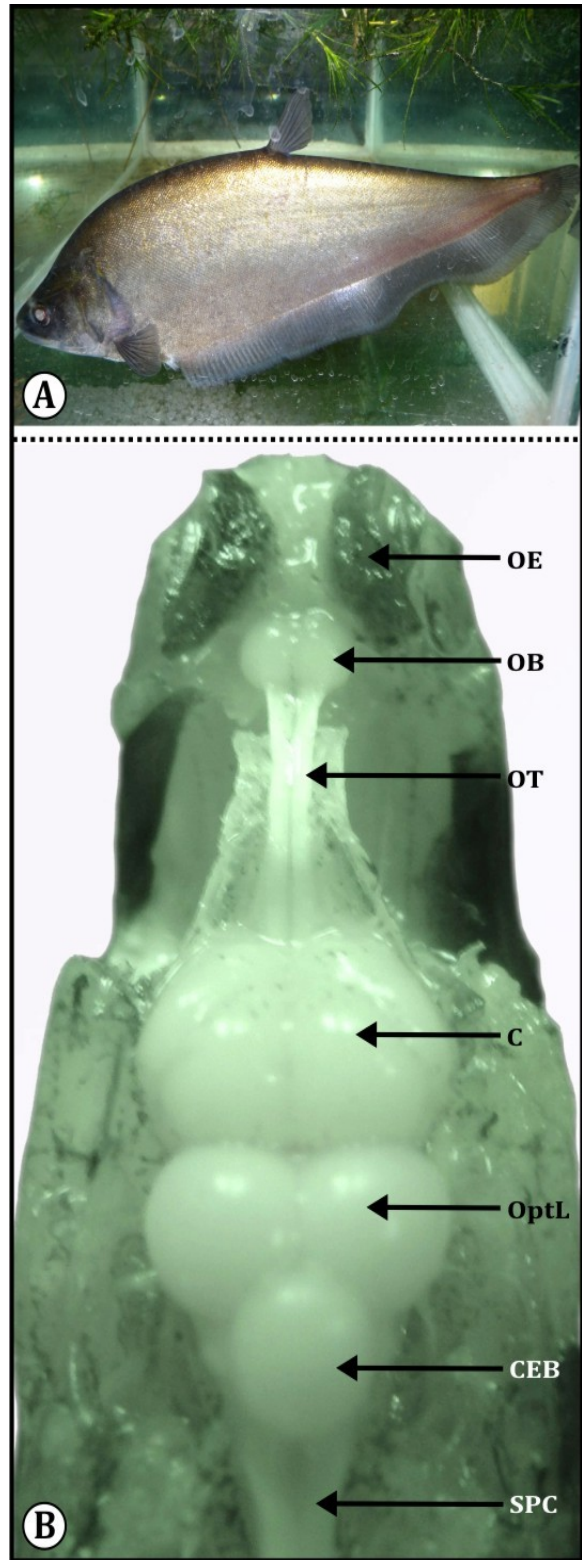


Fig. 1: (A) Photograph of *Notopterus notopterus*. (B) *In situ* photograph of olfactory organ with brain of *Notopterus notopterus* showing; cerebrum (C), cerebellum (CEB); olfactory bulb (OB), olfactory epithelium (OE), optic lobe (OptL), olfactory tract (OT) and spinal cord (SPC).

Table 1: Morphometric analysis of the olfactory system in *N. notopterus*

S. No.	Particulars			Size	
1.	Fish		Length	28 ± 0.83 cm	
			Weight	140 ± 7.9 gm	
2.	Head			58 ± 3.16 mm	
3.	Olfactory system	A.	Olfactory epithelium (OE)	Length	8.2 ± 0.8 mm
			Width	3.78 ± 0.19 mm	
		Cell types			
		a.	Ciliated olfactory receptor cells (ciORC)	Cell body	7.6 ± 0.31 µm
				Dendrite	11.18 ± 0.60 µm
		b.	Microvillous olfactory receptor cells (mORC)	Cell body	5.5 ± 0.41 µm
				Dendrite	6.56 ± 0.40 µm
		c.	Crypt olfactory receptor cells (crORC)	Diameter	2.9 ± 0.22 µm
		d.	Supporting cells (SC)	Diameter	7.6 ± 0.31 µm
		e.	Ciliated Non-sensory cells (ciNSC)	Cell body	5.76 ± 0.23 µm
				Cilia	6.68 ± 0.31 µm
		f.	Goblet cells (GC)/Mucous cells (MC)	Diameter	8.66 ± 0.86 µm
		g.	Basal cells (BC)	Diameter	3.9 ± 0.47 µm
		B.	Olfactory nerve (OlfN)	Length	1.1 ± 0.07 mm
		C.	Olfactory bulb (OB)	Length	2.44 ± 0.11 mm
				Width	1.6 ± 0.07 mm
			Cell types		
a.	Mitral cells (MC)		Diameter	11.5 ± 0.43 µm	
b.	Ruffed cells (RC)		Diameter	5.4 ± 0.44 µm	
c.	Granular cells (GC)		Diameter	4.74 ± 0.20 µm	
d.	Nervous terminalis (NT)	Diameter	7.6 ± 0.22 µm		
D.	Olfactory tract (OT)	Length	12.2 ± 0.74 mm		
4.	Eye		Diameter	8.62 ± 0.31 mm	
5.	Brain		Length	16.8 ± 0.82 mm	

*Cells (n = 50) were counted for each of the cell types and all the values are presented as mean ± standard deviations (SD).

Neuroanatomy of the olfactory epithelium and bulb

Olfactory epithelium (OE) of *N. notopterus* is a continuous thick sheet (30-35µm) of pseudo-stratified columnar epithelial cells which is folded to form olfactory lamellae (Fig. 2F). In the lamellae, epithelium encloses a central lumen called central core (CC)/lamina propria (LP) which contains blood vessels, connective tissues and nerve fibers (Fig. 2E, F, G). The CC/LP and OE are separated by a basal lamina (Fig. 2E, F, G). Within the median raphe and lamina propria, very distinct widely distributed melanophore like structures are observed (Fig. 2C, D, E) which are innervated by the fibers from ORNs. The lamellae show sensory (S) and nonsensory (NS) regions which are arranged very regularly (Fig. 2C, D). Sensory region is located at the proximal end and towards the basal area of lamellae comprising columnar ciliary receptor cells, columnar microvillous receptor cells, crypt receptor cells, columnar supporting cells and round basal cells (Fig. 2D, E, F). Supporting cells and receptor cells are arranged in alternate rows and basal cells are situated at the base just above the basal lamina (Fig. 2E, F). Non-

sensory region is at the middle of lamellae covered by columnar ciliated non-sensory cells, goblet cells/mucous cells and basal cells (Fig. 2D, E, G, H). These lamellae receive fascicles or fibers at its proximal end from ORNs and extend into short olfactory nerve (Fig. 4A, B, C). This nerve continues further into the olfactory bulb and spreads profusely at the periphery of bulb to form primary olfactory nerve layer (Fig. 4A, C) of the OB.

Cell types in olfactory epithelium

1) Ciliated olfactory receptor cells (ciORC): These are largest among all the types of ORCs distributed throughout the sensory epithelium having 7.6 ± 0.31 µm of cell body and 11.18 ± 0.60 µm of dendrite. ciORC are columnar, bipolar cells bearing a basally located cell body, a thin long dendrite reaching upto epithelial surface with apically arranged cilia and an axonal process toward the basal lamina. The cell body containing a round prominent nucleus is situated deep in the epithelium. The cytoplasm is highly granular and intensely stained (Fig. 2E, F).

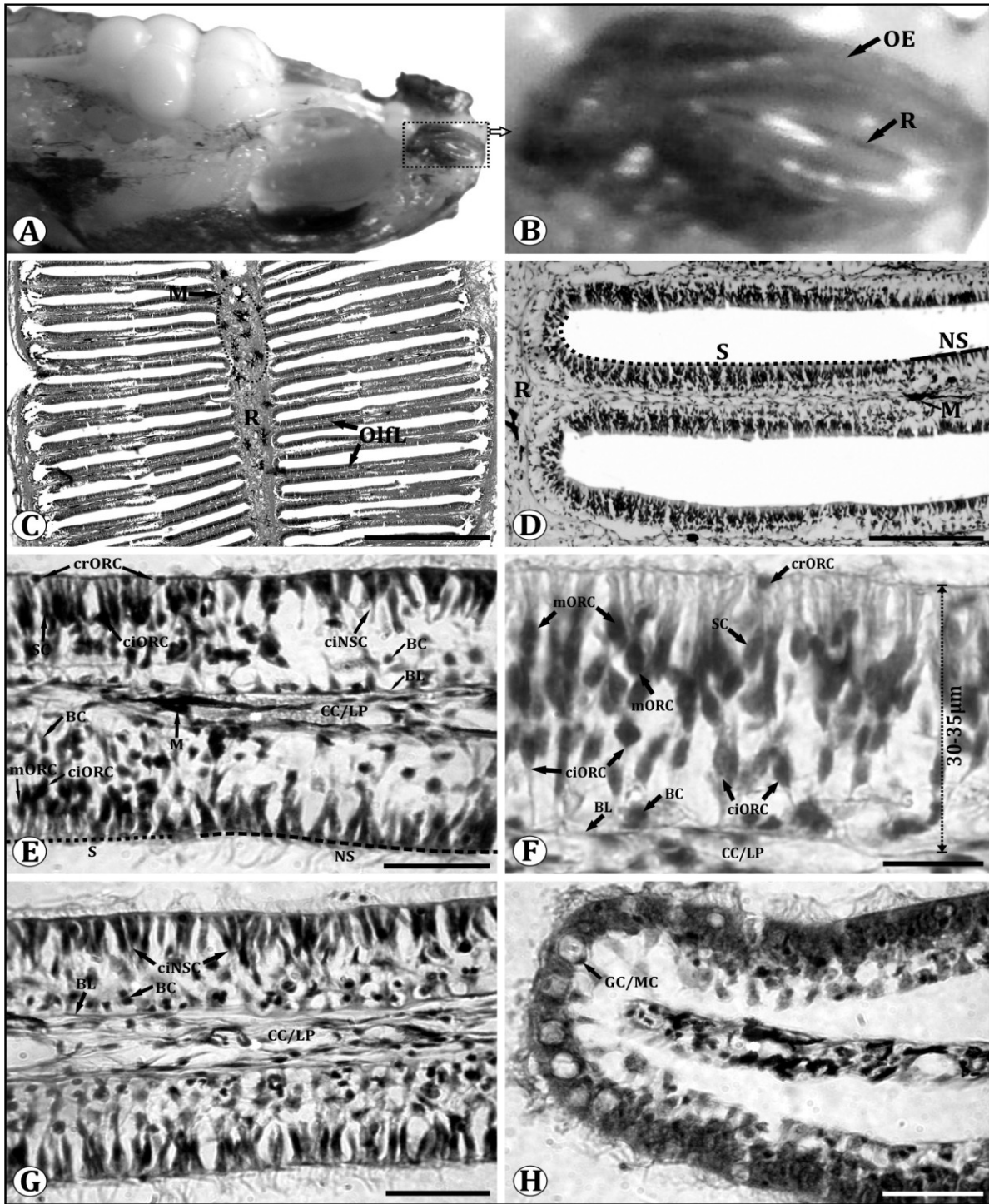


Fig. 2: (A) Lateral view of the dissected olfactory organ with brain showing location of olfactory epithelium. (B) Magnified view of the olfactory epithelium (OE) showing median raphe (R). (C) Transverse section of the olfactory epithelium showing olfactory lamellae (Olfl) radiating from the central raphe (R) and melanophores (M). Scale bar = 500µm. (D) Transverse section of the olfactory epithelium showing location of sensory (S) and nonsensory (NS) regions of the olfactory lamellae. Scale bar = 100µm. (E) Magnified view of the sensory and nonsensory regions of the olfactory lamellae showing basal cell (BC), basal lamina (BL), central core (CC)/lamina propria (LP), ciliated nonsensory cell (ciNSC), crypt olfactory receptor cell (crORC), ciliated olfactory receptor cell (ciORC), melanophore (M), microvillous olfactory receptor cell (mORC) and supporting cell (SC). Scale bar = 25µm. (F) Magnified view of the sensory region of the olfactory lamellae showing; basal cell (BC), basal lamina (BL), central core (CC)/lamina propria (LP), crypt olfactory receptor cell (crORC), ciliated olfactory receptor cell (ciORC), microvillous olfactory receptor cell (mORC) and supporting cell (SC). Scale bar = 25µm. (G) Magnified view of the nonsensory region of the olfactory lamellae showing; basal cell (BC), basal lamina (BL), central core (CC)/lamina propria (LP) and ciliated nonsensory cells (ciNSC). Scale bar = 25µm. (H) Magnified view of the nonsensory region at tip of the olfactory lamellae showing; mucous cells (MC). Scale bar = 25µm.

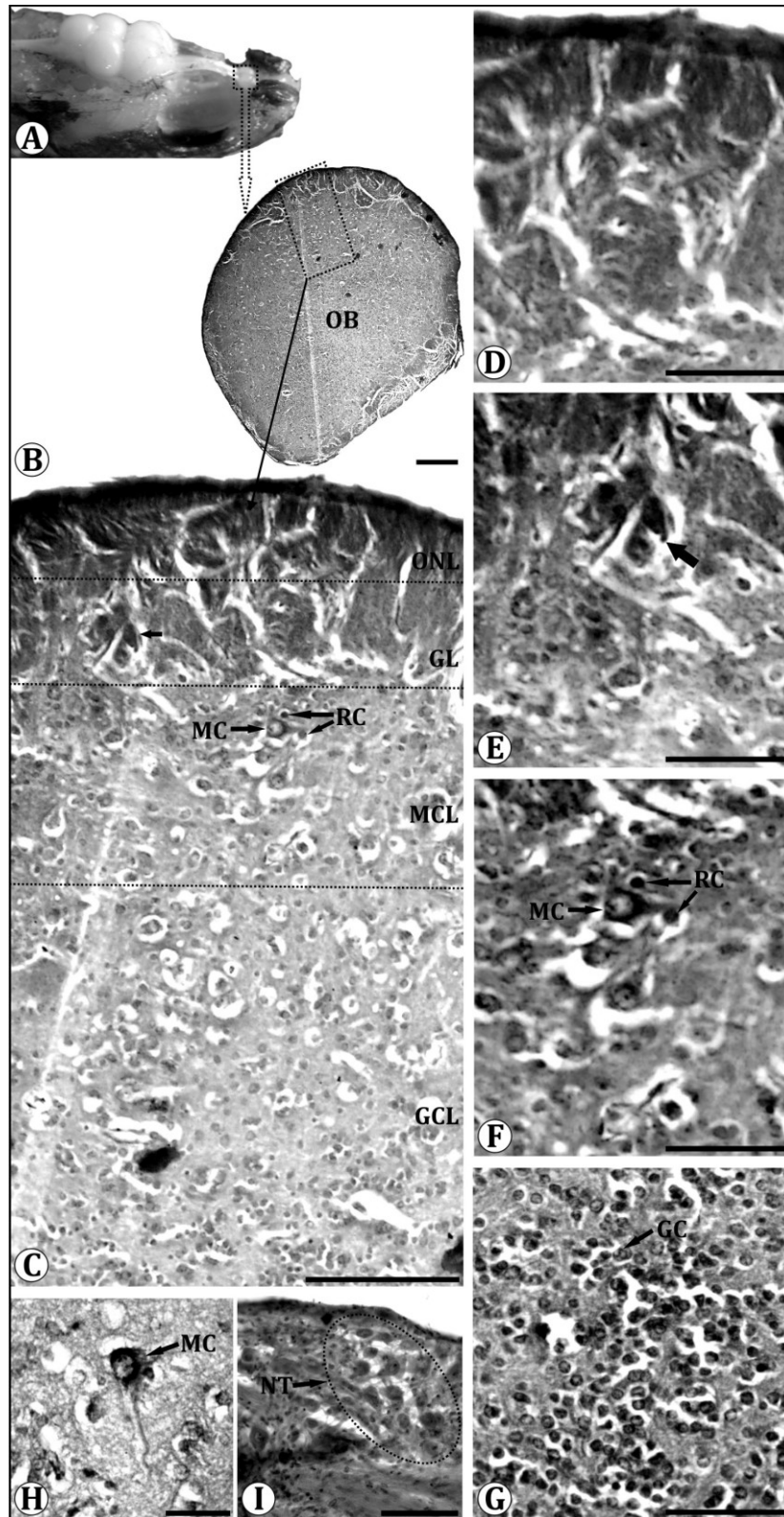


Fig. 3: (A) Lateral view of *In situ* photograph of olfactory organ with brain of *Notopterus notopterus* showing location of olfactory bulb. (B) Transverse section of the olfactory bulb. Scale bar = 200µm. (C) Part of transverse section of the olfactory bulb showing concentrically arranged four layers viz: Olfactory nerve layer (ONL), Glomerular layer (GL) showing formation of glomeruli (arrow), Mitral cell layer (MCL) showing mitral cell (MC) and ruffed cell (RC) and Granular cell layer (GCL). Scale bar = 100µm. (D) Magnified part of ONL showing innervations of olfactory nerve fibers. Scale bar = 50µm. (E) Magnified part of the glomerular layer showing formation of glomeruli (arrow). Scale bar = 50µm. (F) Magnified part of the MCL showing Mitral cells (MC) and ruffed cells (RC). Scale bar = 50µm. (G) Magnified part of the GCL showing granular cells (GC). Scale bar = 50µm. (H) Magnified view of the mitral cell (MC). Scale bar = 25µm. (I) Part of the transverse section of the dorsomedial region of the olfactory bulb showing neurons of nervus terminalis (NT). Scale bar = 50µm.

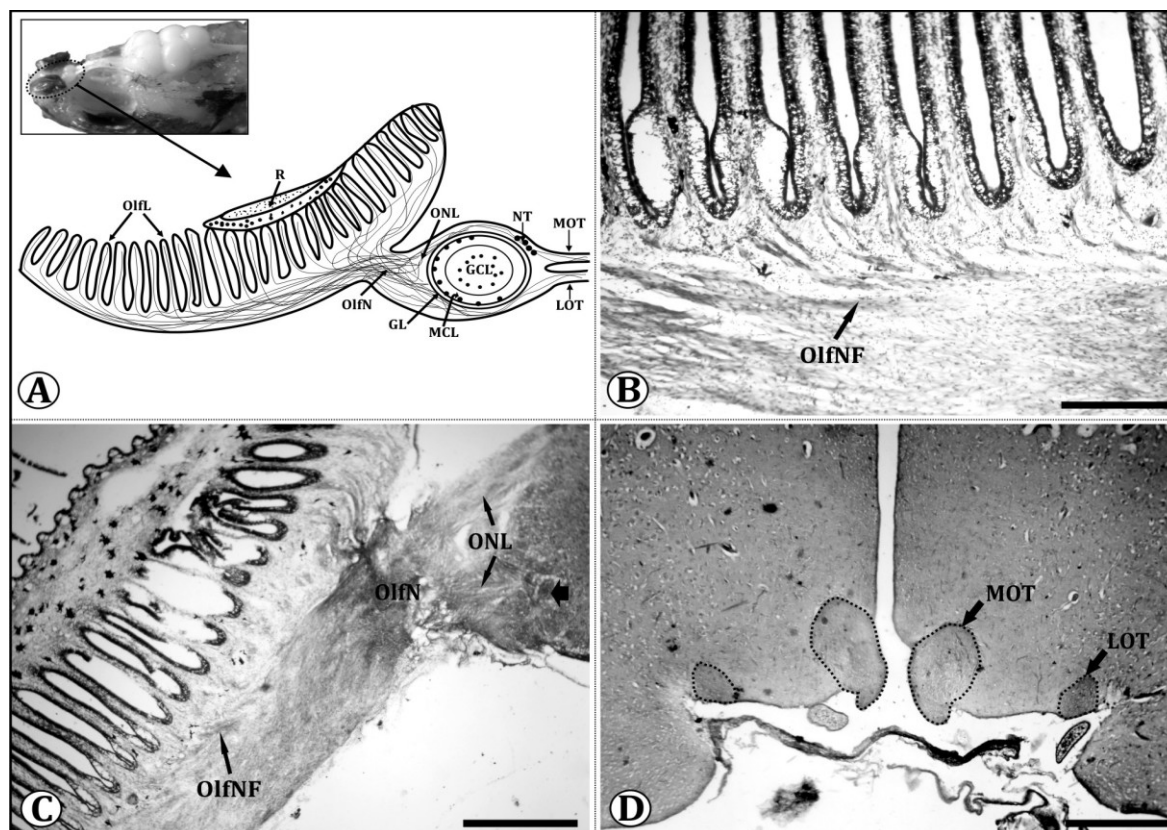


Fig. 4: (A) Diagrammatic representation of the mid saggital section of the olfactory system of *N. notopterus* showing fibers from olfactory receptor neurons entering the olfactory bulb through short olfactory nerve (OlfN), forming olfactory nerve layer (ONL). Location of glomerular layer (GL), mitral cell layer (MCL), granular cell layer (GCL), lateral olfactory tract (LOT) and medial olfactory tract (MOT) is also depicted. (B) Part of the mid saggital section of the olfactory epithelium showing fibers from the olfactory receptor neurons (OlfNF) entering the olfactory nerve. Scale bar = 200µm. (C) Mid saggital section of the olfactory system showing fibers from the olfactory receptor neurons (OlfNF) entering into olfactory bulb through short olfactory nerve (OlfN) forming primary olfactory nerve layer (ONL) and glomeruli (broad arrow). Scale bar = 400µm. (D) Part of the transverse section of ventral telencephalon showing projections of olfactory tract comprising medial olfactory tract (MOT) and lateral olfactory tract (LOT). Scale bar = 200µm.

- 2) Microvillous olfactory receptor cells (mORC): These are of moderate size having $5.5 \pm 0.41 \mu\text{m}$ of cell body and $6.56 \pm 0.40 \mu\text{m}$ of dendrite. mORC are columnar bipolar cells with a cell body located midway, thick moderate length dendrite reaching upto epithelial surface without cilia and an axonal process towards the basal lamina. Cell body is more superficial in the epithelium than the ciORC and possesses a round nucleus. Cytoplasm is granular and stained intensely (Fig. 2E, F). Population of these cells dominated over the ciORC.
- 3) Crypt olfactory receptor cells (crORC): These are smallest among all the ORCs, having $2.9 \pm 0.22 \mu\text{m}$ diameter. Crypt cells are spherical or pear-shaped having cell body situated apically just close to the epithelial surface, devoid of dendrite and with an axonal process toward the basal lamina. They are characterized by submerged cilia in the upper portion of the cell showing intense staining and are very few in number (Fig. 2E, F).
- 4) Supporting cells (SC): These are of $7.6 \pm 0.31 \mu\text{m}$ size. Supporting cells are elliptical to columnar in shape with a prominent central basophilic nucleus situated deep in the epithelium and without any dendrite and axonal processes. Cytoplasm is less granular and moderately stained (Fig. 2E, F).
- 5) Ciliated Non-sensory cells (ciNSC): These have $5.76 \pm 0.23 \mu\text{m}$ of cell body and $6.68 \pm 0.31 \mu\text{m}$ of cilia. Ciliated non-sensory cells are columnar, without dendrite and axon and consist of numerous long cilia at its surface. Nucleus is round and located in the middle of the cell showing intense staining (Fig. 2G).
- 6) Goblet cells (GC) or Mucous cells (MC): These are fairly larger ($8.66 \pm 0.86 \mu\text{m}$), oval in shape and restricted to the nonsensory region of lamellae surrounded by ciliated nonsensory cells consisting of more granules. Olfactory lumen is covered by the mucous (Fig. 2H).

- 7) Basal cells (BC): These are small ($3.9 \pm 0.47 \mu\text{m}$), oval in shape with a prominent round central nucleus lying in the deeper part of the epithelium just above the basal lamina in both sensory and non-sensory regions showing intense staining (Fig. 2E, F, G).

The *olfactory bulb* is oval in shape, pedunculated and anatomically divisible into four concentric layers (Fig. 3A, B, C). Outer layer is called as olfactory nerve layer (ONL) which has axons of ORNs (Fig. 3C, D). Below ONL, axons group together or arborise, forming glomeruli, called as glomerular layer (GL) (Fig. 3C, E). The glomeruli innervate the bigger sized multipolar neurons called mitral cells forming the mitral cell layer (MCL) which shows moderate staining (Fig. 3C, F, H). In the centre, densely packed small rounded cells are present forming granular cell layer (GCL) (Fig. 3C, G) which exhibits intense staining. Another type of neuron occurs surrounding the mitral cells, the ruffed cells (Fig. 3C, F) which are smaller in size as compared to the mitral cells. Nerve bundles carrying afferent fibers from the olfactory organs extend caudally over the olfactory nerves, penetrate the bulb from rostral pole and spread along the periphery of bulb to terminate on dendrites of mitral cells in glomerular layer (Fig. 4A, B, C). Axons of the mitral cell and ruffed cell run through the OT (comprising LOT and MOT) and extend to various telencephalic areas (Fig. 4D). Some cells are placed in dorsomedial and ventromedial position and are intensely stained. These are the giant cells of *nervus terminalis* (NT) (Fig. 3I).

DISCUSSION

In *N. notopterus* olfactory organs are paired situated on the snout. Each organ has two openings through which water enters and leaves the olfactory chambers. In *N. notopterus* sp. anterior inlet is in the form of an incomplete open membranous tube-like inlet. It is a unique feature and seems to be a specialized case of adaptation due to their shallow water and muddy habit. The tube-like inlet enables a fish to burrow and search for food in mud with no danger to its olfactory organ becoming clogged with silt particles (Datta Munshi and Hughes, 1992). The olfactory organs of fishes show wide range of variations depending upon the systematic groups and ecological habitats (Zeiske *et al.*, 1992; Hansen and Reutter, 2004). The morphology and morphometric data indicate that the olfactory organs in this fish are fairly large as compared to its head size and body size. It is thus clear that in *N. notopterus* chemosensory mechanism is strongly developed.

In some teleosts, the olfactory rosette is composed of olfactory lamellae covered with olfactory epithelia

(Zeiske *et al.*, 1992; Hansen and Zielinski, 2005) situated on the floor of nasal chamber. Olfactory epithelium in *N. notopterus* is a continuous thick sheet of pseudo-stratified columnar epithelial cells; 30-35 μm in thickness. It is 35 μm in the piranha, *Serrasalmus nattereri* (Schulte and Riehl, 1978), 35-55 μm in the European eel, *Anguilla anguilla* (Schulte, 1972), and 60-75 μm in the swordtail, *Xiphophorus helleri* (Zeiske *et al.*, 1976) which is folded to form olfactory lamellae. The number, shape and arrangement of the lamellae vary considerably among different teleosts ranging from flat unfolded surface to a multi-lamellar rosette (Yamamoto, 1982; Zeiske *et al.*, 1992). Teichmann (1954) has noted that olfactory organs and eyes are equally well developed in *N. notopterus* and *Hilsa ilisha* and included them in the eye and nose fish group on the basis of ratio of the surface area of the olfactory lamellae to that of the retinae. The large surface area provided by the olfactory lamellae increases the sensitivity and efficacy of the olfactory system (Zeiske *et al.*, 1976). This view is supported by our study as olfactory rosette in *N. notopterus* is a multi-lamellar rosette comprising large number (70-76) of lamellae which may provide more surface area for the binding of odorants. Generally lamellae are arranged laterally around the central raphe in *Danio rerio* (Hansen and Zeiske, 1998), *Clarias batrachus* (Khan *et al.*, 1998, 1999), *Cirrhinus mrigala* (Biju *et al.*, 2003), *Oreochromis mossambicus* (Singru *et al.*, 2003), *A. anguilla* (Hansen and Zielinski, 2005), *Mugil parsia* (Chakrabarti, 2005), *Labeo rohita* (Bhute *et al.*, 2007; Bhute and Baile, 2007), *Wallago attu* (Ghosh and Chakrabarti, 2009) and *Macroglyptus aculeatus* (Chakrabarti and Guin, 2011), same arrangement is observed in *N. notopterus*. However, in some other teleosts, olfactory lamellae are arranged at the top of raphe, parallel to each other and in rostral-caudal orientation as in *Channa punctatus* (Mandal *et al.*, 2005) and in *Channa gachua* (Patle, 2013).

In *N. notopterus*, from the median raphe, both sensory and nonsensory regions are located on the olfactory lamellae. Location of these regions varies in different species (Yamamoto, 1982). The sensory region is at the proximal end and basal region of lamellae in *N. notopterus* covering both the sides of lamellae separated by a lamina propria. This is thin sheet of connective tissue containing blood vessels, nerve fibers and in some cases melanophores (Hansen and Reutter, 2004). In *N. notopterus* widely distributed distinct melanophore population is observed in the median raphe and in lamina propria innervated by the nerve fibers which is a novel finding in our study. Previously these structures are observed in median raphe of Zebrafish (Weth *et al.*, 1996) and in *C. gachua* (Patle, 2013). To our knowledge we are the first ones to report these structures in the olfactory organ of a fresh water member of Osteoglossiformes. On the basis of its

distribution and organization pattern, it can be assumed that melanophores may play an important role in the processing of chemosensory information. In a Cyprinid *L. rohita*, sensory region is at the middle of lamellae and nonsensory region is at the proximal and basal regions of lamellae (Bhute *et al.*, 2007; Bhute and Baile, 2007), in *Rhodeus amarus*, sensory region is at the base and middle of lamellae and nonsensory region is at the proximal end (Baby *et al.*, 2000). In the sensory region, two morphologically distinct types of ORCs, ciliated and microvillous ORCs are prevalent in teleosts (Zielinski and Hara, 1988). They occur together but in varying proportions in different species (Zeiske *et al.*, 2003). In the OE of *N. notopterus*, mORC are dominant over ciORC, same is observed in *C. punctatus* (Mandal *et al.*, 2005) whereas ciORC are dominant over the mORC in *Labeo bata* (Ghosh and Chakrabarti, 2011) and in channel catfish, the density of mORC is highest in the medial part of lamellae while that of the ciORC was highest in the lateral areas of lamellae (Erickson and Caprio, 1984). Third type of cells, crypt ORCs are reported in Cyprinodonts (Zeiske *et al.*, 1976), catfish, swordtail and needlefishes (Hansen *et al.*, 1997), in Zebrafish, *D. rerio* (Hansen and Zeiske, 1998) and recently by Hansen and Finger (2000). Limited numbers of crypt receptor cells are noticed in our study. Such types of sensory cells can be considered as different functional and structural entities with different sensitivities to external stimuli (Yamamoto, 1982). Thommesen (1983) reported that ciliated ORCs are tuned toward bile salts and microvillous ORCs toward amino acids. However, recent electrophysiological studies concluded that ciliated ORCs might be termed as generalists which respond to varying species of odorants including amino acids, bile salts and other odorants whereas microvillous ORCs might be called as specialist, which respond specifically to amino acids and nucleotides (Sato and Suzuki, 2001; Hansen *et al.*, 2003). In between the sensory receptor cells, columnar supporting cells form a mosaic protecting them from mechanical injury. Basal cells are situated adjacent to the basal lamina and distributed throughout the epithelium in both sensory and nonsensory regions. Basal cells are assumed to be the progenitors of the receptor and supporting cells (Yamamoto, 1982; Zeiske *et al.*, 1992). Same type of arrangement is noticed in *N. notopterus*.

Adequate ventilation is necessary to bring the odorants in the olfactory chamber for perceiving the chemical signals (Kapoor and Ojha, 1972; Døving *et al.*, 1977; Belanger *et al.*, 2003). Ventilation of the olfactory chamber takes place by either forward motion of the fish, hydraulic pumping of the olfactory sac or by synchronous beating of cilia of ciliated non-sensory cells (Hara, 1993). Since the non-sensory epithelium in *N. notopterus* is covered with a dense mat of cilia, probably the ventilation of olfactory chamber in this fish is

achieved due to the beating action of cilia of ciliated non-sensory cells. Another type of cells found in the nonsensory region are the epidermal cells which form a component of the non-ciliated part of nonsensory epithelium and are structurally identical with those of the fish epidermis (Hawkes, 1974; Hara, 1982). These are observed in *C. punctatus* (Mandal *et al.*, 2005) and in *C. gachua* (Patle, 2013). However, these cells are not detected in our study. Mucous cell/goblet cell surrounded by ciliated nonsensory cells or epidermal cells (Hansen and Zeiske, 1998) secretes mucus to protect the epithelium from mechanical abrasion. These cells are previously reported in zebrafish, *D. rerio* (Hansen and Zeiske, 1998), snakehead, *C. punctatus* (Mandal *et al.*, 2005), *L. rohita* (Bhute *et al.*, 2007; Bhute and Baile, 2007), *W. attu* (Ghosh and Chakrabarti, 2009), *L. bata* (Ghosh and Chakrabarti, 2011) and *M. aculeatus* (Chakrabarti and Guin, 2011). Mucous cells in *N. notopterus* are fairly large and distributed profusely in the nonsensory region.

Axons of olfactory receptor neuron accumulate in the lamina propria of olfactory organ and in turn form the 1st cranial nerve, the olfactory nerve. The olfactory nerve varies in species-specific way (Hansen and Reutter, 2004). In general, fish with short olfactory nerves (goldfish, *Carassius auratus* and channel catfish, *Ictalurus punctatus*) have pedunculated OBs, with long olfactory tracts (OTs) and fish with long olfactory nerves tend to have short OTs, which is designated as "sessile" OBs, which are located next to the telencephalon proper as in eel, *A. anguilla*; swordtail, *X. helleri* (Hansen and Reutter, 2004) and snakehead, *C. gachua* (Baile and Patle, 2011). OTs form the connection between output neurons from OB and higher brain centers via the lateral olfactory tract (LOT) and the medial olfactory tract (MOT) and convey behaviorally distinct information. These two nerve bundles were observed by Sheldon (1912) in the carp from the medial and lateral parts of olfactory bulb respectively. MOT is subdivided into lateral (lMOT) and medial (mMOT) tracts in goldfish (Stacey and Kyle, 1983; Kyle, 1987; Sorensen *et al.*, 1991) and in Crucian carp, *Carassius carassius* (Hamdani *et al.*, 2000, 2001a, 2001b; Weltzien *et al.*, 2003). The lateral olfactory tract controls feeding behavior in goldfish, whereas the medial olfactory tract controls reproductive behavior in males (Stacey and Kyle, 1983; Demski and Dulka, 1984; Kyle *et al.*, 1987; Sorensen *et al.*, 1991; Von Rekowski and Zippel, 1993). In Crucian carp, LOT has been shown to mediate information associated with feeding behavior, whereas mMOT mediates information associated with alarm response. lMOT mediates reproductive behavior in males (Hamdani *et al.*, 2000, 2001a, 2001b; Weltzien *et al.*, 2003). In *N. notopterus*, olfactory bulb is of pedunculated type, connected to the telencephalon by two tracts: MOT and LOT. Such type of olfactory organ is

also found in other members of family Cyprinidae (Biju *et al.*, 2003; Bhute *et al.*, 2007) and Acanthidae (Bass, 1981). The reasons for two morphological types of OB (sessile and pedunculated) are not well understood.

Olfactory bulb comprises four layers from superficial to the deep *viz*: 1) the olfactory nerve layer (ONL), 2) the glomerular layer (GL), 3) the mitral cell layer (MCL) and 4) the internal cell layer also called as granular cell layer (GCL) (Khan *et al.*, 1998, 1999; Biju *et al.*, 2003; Singru *et al.*, 2003; Bhute *et al.*, 2007; Baile *et al.*, 2008; Baile and Patle, 2011) same pattern is observed in *N. notopterus*. In the OB, ruffed cells are observed surrounding mitral cells which are also reported in the goldfish (Kosaka, 1980; Kosaka and Hama, 1981; Zippel *et al.*, 1999). Fibers of the olfactory receptor neurons (ORNs) extend caudally over the olfactory nerve, penetrate the bulb from anterior side, spread along the periphery of bulb and synapses with the dendrites of mitral cells forming glomeruli which are clearly demonstrated in *N. notopterus* as in other teleosts (Bhute *et al.*, 2007; Baby *et al.*, 2000; Khan *et al.*, 1999; Baile and Patle, 2011). Glomeruli are histologically distinct units that serve as the basic modules in information processing (Shepherd, 1994) and as a relay station to several higher brain areas (Satou, 1992). Axons of the mitral cells and ruffed cells run through the OT and terminate on various telencephalic areas (Satou, 1992). Same pattern of organization is observed in our study. In the olfactory bulb of *N. notopterus*, on the ventromedial and dorsomedial side, giant cells of the nervus terminalis have been identified. These ganglion cells are also noted in *I. punctatus* (Bass, 1981), goldfish (Stell *et al.*, 1984), *C. batrachus* (Khan *et al.*, 1998, 1999), *C. mrigala* (Biju *et al.*, 2003), *O. mossambicus* (Singru *et al.*, 2003), *L. rohita* (Bhute *et al.*, 2007) and in *C. gachua* (Baile and Patle, 2011). The processes of NT neurons travel caudally via the MOT and project to the retina, various brain areas and pineal organ suggesting their role in reproductive behavior, conduction of sex-related olfactory stimuli and modulation of visual inputs to the brain (Stell *et al.*, 1984; Biju *et al.*, 2003; Singru *et al.*, 2003).

In the present study, we have reported the morphology, morphometry and neuroanatomy of the olfactory system in relation to the body size of fish and its correlation with its habitat. It is observed that olfactory system in this fish is well developed. Fiber connectivity from olfactory receptor neurons to the brain is clearly demonstrated. This study will cater a sufficient data to study the neuroanatomy of olfactory system and ultimately to understand neurobiology of fish olfaction.

REFERENCES

- Baby SM, Ueck M, Prasada Rao PD (2000) Gonadotropin-releasing hormone immunoreactive neurons and associated nicotinamide adenine nucleotide phosphate diaphorase-positive neurons in the brain of teleosts, *Rhodeus amarus*. *General and Comparative Endocrinology*, 120: 44-54.
- Baile VV, Patle PJ (2011) Cytoarchitectonic study of the brain of a dwarf snakehead, *Channa gachua* (Ham.). I. The telencephalon. *Fish Physiology and Biochemistry*, 37: 993-1004.
- Baile VV, Raut IN, Bhute YV (2008) Organization of olfactory system, forebrain and pituitary gland of a teleost, *Notopterus notopterus*. *Annals of Neurosciences*, 15: 43-50.
- Bass AH (1981) Olfactory bulb efferents in the channel catfish, *Ictalurus punctatus*. *Journal of Morphology*, 169: 91-111.
- Belanger RM, Smith CM, Corkum LD, Zielinski BS (2003). Morphology and histochemistry of the peripheral olfactory organ in the round goby, *Neogobius melanostomus* (Teleostei: Gobiidae). *Journal of Morphology*, 257: 62-71.
- Bhute YV, Baile VV (2007) Organization of the olfactory system of the Indian major carp *Labeo rohita* (Ham.): A scanning and transmission electron microscopic study. *Journal of Evolutionary Biochemistry and Physiology*, 43: 342-349.
- Bhute YV, Masram SC, Raut IN, Baile VV (2007) Cytoarchitectonic pattern of the olfactory system, Forebrain and Pituitary gland of the Indian Major Carp, *Labeo rohita*. *Annals of Neurosciences*, 14: 30-36.
- Biju KC, Singru PS, Schreiberman MP, Subhedar NK (2003) Reproductive phase-related expression of GnRH-like immunoreactivity in the olfactory receptor neurons, their projections to the olfactory bulb and in the nervus terminalis in the female Indian major carp *Cirrhinus mrigala* (Ham.). *General and Comparative Endocrinology*, 133: 358-367.
- Chakrabarti P (2005) Histological and histochemical studies on the olfactory rosette of *Mugil parsia* (Hamilton). *Folia Morphologica*, 64(1): 41-46.
- Chakrabarti P, Guin S (2011) Surface architecture and histoarchitecture of the olfactory rosette of freshwater lesser spiny eel, *Macrogathus aculeatus* (Bloch). *Archives of Polish Fisheries*, 19: 297-303.
- Datta Munshi JS, Hughes GM (1992) Olfactory organs. In Air-breathing Fishes of India: Their Structure, Function and Life History, Eds., Datta Munshi JS, Hughes GM. Oxford & IBH Publishing Co. Pvt. Ltd., New Delhi, pp: 271-275.
- Demski LS, Dulka JG (1984) Functional-anatomical studies on sperm release evoked by electrical stimulation of the olfactory tract in goldfish. *Brain Research*, 291: 241-247.
- Døving KB, Dubois-Dauphin M, Holley A, Jourdan F (1977) Functional anatomy of the olfactory organ of fish and the ciliary mechanism of water transport. *Acta Zoologica*, 58: 245-255.
- Erickson JR, Caprio J (1984) The spatial distribution of ciliated and microvillous olfactory receptor neurons in the channel catfish is not matched by a differential specificity to amino acids and bile salt stimuli. *Chemical Senses*, 9: 127-141.
- Farbman AI (1994) The cellular basis of olfaction. *Endeavour*, 18: 2-8.

- Ghosh SK, Chakrabarti P (2009) Cellular architecture and functional aspects of the olfactory rosette of *Wallago attu* (Bleeker). *Turkish Journal of Fisheries and Aquatic Sciences*, 9: 187-190.
- Ghosh SK, Chakrabarti P (2011) Distribution and organization of different cells lining the olfactory epithelium of the Indian major carp, *Labeo bata* (Hamilton 1822): A light and scanning electron microscopic analysis. *Pakistan Journal of Biological Sciences*, 14: 736-741.
- Hamdani EH, Alexander G, Døving KB (2001a) Projections of sensory neurons with microvilli to the lateral olfactory tract indicates their participation in feeding behavior in crucian carp. *Chemical Senses*, 26: 1139-1144.
- Hamdani EH, Kasumyan A, Døving KB (2001b) Is feeding behaviour in crucian carp mediated by the lateral olfactory tract? *Chemical Senses*, 26: 1133-1138.
- Hamdani EH, Stabell OB, Alexander G, Døving KB (2000) Alarm reaction in the crucian carp is mediated by the medial bundle of the medial olfactory tract. *Chemical Senses*, 25: 103-109.
- Hansen A, Eller P, Finger TE, Zeiske E (1997) The crypt cell: a microvillous ciliated olfactory receptor cell in teleost fishes. *Chemical Senses*, 22: 694-695.
- Hansen A, Finger TE (2000) Phyletic distribution of crypt type olfactory receptor neurons in fishes. *Brain Behavior and Evolution*, 55: 100-110.
- Hansen A, Reutter K (2004) Chemosensory Systems in Fish: Structural, Functional and Ecological Aspects. In: *The Senses of Fish: Adaptations for the Reception of Natural Stimuli*, Eds., Von Der Emde G, Modgans J, Kapoor BG. Narosa Publishing House, New Delhi, pp: 55-89.
- Hansen A, Rolen SH, Anderson K, Morita Y, Caprio J, Finger TE (2003) Correlation between olfactory receptor cell type and function in the channel catfish. *Journal of Neuroscience*, 23(28): 9328-9339.
- Hansen A, Zeiske E (1998) The peripheral olfactory organ of the zebrafish, *Danio rerio*: an ultrastructural study. *Chemical Senses*, 23: 39-48.
- Hansen A, Zielinski BS (2005) Diversity in the olfactory epithelium of bony fishes: development, lamellar arrangement, sensory neuron cell types and transduction components. *Journal of Neurocytology*, 34: 183-208.
- Hara TJ (1982) *Chemoreception in fishes*. Elsevier: Amsterdam, pp: 333.
- Hara TJ (1992) Mechanism of Olfaction. In *Fish chemoreception*, Eds., Hara TJ. Chapman and Hall, London, pp: 150-170.
- Hara TJ (1993) Chemoreception. In *The physiology of fishes*, Eds., Evans DH. CRC Press, Boca raton, pp: 191-218.
- Hawkes JW (1974) The structure of fish skin. I. General organization. *Cell and Tissue Research*, 149: 147-158.
- Huesa G, Anadon R, Yanez J (2000) Olfactory projections in a chondrosteian fish *Acipenser baeri*: an experimental study. *Journal of Comparative Neurology*, 428: 145-158.
- Ichikawa M (1976) Fine structure of the olfactory bulb in the goldfish, *Carassius auratus*. *Brain Research*, 115: 53-56.
- Kapoor AS, Ojha PP (1972) Studies on ventilation of the olfactory chambers of fishes with a critical reevaluation of the role of accessory nasal sacs. *Archives de Biologie*, 83: 167-178.
- Khan FA, Jain MR, Saha SG, Subhedar NK (1998) FMRFamide-like immunoreactivity in the olfactory system responds to morphine treatment in the teleost *Clarias batrachus*: involvement of opiate receptors. *General and Comparative Endocrinology*, 110: 79-87.
- Khan FA, Saha SG, Sarkar S, Subhedar NK (1999) β -endorphin-like immunoreactivity in the forebrain and pituitary of teleosts *Clarias batrachus* (Linn.). *General and Comparative Endocrinology*, 113: 290-301.
- Kluver H, Barrera E (1953) A method for the combined staining of cells and fibers in the central nervous system. *Journal of Neuropathology and Experimental Neurology*, 12: 400-403.
- Kosaka T (1980) Ruffed cell: a new type of neuron with a distinctive initial unmyelinated portion of the olfactory bulb of goldfish. II. Fine structure of ruffed cell. *Journal of Comparative Neurology*, 193: 119-145.
- Kosaka T, Hama K (1981) Ruffed cell: a new type of neuron with a distinctive initial unmyelinated portion of the olfactory bulb of goldfish. III. Three dimensional structure of the ruffed cell dendrite. *Journal of Comparative Neurology*, 201: 571-587.
- Kyle AL, Sorensen PW, Stacey NE, Dulka JG (1987) Medial olfactory tract pathways controlling sexual reflexes and behavior in teleosts. *Annals of the New York Academy of Sciences*, 519: 97-107.
- Mandal DK, Roy D, Ghosh L (2005) Structural organization of the olfactory epithelium of a spotted snakehead fish, *Channa punctatus*. *Acta Ichthyologica et Piscatoria*, 35(1): 45-50.
- Oka Y, Ichikawa M, Ueda K (1982) Synaptic organization of the olfactory bulb and central projections of the olfactory tract. In *Chemoreception in Fishes*, Eds., Hara TJ. Elsevier Scientific Publ. Co. pp: 61-75.
- Olsén KH, Liley NR (1993) The significance of olfaction and social cues in milt availability, sexual hormone status, and spawning behavior of male rainbow trout (*Oncorhynchus mykiss*). *Gen. Comp. Endocrinology*, 89: 107-118.
- Patle PJ (2009) Immunocytochemical localization of neuropeptide Y (NPY) in the olfactory and brain of featherback fish, *Notopterus notopterus* (Pallas). M. Phil. Dissertation, RTM Nagpur University, Nagpur. M.S., India.
- Patle PJ (2013) Immunocytochemical studies on the effects of pesticide on olfactory-brain-pituitary-gonadal axis of a dwarf snakehead, *Channa gachua* (Hamilton). Ph. D. Thesis, RTM Nagpur University, Nagpur. M.S., India.
- Rajakaruna RS, Brown JA, Kaukinen KH, Miller KM (2006) Major histocompatibility complex and kin discrimination in Atlantic salmon and brook trout. *Molecular Ecology*, 15: 4569-4575.
- Sato K, Suzuki N (2001) Whole-cell response characteristics of ciliated and microvillous olfactory receptor neurons to amino acids, pheromone candidates and urine in rainbow trout. *Chemical Senses*, 26: 1145-1156.
- Satou M (1990) Synaptic organization, local neuronal circuitry, and functional segregation of the teleost olfactory bulb. *Progress in Neurobiology*, 34: 115-142.
- Satou M (1992) Synaptic organization of the olfactory bulb and its central projection. In *Fish Chemoreception*, Eds., Hara TJ. Chapman and Hall, London, pp: 40-59.
- Schulte E (1972) Untersuchungen an der Regio olfactoria des Aals, *Anguilla Anguilla* L. *Z. Zellforsch*, 125: 210-228.
- Schulte E, Riehl R (1978) Feinstruktur der Regio olfactoria vom Piranha, *Serrasalmus nattereri* (Kner, 1860) (Teleostei, Characidae). *Zoologischer Anzeiger*, 200: 119-131.
- Sheldon RE (1912) The olfactory tracts and centers in teleosts. *Journal of Comparative Neurology*, 22: 177-339.
- Shepherd GM (1994) The extent of adaptation in bullfrog saccular hair cells. *Journal of Neuroscience*, 14: 6217-6229.

- Shoji T, Ueda H, Ohgami T, Sakamoto T, Katsuragi Y, Yamauchi K, Kurihara K (2000) Amino acids dissolved in stream water as possible home stream odorants for masu salmon. *Chemical Senses*, 25: 533-540.
- Singru PS, Sakharkar AJ, Subhedar NK (2003) Neuronal nitric oxide synthase in the olfactory system of an adult teleost fish, *Oreochromis mossambicus*. *Brain Research*, 977: 157-168.
- Sorensen PW, Hara TJ, Stacey NE (1991) Sex pheromones selectively stimulate the medial olfactory tracts of the male goldfish. *Brain Research*, 558: 343-347.
- Stabell OB (1992) Olfactory control of homing behaviour in salmonids. In *Fish chemoreception*, Eds., Hara TJ. Chapman and Hall, London, pp: 249-270.
- Stacey NE, Kyle AL (1983) Effects of olfactory tract lesions on sexual and feeding behavior in the goldfish. *Physiology and Behavior*, 30: 621-628.
- Stell WK, Walker SE, Chohan KS, Ball AK (1984) The goldfish nervus terminalis: a luteinizing hormone-releasing hormone and molluscan cardioexcitatory peptide immunoreactive olfactory pathway. *Proceedings of the National Academy of Sciences USA*, 81: 940-944.
- Teichmann H (1954) Vergleichende Untersuchungen an der Nase der Fische. *Z. Morph. Oekol. Tiere*, 43: 171-212.
- Thommensen G (1983) Morphology, distribution, and specificity of olfactory receptor cells in salmonid fishes. *Acta Physiologica Scandinavica*, 117: 241-249.
- Ueda H, Kaeriyama M, Mukasa K, Urano A, Kudo H, Shoji T, Tokumitsu Y, Yamauchi K, Kurihara K (1998) Lacustrine sockeye salmon return straight to their natal area from open water using both visual and olfactory cues. *Chemical Senses*, 23: 207-212.
- Valentinčič T (2005) Olfactory discrimination in fishes. In *Fish chemosenses*, Eds., Reutter K, Kapoor BG. Science Publishers, Enfield (NH), pp: 63-85.
- Von Rekowski C, Zippel HP (1993) In goldfish the qualitative discriminative ability for odors rapidly returns after bilateral nerve axotomy and lateral olfactory tract transection. *Brain Research*, 618: 338-340.
- Weltzien F, Höglund E, Hamdani EH, Døving KB (2003) Does the lateral bundle of the medial olfactory tract mediate reproductive behavior in male crucian carp? *Chemical Senses*, 28: 293-300.
- Weth F, Nadler W, Korsching S (1996) Nested expression domains for odorant receptors in zebrafish olfactory epithelium. *Proceedings of the National Academy of Sciences USA*, 93: 3321-3326.
- Yamamoto M (1982) Comparative morphology of the peripheral organ in teleosts. In *Chemoreception in fishes*, Eds., Hara TJ. Elsevier, Amsterdam (The Netherlands), pp: 39-59.
- Zeiske E, Kasumyan A, Bartsch P, Hansen A (2003) Early development of the olfactory organ in sturgeons of the genus *Acipenser*: A comparative and electron microscopic study. *Anatomy and Embryology*, 206: 357-372.
- Zeiske E, Kux J, Melinkat R (1976) Development of the olfactory organ of oviparous and viviparous cyprinodonts (Teleostei). *Zeitschrift für Zoologische Systematik und Evolutionsforschung*, 14: 34-40.
- Zeiske E, Theisen B, Breucker H (1992) Structure, development and evolutionary aspects of the peripheral olfactory system. In *Fish Chemoreception*, Eds., Hara TJ. Chapman and Hall, London, pp: 13-39.
- Zielinski B, Hara TJ (1988) Morphological and physiological development of olfactory receptor cells in rainbow trout (*Salmo gairdneri*) embryos. *Journal of Comparative Neurology*, 271: 300-311.
- Zippel HP, Reschke C, Korff V (1999) Simultaneous recordings from two physiologically different types of relay neurons, mitral cells and ruffed cells in the olfactory bulb of goldfish. *Cellular and Molecular Biology*, 45: 327-337.