

The effect of Medroxy Progesterone Acetate on adrenal gland of Indian Palm Squirrel *Funambulus pennati* (Wroughton).

Pradhan VP

Dept. of Zoology, St. Francis de Sales College, Nagpur 440 006, (MS) India.

Address for correspondence Email: pradhan.sfscollege@gmail.com.

Article received : 30/07/2013 | Revised : 05/08/2013 | Accepted : 15/09/2013 | Online Published 25/09/2013

ABSTRACT

For many years research in the field of contraception or the application of contraceptive methods has been exclusively limited to female as compared to male fertility control. The most highly effective reversible contraceptive method for men with no side effects has yet to be developed. Administration of several progestational compounds has been shown to inhibit spermatogenesis. Although progesterone is studied extensively, the exact mechanism of action of this compound has not been proven. The present experiment was designed to determine the exact relationship between the pituitary-gonad and adrenal following the intramuscular injection of Depo-Provera to male squirrels *Funambulus pennati* (Wroughton). The proposed investigation will contribute to the understanding of pituitary-gonad-adrenal relationship and the results will be of considerable importance in contraceptive study.

KEYWORDS

Contraception, progesterone, Depo-Provera, fertility, adrenal.

INTRODUCTION:

Depo-Provera (Upjohn. Co. U.S.A.) is one of the long acting injectable progestin compounds, (6-medroxy-progesterone acetate). The United States withheld the approval of Depo-Provera for contraceptive purpose in 1974. Depo-Provera is capable of causing spermatogenetic suppression without feminizing effects and loss of libido.

Available literature indicates that disagreement exists regarding the mechanism of action of Depo-Provera. The present experiment was designed to determine the effect of Depo-provera on the histology of adrenal gland following the intramuscular injection of Depo-provera to male squirrels, *Funambulus pennati* (Wroughton).

MATERIAL AND METHODS

The species *Funambulus pennati* is synonym of palm squirrel. It belongs to the family squirrelidae of the sub-group scouromorpha, order Rodentia, Class Mammalia and is characterized by hairy body. They are arboreal in habit and found on trees close

to human habitation. The five striped palm squirrel, *Funambulus pennati* (Wroughton) was selected for the present study because of its convenient size and availability from local gardens around Nagpur. It can be maintained easily in captivity. It is a sturdy animal and is therefore, suitable for experimental purposes.

12 mature male squirrels weighing 112 to 120 gms were used in these experiment. The squirrels were kept in metal cage for experimental purposes. The squirrels were acclimatized in the laboratory for about 15 days at constant room temperature and humidity. Healthy male animals were separated, marked, weighed grouped and housed in different cages. They were kept on a diet of bread, fruits etc. and water was also given. Two groups of three males each were injected intramuscularly with Depo-Provera (Upjohn) company USA, the dose being 1.5mg/100gms /day for one month and sacrificed at an interval of 15 days. Two other groups of three male each were used as control and injected intramuscularly with the vehicle, cotton seed oil.

Table - I EXPERIMENTAL DESIGN

EXPERIMENT	TREATMENT/DRUG	NO.OF ANIMALS AND SEX	DOSE MG/KG/DAY	ADMINISTRATION	DURATION
Control group	Cotton Seed oil	3 Males	0.5 mg	Intramuscular	15 Days
Experimental group	Depo-Provera	3 Males	0.5 mg	Intramuscular	15 Days
Control group	Cotton Seed oil	3 Males	0.5 mg	Intramuscular	30 Days
Experimental group	Depo-Provera	3 Males	0.5 mg	Intramuscular	30 Days

NOTE: All animals were sacrificed 24 hours after the last injection.

The two doses of cotton seed oil were also the same as that for Depo-Provera, being for 15 days and one month respectively (Table 1).

The animals were sacrificed separately to avoid stress due to sight of sacrifice, (Madhyastha *et al.*, 1978). Harnes *et al.*, (1975) reported prolactin release in other rats kept in the same room of sacrifice, adrenal gland was dissected out and fixed. The material was dehydrated in different grades of ethanol cleared in xylol and embedded in paraffin wax and then sections were cut.

OBSERVATIONS:

1. Adrenal of control animal (Fig.1)

i) 15 Days: Histologically the adrenal gland was composed of cortex and medulla. The cortex was divided into three zones:-

Zona glomerulosa: consisted of compactly arranged cells in acini, nuclei of these cells were circular and centrally situated

Zona fasciculata: was composed of cords extended from peripheral to medullary region, the cords consisted of compactly arranged polygonal cells with granulated cytoplasm. Nuclei of these cells were circular and invariably situated eccentrically. This was the thickest zone of the adrenal gland.

Zona reticularis: was situated between the zona fasciculata and the medulla. It was composed of four to five layers. The cell membrane of these cells was not clear. In some of these cells the nuclei were vesicular with a distinct nucleolus. The central part of the gland was occupied by the medulla which consisted of cords or acini, several blood capillaries were found in these regions. Cells of this region were

large, polygonal with little cytoplasm. Nuclei of these cells were round or oval and situated centrally. No secretory granules were observed in the cytoplasm of these cells.

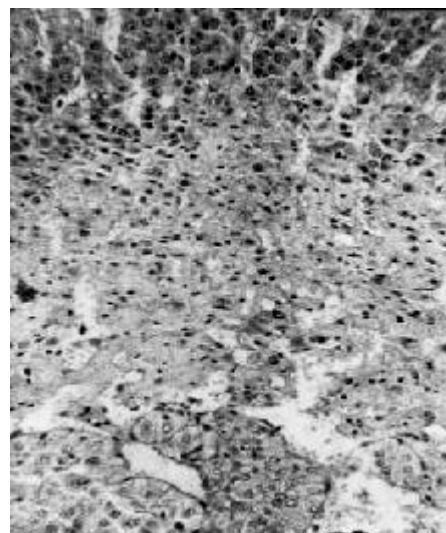


Fig 1: Section of adrenal gland of control animal showing three zones.

ii). 30 Days: Histological structure of the 30 days control adrenal was the same as that of 15 days control animal.

2. Adrenal of treated animal

i) 15 Days: - (Figure No.2,3,4) The histological study of adrenal gland after 15 days administration of Depo-Provera showed that there was a considerable hypertrophy and hyperplasia of the zona glomerulosa. The hypertrophy was particularly more in the peripheral layer which is designated by Del Conte (1972) as "reactive zone".




Fig. 2: Section of adrenal gland administered with Depo-provera for 15 days.

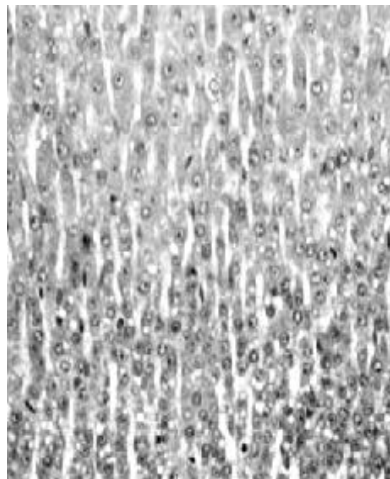


Fig. 3: Enlarged part of zona fasciculata showing presence of vacuoles.

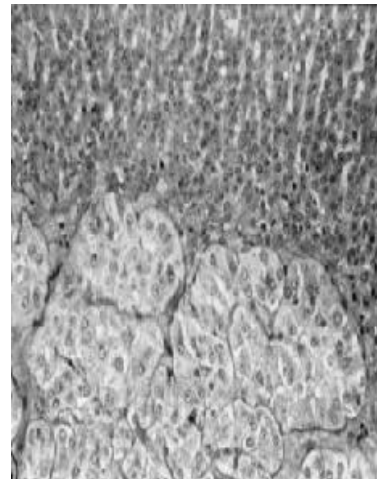


Fig. 4: Enlarged part of zona reticularis and medullary region showing hypertrophy.

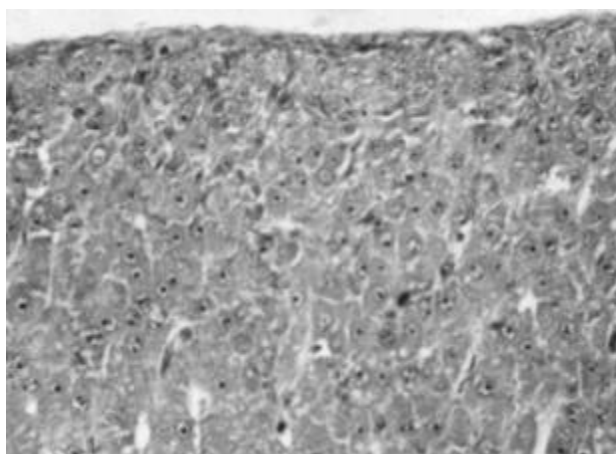


Figure No. 5. Section of adrenal gland of DMPA treated animal for 30 days showing the undifferentiated tissue of zona glomerulosa and zona fasciculata.

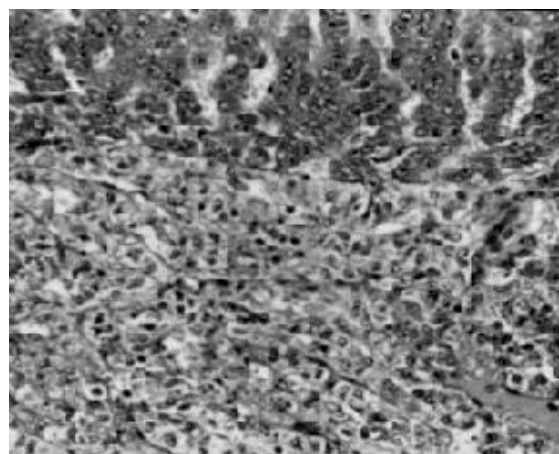


Figure No. 6. Enlarged part of zona reticularis and medullary region showing atrophy of the medullary region after 30 days treatment with DMPA.

The size of the cells and the nuclei increased. The enlarged spherical nuclei of the vesicular cells of the reactive zone were shifted to one side in the most of the cells, specially the zona fasciculata region. The vacuoles were seen in the cytoplasm of the cells of Zona fasciculata indicating the presence of inactivity of the cells. Zona reticularis was reduced significantly. The cells contained in the cytoplasm of zona reticularis contained vacuoles. Nuclei of these cells were condensed. This is the sign of inactivity of the cells. There was a great hypertrophy of the medullary zone. The chromaffin

cells were slightly enlarged and the intercellular connective tissue was reduced greatly.

ii). 30 Days: - (Figure No. 5, 6) Histologically new changes in the Zona glomerulosa were observed after the 30 days treatment of Depo-Provera. Zona fasciculata was reduced significantly as compared to 15 days animal, cytoplasm of these cells was foamy (i.e. vacuoles were present). Nuclei of these cells were enlarged. Thickness of Zona reticularis was decreased significantly. Medulla was also affected by this treatment. The cells lost their cell

membrane and became irregular in shape. Nuclei of these cells were contracted and the cytoplasm was seen to contain big vacuoles and enlarged blood capillaries (i.e. this part was more vascularised as compared to 15 days treated animal).

DISCUSSION

30 days treatment with Depo-Provera induced adrenal atrophy, particularly in the cortex region. Similar results have been observed in rat after administration of DMPA (Edgren, *et al.*, 1959, Gleen *et al.*, 1959, Givner *et al.*, 1972. It is also reported that the various zones of adrenal are not affected by a single dose of Depo-Medroxy-progesterone acetate (Aedo *et al.*, 1981).

Adrenal gland of Depo-Provera treated animal for 15 days and 30 days shows regression of Zona reticularis attesting the contraceptive activity of Depo-Provera.

CONCLUSION:

The observation in the study indicated good correlation between administration of Depo-Provera and contraceptive effect in the experimental male animal.

REFERENCES:

Aedo AR, Landgren BM and Dicalafusy E (1981) Studies on ovarian and adrenal studies at different phases of the menstrual cycle. IV. The effect of dexamethasone suppression and subsequent

ACTH stimulation at different phases of the menstrual cycle and following the administration of 150 mg of depot-medroxy-progesterone acetate (DMPA). *Journal Contraception*, 24(5): 543-58.

Del Conte E (1972) Existence of a reactive zone on the inter renal gland of reptiles. *Experientia* Aug. 19 (1) 26-36.

Edgren RA, Hambourger WE, Calhoun DW (1959) Production of adrenal atrophy by 6-methyl-17-acetal progesterone with remarks on the adrenal effects of other progestational agents. *Endocrinology* Sep 65: 505-507.

Givner ML, Rochefort JG. (1972) Effect of synthetic progestogens and estradiol-17 on adrenal function in the rat. *Endocrinology*. May 90(5):1238-44.

Glenn EM, Richardson SL, Bowman BJ (1959) Biological activity of 3-alpha-methyl compounds corresponding to progesterone 17-alpha hydroxyprogesterone acetate and compound S. *Metabolism* 8, 265-285.

Harnes PG, Langlier P, McCann SM (1975) Modification of stress induced prolactin release by dexamethaxone or adrenalectomy. *Endocrinology* 96:475-481.

Madhyastha NA, GopalDutt NH (1978) Prolactin secreting cells in the hypophysis of the brown spiny mouse *Mus Platythrix* (Bennett). *Proc. Indian. Acad, Sci*, 1101.87B (Experimental Biology-4). No. 10, October pp 271 – 282.

© 2013| Published by IJLSCI

Cite this article as: Pradhan VP (2013) The effect of Medroxy Progesterone Acetate on adrenal gland of Indian Palm Squirrel *Funambulus pennati* (Wroughton), *Int. J. of Life Sciences*, 1(3): 198-201.

Source of Support: Nil,

Conflict of Interest: None declared