



Effect of Aqueous Flower Extract of *Catharanthus roseus* on Alloxan Induced Diabetes in Male Albino Rats

A. Natarajan¹, K. Syed Zameer Ahmed¹, S. Sundaresan¹, A. Sivaraj², K. Devi³,
B. Senthil Kumar^{2*}

¹PG & Research Department of Zoology, C. Abdul Hakeem College, Melvisharam-632 509, Tamil Nadu, India

²Department of Zoology, Thiruvalluvar University, Serkkadu, Vellore-632 001, Tamil Nadu, India

³Department of Zoology, DKM College for Women, Vellore-632 00, Tamil Nadu, India

ABSTRACT

Catharanthus roseus is widely used in Indian Ayurvedic medicine for the treatment of diabetes mellitus. The present study was carried out to investigate the antidiabetic and hyperlipidemic potential of *Catharanthus roseus* on alloxan induced diabetes in male albino rats. Oral administration of aqueous extract of *Catharanthus roseus* at a dose of 250 mg, 350 mg, and 450 mg/kg body weight for 30 days to diabetic rats resulted in significant reduction in blood glucose, reduction in lipid profile and also prevented a decrease in body weight. Histological observation demonstrated significant fatty changes and inflammatory cell infiltrates in pancreas of diabetic rats. But, supplementation with *Catharanthus roseus* to diabetic rats significantly reduced the fatty changes and inflammatory cell infiltrates.

Keywords: *Catharanthus roseus*, alloxan, hyperglycemia, hyperlipidemia.

INTRODUCTION

Currently, there are over 150 million diabetic patients worldwide and this likely tends to increase to 300 million or more by the year 2025. [1] It has already been established that chronic hyperglycemia of diabetes is associated with long term damage, dysfunction and eventually the failure of organs, especially the eyes, kidneys, nerves, heart and blood vessels. [2] The use of medicinal plants for the treatment of diabetes mellitus dates back from the Ebers papyrus of about 1550 B.C. A multitude of herbs spices and other plant materials have been described for the treatment of diabetes throughout the world. [3] Few of the plants used for the treatment of diabetes have received scientific or medical scrutiny and even the WHO expert committee on diabetes recommends that this area warrant further attention. [4]

There are more than 1200 plants species worldwide that are used in the treatment of diabetes mellitus and a substantial number of plants have shown effective hypoglycemic activity after laboratory testing. [5-6] The medicinal plants provide a useful source of oral hypoglycemic compounds for the development of new pharmaceutical leads as well as a dietary supplement to existing therapies. [7] India has about 45,000 plant species and many of them have medicinal properties. [5]

Catharanthus roseus L. (Family: Apocyanaceae) also known as *Vinca rosea* is native to the Caribbean basin. It is an evergreen sub shrub or herbaceous plant growing up to 1 m tall. The leaves are oval to oblong, 2.5-9 cm long and 1-3.5 cm broad, glossy green, hairless, with a pale midrib and a short petiole 1-1.8 cm long; they are arranged in opposite pairs. The flowers are white to dark pink with a darker red centre, with a basal tube 2.5-3 cm long and a corolla 2-5 cm diameter with five petal-like lobes. The fruit is a pair of follicles 2-4 cm long and 3 mm broad. [8]

Catharanthus roseus locally known as "*Nithiya kalyani*" in Tamil is a native shrub widely distributed throughout India. In traditional Chinese medicine, extracts from it have been used to treat numerous diseases, including diabetes, malaria and Hodgkin's diseases. The substances vinblastine and vincristine extracted from the plant are used in the treatment of leukemia.

MATERIALS AND METHODS

Chemical

Alloxan was purchased from (SD Fine Chem Limited, Mumbai). Total cholesterol, phospholipids, free fatty acids, triglycerides were assayed using kits from Ranbaxy Diagnostics, New Delhi. Accu Chek Sensor of Roche Diagnostics, Germany was used for measuring fasting blood glucose levels and Uristix was purchased from Bayer Diagnostics India Ltd. Radio immuno assay (RIA) kit for insulin was supplied by Linco research Inc, Stat diagnostic, Mumbai, India.

*Corresponding author: Dr. B. Senthil Kumar, Professor and Head, Department of Zoology, Thiruvalluvar University, Serkkadu, Vellore-632 001, Tamil Nadu, India; Tel.: +91-9442378655; E-mail: senthil_cahc@yahoo.co.in

Plant material

The flowers of *Catharanthus roseus* (Apocyanaceae) were collected in and around Vellore District, Tamil Nadu, India. The plant materials were cleaned with distilled water, shade dried at room temperature and authenticated by Dr. A. Annadurai, Department of Botany, C. Abdul Hakeem College, Melvisharam, Vellore, Tamil Nadu and voucher specimens (CAHC-09/2009) were kept there.

Plant extract preparation

100 g of the powdered flowers materials of *Catharanthus roseus* was taken and mixed with 500 ml of distilled water and magnetically stirred in a container at room temperature for overnight. The residue was removed by filtration under vacuum to get *C. roseus* aqueous extract (CRAE) at a solid yield of 7%.

Animal

Adult male albino rats of 180-210 g were used throughout the experiments. The animals were procured from Tamil Nadu Veterinary and Animal Sciences University, Chennai, India. Before initiation of experiment, the rats were acclimatized for a period of 7 days. Standard environmental conditions such as temperature ($26 \pm 2^\circ\text{C}$), relative humidity (45-55%) and 12 hours dark/light cycle were maintained. All the animals were fed with rodent pellet diet (Hindustan Lever Ltd., Bangalore, India) and water was allowed *ad libitum* under strict hygienic conditions. The experiments were designed and conducted in accordance with the institutional guidelines.

Experimental induction of diabetes

The animals were fasted for 12 hours prior to the induction of diabetes. Alloxan (ALX) freshly prepared in 0.5% Tween-80 was administered intraperitoneally (*i.p.*) as a single dose of 150 mg/kg body wt. Development of diabetes was confirmed by measuring blood glucose concentration 5 days after the administration of ALX. Rats with blood glucose level of above 400 mg/dl were considered to be diabetic and used for the studies. All animals were allowed free access to water and pellet diet and maintained at room temperature in polypropylene cages.

Experimental design

In the experiment, a total of 30 rats (24 diabetic rats, 6 normal rats) were used. The rats were divided into six groups of six rats each and given treatment for 30 days. **Group 1:** Normal rats. **Group 2:** diabetic induced control rats. **Group 3:** Diabetic induced animals fed with *C. roseus* aqueous flower extract (250 mg/kg body wt.). **Group 4:** Diabetic induced animals fed with *C. roseus* aqueous flower extract (350 mg/kg body wt.). **Group 5:** Diabetic induced animals fed with *C. roseus* aqueous flower extract (450 mg/kg body wt.). Blood glucose was measured 2 days after first extract administration. Blood was withdrawn from the tail vein. To measure the levels of glucose, insulin lipid profile and enzyme activities, the animals were sacrificed on 30th day by cervical decapitation and serum and tissue samples were collected.

Effect of fasting blood glucose level

Fasting blood glucose was measured after 30 days of treatment with *C. roseus* flower extract, during which the animals were fed with normal diets. The blood glucose was measured using Accu Chek Sensor glucose estimation kit. The results were expressed in terms of mg/dl of blood. [2]

Estimation of plasma Insulin levels: Plasma insulin was estimated using Radio immuno assay (RIA) kit.

Estimation of lipid profile in blood sample

Total cholesterol (TC), high density lipoprotein cholesterol (HDL) and triglyceride (TG) levels in serum were measured spectrophotometrically by prescribed methods. [3] Urine sugar was detected by reagent-based uristrix. Low density lipoprotein cholesterol was calculated from the above measurement by using Friedwald formula.

Histopathological analysis

Pancreas samples were fixed in 40 g/l buffered formaldehyde and embedded in paraffin. Then the samples were cut into 5µm thick sections, and stained with haematoxylin and eosin for light microscopic examination. Histological assessment was performed by an investigator blinded to the treatment group. The severity of pancreatitis was determined by the degree of edema, hemorrhage, inflammation and necrosis. [9]

Statistical analysis

Results were expressed as mean \pm SD. Differences between groups were compared by two-way ANOVA. $P < 0.05$ was considered statistically significant. Mortality was assessed by Kaplan-Meier and log rank analysis. All data processing was done with a statistical program, SPSS 11.0.

RESULTS

The aqueous extract residue of *Catharanthus roseus* administered orally in an aqueous solution at increased dose levels of 250 mg, 350 mg, and 450 mg/kg body wt. to diabetic rats to assess the impact of the plant extracts (Table 1). The decreased insulin levels in the diabetic animals were enhanced significantly ($P < 0.001$) in the extracts treated animals. The highest increment was recorded at 450 mg dose level (78.05%).

The aqueous flower extract were fed with fasting and diabetes induced rats. The blood glucose levels was significantly ($P < 0.001$) reduced when compared to the specific control animals. The highest depletion was recorded at 450 mg dose level, (402.05%) in fasting rats and (59.92%) in diabetic induced rats.

Table 1: Effect of aqueous flower extract of *Catharanthus roseus* (Cr) on Serum insulin (µu/ml), Blood glucose (mg/dl) on alloxan induced diabetic rats

Experiment	Insulin (µu/ml)	Glucose (mg/dl)
Normal (N)	14.81 \pm 0.14	82.66 \pm 1.54
Alloxan (C)	7.70 \pm 0.23	415.0 \pm 7.63
Alloxan + Cr (250 mg/kg body wt)	9.23 \pm 0.12	269.50 \pm 3.73
Alloxan + Cr (350 mg/kg body wt)	11.80 \pm 0.15	195.33 \pm 2.99
Alloxan + Cr (450 mg/kg body wt)	13.71 \pm 0.14	166.33 \pm 3.15

Values are mean of six individual observations in each group \pm SEM.

Table 2: Effect of aqueous flower extract of *Catharanthus roseus* (Cr) on serum lipid profile (mg/dl) on alloxan induced diabetic rats

Experiment	TC	TG	HDL	LDL	VLDL
Normal (N)	77.33 \pm 2.4	84.91 \pm 0.5	29.91 \pm 0.	30.43 \pm 1.7	16.98 \pm 0.
Alloxan (C)	130.50 \pm 2.61	135.00 \pm 4.83	20.25 \pm 0.38	83.25 \pm 1.29	27.00 \pm 0.96
Alloxan + Cr (250 mg/kg body wt)	119.50 \pm 0.76	122.50 \pm 0.76	21.83 \pm 0.30	62.61 \pm 11.01	24.55 \pm 0.14
Alloxan + Cr (350 mg/kg body wt)	102.66 \pm 1.40	111.16 \pm 1.01	23.00 \pm 0.36	57.43 \pm 1.50	22.23 \pm 0.20
Alloxan + Cr (450 mg/kg body wt)	89.83 \pm 2.35	101.16 \pm 1.74	25.25 \pm 0.38	44.13 \pm 1.60	20.40 \pm 0.41

Values are mean of six individual observations in each group \pm SEM.

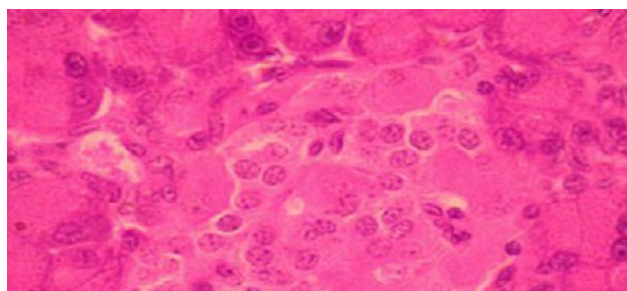


Fig. 1: The Pancreatic islets of langerhans of normal rat showing alpha cells and beta cells.

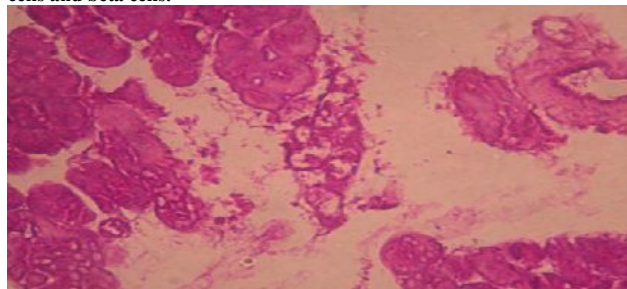


Fig. 2: Alloxan induced diabetic damaged pancreatic islets showing reduced size and increased damaged beta cells.

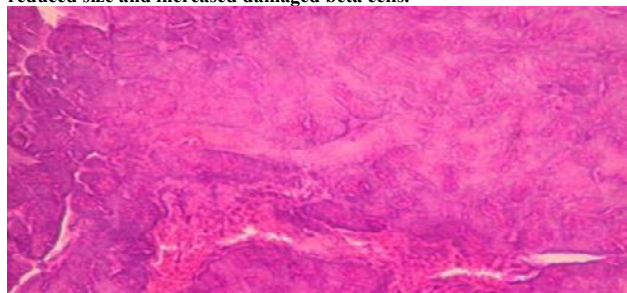


Fig. 3: Aqueous flower extract (250 mg/kg) treated pancreatic islets show partial revealed better restoration, when compared to the Alloxan induced diabetic control rats.

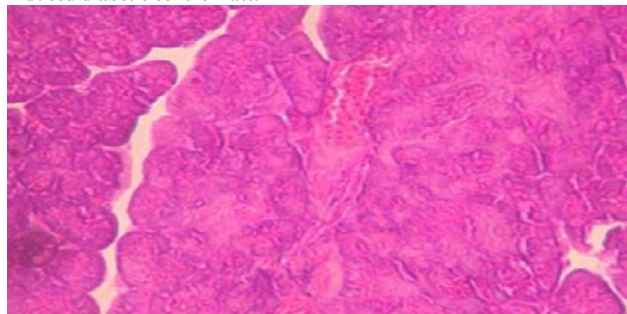


Fig. 4: Aqueous flower extract (350 mg/kg) treated pancreatic islets show partial revealed better restoration, when compared to the Alloxan induced diabetic and also 250 mg/kg treated rats.

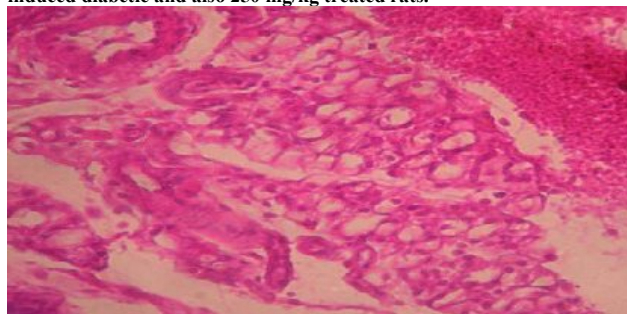


Fig. 5: Aqueous flower extract (450 mg/kg) treated pancreatic islets shows partial proliferation of beta cells. The animals revealed better restoration proliferation from the Alloxan induced damage when compared to control as well as 350 mg/kg treated animal.

The lipid profile such as TC, TG, LDL and VLDL levels were significantly increased in diabetic control animals (DC) whereas HDL levels were decreased when compared to the control rats (Table 2). The aqueous flower extract was administered orally at increasing dose levels of 250 mg, 350 mg, and 450 mg/kg body wt., to diabetic rats. The diabetic animals at 250 mg/kg dosage recorded no significant change in the TC, TG, HDL, LDL and VLDL levels. On the other hand when dosage levels were increased to 350 mg and 450 mg/kg body wt., a significant ($P < 0.001$) depletion in the total cholesterol level was recorded in the diabetic animals. The depletion in the TC, TG, LDL, and VLDL was dose dependent and the highest reduction in the cholesterol recorded was 21.33%, TG was 25.06%, LDL was 75.49% and VLDL was 24.44% in 450 mg/kg body wt., when compared to the diabetic control animals. The depleted high density lipoprotein (HDL) in the diabetic rats increased significantly ($P < 0.001$) after the administration of the plant extract. The highest increment was recorded at 450 mg/kg body wt. dosage level (24.69%).

Histological sections of endocrine regions of pancreas of Alloxan induced diabetic rats revealed a significant reduction in the size of the islets when compared to that of normal groups (Fig. 1-5). Further the study revealed the presence of damaged β -cell population. This damage of the β -cells is due to Alloxan induction. The reduction in β -cell number can be as low as 50% during diabetes.^[10] On the other hand, studies on the supplementation of aqueous flower extracts the diabetic rats revealed restoration of size of the islets along with β -cells repair. This recovery of the β -cells was found to be dependent on the dose of the aqueous flower extract. The restoration of β -cells was very good in 450mg/kg body wt extract fed groups.

DISCUSSION

Several medicinal plants are widely used for the treatment of diabetes mellitus in the traditional medicine of many countries. *Catharanthus roseus* is an important ingredient of a number of Ayurvedic formulations in India.^[11-12] Studies confirmed its antihyperglycemic potential along with its malaria and Hodgkin's diseases effects.^[13-17] The present work was carried out to know whether *C. roseus*, has a major phytoconstituent present in it as the active molecule for its antidiabetic effects.

Pancreas is the primary organ involved in sensing the organism's dietary and energetic states via glucose concentration in the blood and in response to elevated blood glucose; insulin is secreted.^[18]

The diabetogenic effect of alloxan was utilized to induce hyperglycemia in the present study. Nitric oxide has been demonstrated to participate in the beta cell damage during alloxan induced diabetes.^[19-20]

Diabetes affects both glucose and lipid metabolism.^[21] In the post prandial state elevated serum insulin increases lipoprotein lipase activity in adipose tissue and promotes fuel storage as triglycerides in normal metabolism.^[22] The deficiency of insulin depletes the activity level of lipoprotein lipase, thus leading to deranged lipoprotein metabolism during diabetes.^[23]

The lipoprotein levels in the alloxan induced diabetic rats in the present study reveal a significant deranged lipoprotein profile. The serum total cholesterol content was increased significantly in diabetic animals. The elevated triglycerides in

diabetic animals might be due to the consequence of increased synthesis of triglyceride rich lipoprotein particles (very low density lipoprotein, VLDL) in liver and diminished catabolism.^[24] Since insulin has a potent inhibitory effect on lipolysis in adipocytes, insulin deficiency is associated with excess lipolysis and increased influx of free fatty acids to the liver.^[25-26] The increased levels of low density lipoprotein (LDL) and very low density lipoprotein (VLDL) in the diabetic animals might be due to over production of LDL and VLDL by the liver due to the stimulation of hepatic triglyceride synthesis as a result of free fatty acid influx.^[24] The high density lipoprotein (HDL) was significantly reduced in the diabetic rats, which indicate a positive risk factor for atherosclerosis.^[27]

The levels of serum total cholesterol, triglycerides, LDL, and VLDL were significantly reduced in the plant extracts treated diabetic animals. This might be due to the reduced hepatic triglyceride synthesis and or reduced lipolysis that might be due to the increase in serum insulin levels in the plant extract treated animals. The high-density lipoprotein (HDL) was significantly ($P < 0.001$) increased in the plant extract treated animals indicating a reversed atherogenic risk.

The histological studies of the endocrine region of pancreas of the diabetic and aqueous flower extract treated animals revealed that shrinkage of β -cells of islets of langerhans in the diabetic animals. The aqueous flower extracts treated animals revealed restoration of β -cells. The restorations of the β -cells in diabetic treated (extract fed) animals corroborate the increased serum insulin levels in treated animals.

The present study suggests that the aqueous flower extract had synergetic hyperglycemia effect revealed by increased serum insulin levels, decreased serum lipid levels and therefore attribute to therapeutic value of the aqueous flower extract of *Catharanthus roseus* to combat the diabetic condition in rats.

REFERENCES

1. Zeggwagh NA, Ouahidi ML, Lemhadri A, Eddouks M. Study of hypoglycaemic and hypolipidemic effects of *Inula viscosa* L. aqueous extract in normal and diabetic rats. *Journal of Ethnopharmacology* 2006; 108: 223-227.
2. Sharma B, Balomajumder C, Roy P. Hypoglycemic and hypolipidemic effects of flavonoid rich extract from *Eugenia jambolana* seeds on streptozotocin induced diabetic rats. *Food and Chemical Toxicology* 2008; 46: 2376-2383.
3. Kesari AN, Gupta RK, Singh SK, Diwakar S, Watal G. Hypoglycemic and antihyperglycemic activity of *Aegle marmelos* seed extract in normal and diabetic rats. *Journal of Ethnopharmacology* 2006; 107: 374-379.
4. Sepici A, Gürbüz I, Çevik C, Yesilada E. Hypoglycaemic effects of myrtle oil in normal and alloxan-diabetic rabbits. *Journal of Ethnopharmacology* 2004; 93: 311-318.
5. Sivaraj A, Devi K, Palani SP, Vinoth Kumar P, Senthil Kumar B, David E. Anti-hyperglycemic and Anti-hyperlipidemic effect of combined plant extract of *Cassia auriculata* and *Aegle marmelos* in streptozotocin (STZ) induced diabetic albino rats. *Int J Pharm Tech Res.* 2009; 1(4):1010-1016.
6. Eddouks M, Maghrani M, Michel JB. Hypoglycemic effect of *Triticum repens* P. Beauv in normal and diabetic rats. *Journal of Ethnopharmacology* 2005; 102: 228-232.
7. Bailey LJ, Day C. Traditional plant medicine as treatment for diabetes. *Diab Care.* 1989; 12: 553-564.
8. Huxley A. *New RHS Dictionary of Gardening.* Macmillan ISBN. 1992; 0-333-47494-5.
9. Zi-Qian C, Yao-Qing T, Zhang Y, Zhi-Hong J, En-Qiang M, Wei-Guo Z, Ruo-Qing L, Tian-Quan H, Sheng-Dao Z. Adenoviral transfer of human interleukin-10 gene in lethal pancreatitis. *World Journal of Gastroenterology* 2004; 10(20): 3021-3025.
10. Hayashida CY, Suzuki K, Fujika H, Koizumi M, Toyota T, Goto Y. Morphometrical quantization of pancreatic endocrine cells in patients with carcinoma of the pancreas. *Tohoku J. Exp. Med.* 1983; 141:311-322.
11. Pandey VN. Pharmacological investigation of certain medicinal plants and compound formulations used in Ayurveda and Siddha, Central Council for Research in Ayurveda and Siddha. New Delhi, India: Yugantar Press, 1996, pp. 370-376.
12. Vaidya Arya MR. Sthaulya Cikitsa. (treatment of obesity) In: A Compendium of Ayurvedic Medicine, Principles and Practice, Sri Satyaguru Publication. New Delhi, India: A division of Indian Book Centre, 1999, pp. 335-339.
13. Joshi R, Kamat JP, Mukherjee T. Free radical scavenging reactions and antioxidant activity of embelin: biochemical and pulse radiolytic studies. *Chemico Biol Interact.* 2007; 167:125-134.
14. Dharmendra S, Ruchi S, Pahup S, Gupta RS. Effect of embelin on lipid peroxidation and free radical scavenging activity against liver damage in rats. *Basic Clin Pharmacol Toxicol.* 2009; 105: 243-248.
15. Bhandari U, Jain N, Pillai KK. Further studies on antioxidant potential and protection of pancreatic β -cells by *Embelia ribes* in experimental diabetes. *eXP Diabetes Res.* 2007; 1-6.
16. Bhandari U, Jain N, Ansari MN, Pillai KK. Beneficial effect of *Embelia ribes* ethanolic extract on blood pressure and glycosylated hemoglobin in streptozotocin induced diabetes in rats. *Fitoterapia* 2008; 79:351-355.
17. Sreepriya M, Bali G. Effects of administration of embelin and curcumin on lipid peroxidation, hepatic glutathione antioxidant defense and hematopoietic system during N-nitrosodiethylamine/phenobarbital-induced hepatocarcinogenesis in Wistar rats. *Mol Cellular Biochem.* 2006; 284: 49-55.
18. Ogbornia SO, Odimegwu JI, Enwuru VN. Evaluation of hypoglycemic and hypolipidemic effects of ethanolic extracts of *Treculia africana* Decne and *Bryophyllum pinnatum* Lam. and their mixture on streptozotocin (STZ) - induced diabetic rats. *African Journal of Biotech.* 2008; 7(15): 2535-2539.
19. Flodstrom M, Tyrberg B, Eizirik DL, Sandler S. Reduced sensitivity of inducible nitric oxide synthetase-deficient mice to multiple low-dose streptozotocin induced diabetes. *Diabetes* 1999; 48(4): 706-713.
20. Rao VS, Santos FA, Silva RM, Teixeira MG. Effects of nitric oxide synthetase inhibitor and melatonin on the hyperglycemic response to streptozotocin in rats. *Vascul Pharmacol.* 2002; 38(3): 127-130.
21. Sperling MA, Saunders PA. Diabetes mellitus in: Behrman RM, sKliegman HB. Jenson (Eds) Nelson text book of pediatrics, 2000, pp. 1767-1791.
22. Bhagavan NV. Metabolic homeostasis in: N.V. Bhagavan (Eds) Medical biochem Harcourt/Academic, Florida 2002; 485-519.
23. Ranganathan G, Li C, Kern PA. The translational regulation of lipoprotein lipase in diabetic rats involves the 3'-untranslated region of lipoprotein lipase mRNA. *J Biol Chem.* 2000; 275(40): 986-40991.
24. Ginsberg HN. Lipoprotein physiology in nondiabetic and diabetic states. Relationship to atherogenesis. *Diabetes care.* 1991; 14: 839-855.
25. Coppack SW, Jenson MD, Miles JM. *In-vivo* regulation of lipolysis in human. *J lipid Res.* 1994; 35: 177-193.
26. Ohno T, Horio F, Tanaka S, Terada M, Namikawa T, Kitoh J. Fatty liver and hyperlipidemia in IDDM of streptozotocin treated shrews. *Life Sci.* 2000; 66: 125-131.
27. Bopanna KN, Kannan J, Sushma gangil, Balaraman R, Rathod SP. Anti-diabetic and anti-hyperlipidemic effect of Neem, Lipidemic effect of Neem seed kernel powder on alloxan diabetic rabbits. *Ind J Pharmacol.* 1997; 29: 162-167.