



Aggressive Inflammatory Myofibroblastic Tumor of the Urinary Bladder in Children

Janet E. Baack Kukreja, Jennifer Gordetsky, Jimena Cubillos, Robert A. Mevorach, Ronald Rabinowitz, William C. Hulbert

Abstract Inflammatory myofibroblastic tumor (IMT) of the genitourinary tract is a well-known entity. The majority of the literature characterizes IMT of the bladder as a benign, slow growing tumor in children. We present two cases of aggressive IMT. Although rhabdomyosarcoma is more common, IMT should remain within the differential diagnosis for any bladder mass found in a child or young adult. The diagnosis of IMT is important in preventing unnecessary diagnostic procedures and guiding the appropriate treatment.

Key Words Inflammatory Myofibroblastic Tumor; urinary bladder; children; non-bacterial cystitis; hematuria; pseudosarcomatous myofibroblastic proliferation

© 2014 pediatricurologycasereports.com. All Rights Reserved

From the Department of Urology, Division of Pediatric Urology, University of Rochester Medical Center. Department of Pathology, Johns Hopkins Medical Institutions, Baltimore, Chesapeake Urology Associates, Owings Mills.

Corresponding Author: Janet E. Baack Kukreja, M.D.
Department of Urology, University of Rochester Medical Center
601 Elmwood Avenue, Box 656 Rochester, NY 14642, USA
E mail: janet_kukreja@urmc.rochester.edu

Accepted for publication 24 June 2014

INTRODUCTION

Inflammatory myofibroblastic tumor (IMT) of the genitourinary tract is a well-known

entity with over 130 case reports in the pediatric literature. Although IMT can involve all parts of the genitourinary tract, bladder is the most common site. The majority of the literature characterizes IMT of the bladder as a benign, slow growing tumor in children [1]. We present two cases

of aggressive IMT and a review of the literature.

CASE REPORT

Our first case presented in a 6 year old female with non-bacterial cystitis and a two week history of gross hematuria. Her past medical history was significant for a recent diagnosis of Streptococcal pharyngitis. Upon admission, urine culture was negative, ASO titer was 800, and erythrocyte sedimentation rate was 51, suspicious for post-streptococcal glomerulonephritis. Ultrasound of the bladder showed a vascular lesion measuring 13.5 x 7.5 x 5.0 cm. Subsequent CT scan revealed an enhancing mass that appeared to be emanating from the trigone of the bladder. As part of a metastatic workup the patient underwent a bone scan and a CT scan of the chest, both of which were negative. Cystoscopy and transurethral biopsy was performed in the operating room. A frozen section was obtained at the time of surgery, which revealed a preliminary diagnosis of rhabdomyosarcoma. Given this diagnosis,

the patient underwent bone marrow biopsy, placement of a Hickman catheter, and an open partial cystectomy. The final diagnosis on permanent section was IMT. A second opinion was obtained from an outside institution, confirming the diagnosis of IMT. The patient was still free of recurrence after two years.

Our second case presented in an 11 year old female with lower abdominal pain, dysuria, and microscopic hematuria. Initial workup revealed a positive culture for streptococcal pharyngitis.

In addition, CT scan (Fig. 1.A) revealed a 1.0 x 0.5 x 0.5 cm bladder mass. The patient was scheduled for follow up in a month with a bladder ultrasound. However, two weeks later the patient developed gross hematuria and severe dysuria for which she required admission. Ultrasound revealed an increase in the size of the bladder mass to 5.6 x 5.0 x 4.3 cm (Fig. 1.B). The patient was taken to the operating room for an endoscopic transurethral biopsy of the bladder mass. Frozen section biopsy demonstrated a

reactive spindle cell lesion, suspicious for IMT. Gross examination revealed a tan-white mass infiltrating the wall of the bladder (Fig. 1.C). Permanent sections revealed an infiltrate of large, plump, elongated spindled cells with abundant eosinophilic cytoplasm in a myxoid stroma, consistent with IMT (Fig. 1.D). Tumor cells had bland appearing nuclei without atypical or hyperchromasia. Chronic inflammatory cells were scattered throughout the lesion. No atypical mitotic figures were present. Tumor cells in both cases showed positive staining for ALK, which is seen in up to 60% of IMT [2].

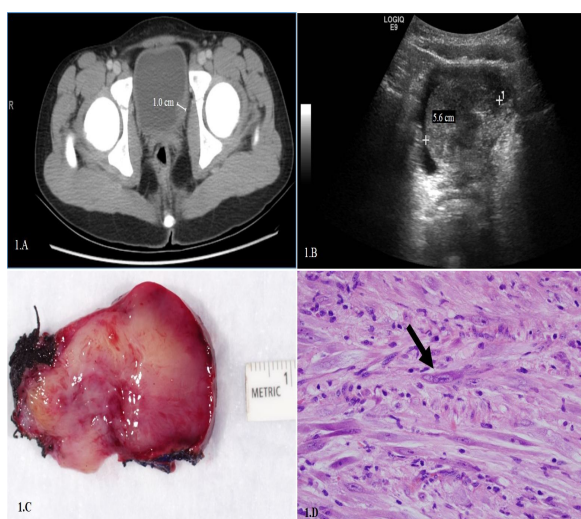


Fig. 1.A. Initial CT scan showing a 1.0 x 0.5 cm bladder wall mass. **1.B.** Ultrasound five weeks from initial presentation, showing the bladder mass had grown to 5.6 x 5.0 x 4.3 cm. **1.C.** Histology showing

an inflammatory myofibroblastic tumor showing an infiltrate of large, plump, elongated spindled cells with bland cytology in a myxoid background. **1.D.** Myofibroblastic inflammatory tumor, showing an infiltrative tan-white mass in the wall of the bladder.

In both cases tumor cells were negative for myogenin, excluding rhabdomyosarcoma. The patient underwent an open partial cystectomy and was free of recurrence after eighteen months.

DISCUSSION

IMT can be found anywhere in the genitourinary tract and has been well reported in children and adolescents. We found 45 cases of IMT described in the bladder, the findings of which are summarized in Table 1.

There were 23 female patients and 22 male patients, ranging from 6 months to 17 years old. Gross hematuria and dysuria were the most common presenting symptoms. Tumor ranged in size from 0.5 cm to 13 cm. In contrast to previous reports, our cases exhibited significant symptoms and rapid growth. Most cases were often treated with partial cystectomy and more recently with

endoscopic transurethral resection.

Author	Year Pub.	# of pts	Age (yrs)	Sex (#)	Symptoms	Treatment (#)	Size (cm)	F/U (mo)	Unnecessary diagnostic testing treatment
Lecuona ⁵	2012	1	3	M	GH, LUTS	LE PC	8.2 x 5.6	7	
Houben ²	2007	1	10	F	LUTS	PC		6	Bone scan, BM bx
Fletcher ⁵	2007	1	6	M	LUTS Pain	PC	10 x 13	22	
Mergan ⁶	2005	3	7 15 6	F M F	GH	PC		24 60 2	
Schneider ⁷	2001	2	14 3	M M	GH LUTS	PC	6x6 4x4		Chemo for rhabdomyosarcoma
Meyer ⁸	2000	1	3	F	GH, LUTS	PC	3x4	9	Bone scan BM bx
Netto ⁹	1999	3	4 12 7	M M F	GH LUTS Pain	LE PC	4.5 2	4 10 42	
Gardner ¹⁰	1999	1	3	M	LUTS Pain	PC	4.7x4.5	3	OR for appendectomy
Lakshmanan ¹¹	1997	1	4	M	GH LUTS Pain	PC	6x5	4	
Foschini ¹²	1995	2	2 4	M M	GH	LE	0.5-3	96 48	
Hojo ¹³	1995	10	Med. age 7	M (6) F (4)	GH	LE (x2) PC (x8)		Med. 24	
Ablores-Saavedra ¹⁴	1990	10	Med. age 7	M (2) F (8)	GH LUTS	PC (x2) TC (x2) LE (x6)		Med. 24	

Pub.-published, Pts-patients, Med.-median, GH-gross hematuria, LUTS-lower urinary tract symptoms, LE-local excision (endoscopic), PC-partial cystectomy, TC-total cystectomy, Bx-biopsy, M-months

Table 1. Pertinent cases from literature review.

There were 23 female patients and 22 male patients, ranging from 6 months to 17 years old. Gross hematuria and dysuria were the most common presenting symptoms. Tumor ranged in size from 0.5 cm to 13 cm. In contrast to previous reports, our cases exhibited significant symptoms and rapid growth. Most cases were often treated with partial cystectomy and more recently with endoscopic transurethral resection.

Without a high suspicion of IMT, unnecessary procedures were reported in other cases including bone marrow biopsies, radiographic imaging, and chemotherapy. Pathologic diagnosis and high suspicion for IMT are imperative for rapid and appropriate treatment.

Additionally it should be noted this is the first report with urinary bladder IMT and a possible association with streptococcal pharyngitis. This should be looked for in the future to see if there is any correlation.

Although rhabdomyosarcoma is more common, IMT should remain within the differential diagnosis for any bladder mass found in a child or young adult. The diagnosis of IMT is important in preventing unnecessary diagnostic procedures and guiding the appropriate treatment.

CONFLICT OF INTEREST

None declared.

REFERENCES

1. JA. Reactive pseudosarcomatous response in urinary bladder. *Urology*. 1980;16:635-7.

2. Montgomery EA, Shuster DD, Burkart AL et al. Inflammatory myofibroblastic tumors of the urinary tract: a clinicopathologic study of 46 cases, including a malignant example inflammatory fibrosarcoma and a subset associated with high-grade urothelial carcinoma. *Am J Surg Pathol.* 2006;30:1502-12.
3. Lecuona AT, Van Wyk AC, Smit SG, Zarrabi AD, Heyns CF. Inflammatory myofibroblastic tumor of the bladder in a 3-year-old boy. *Urology.* 2012;79:215-8.
4. Houben CH, Chan A, Lee KH, Tam YH, To KF, Cheng W, Yeung CK. Inflammatory myofibroblastic tumor of the bladder in children: what can be expected? *Pediatr Surg Int.* 2007;23:815-9.
5. Fletcher SG, Galgano MT, Michalsky MP, Roth JA. Regression of inflammatory pseudotumor of the bladder in a child with medical management. *Urology.* 2007;69:982.e11-2.
6. Mergan F, Jaubert F, Sauvat F, Hartmann O, Lortat-Jacob S, Révillon Y, et al. Inflammatory myofibroblastic tumor in children: clinical review with anaplastic lymphoma kinase, Epstein-Barr virus, and human herpesvirus 8 detection analysis. *J Pediatr Surg.* 2005;40:1581-6.
7. Schneider G, Ahlhelm F, Altmeyer K, Aliani S, Remberger K, Schoenhofen H, et al. Rare pseudotumors of the urinary bladder in childhood. *Eur Radiol.* 2001;11:1024-9.
8. Meyer S, Bruce J, Kelsey A, Eden OB. Pseudosarcoma of the bladder associated with residual urachus in a 3-year-old girl. *Pediatr Surg Int.* 2000;16:604-6.
9. Netto JM, Pérez LM, Kelly DR, Joseph DB. Pediatric inflammatory bladder tumors: myofibroblastic and eosinophilic subtypes. *J Urol.* 1999;162:1424-9.

10. Gardner MP, Lowichik A, Cartwright PC. Inflammatory (pseudosarcomatous) myofibroblastic tumor of the urinary bladder causing acute abdominal pain. *J Pediatr Surg.* 1999;34:1417-9.
11. Lakshmanan Y, Wills ML, Gearhart JP. Inflammatory (pseudosarcomatous) myofibroblastic tumor of the bladder. *Urology.* 1997;50:285-8.
12. Foschini MP, Scarpellini F, Rinaldi P, Mancini AF, Accinelli G, Eusebi V. Inflammatory pseudotumor of the urinary bladder. Study of 4 cases and review of the literature. *Pathologica.* 1995;87:653-8.
13. Hojo H, Newton WA Jr, Hamoudi AB, Qualman SJ, Wakasa H, Suzuki S, Jaynes F. Pseudosarcomatous myofibroblastic tumor of the urinary bladder in children: a study of 11 cases with review of the literature. An Intergroup Rhabdomyosarcoma Study. *Am J Surg Pathol.* 1995;19:1224-36.
14. Albores-Saavedra J, Manivel JC, Essendorf H, Dehner LP, Drut R, Gould E, et al. Pseudosarcomatous myofibroblastic proliferations in the urinary bladder of children. *Cancer.* 1990;66:1234-41.