



## A child with a large bladder stone: A case report

Hulya Ozturk, Emine Dagistan, Ugur Uyeturk

**Abstract** Bladder stones account for approximately 5% of all urinary system stones and are prevalent among children living in poor or rural regions. The symptoms and findings in children with bladder stones are usually urgency, frequency, incontinence, dysuria, pyuria, difficulty voiding, and fever, small caliber of urinary stream, lower abdominal pain and urinary intermittency. Most bladder stones are composed of calcium oxalate, followed by calcium phosphate, and they are usually larger than 2.5 cm in diameter. We present a case of a larger-than 2.5-cm bladder stone in a child.

**Key Words** Urinary system stones; bladder stones; obstruction; management.

© 2014 [pediatricurologycasereports.com](http://www.pediatricurologycasereports.com). All Rights Reserved

*From the Department of Pediatric Surgery, Radiology and Urology, Abant Izzet Baysal University, Medical School, Bolu, Turkey. Corresponding Author: Hulya Ozturk-Associate Prof, M.D. Abant Izzet Baysal University, Medical School, Department of Pediatric Surgery, Bolu, Turkey  
E mail: [hulya\\_ztrk@yahoo.com](mailto:hulya_ztrk@yahoo.com)  
Accepted for publication 20 June 2014*

### INTRODUCTION

Bladder stones occur for reasons such as infravesical obstruction, neurogenic voiding dysfunction, urinary tract infection, foreign bodies and metabolic risk factors. Bladder stones account for approximately 5% of all urinary system stones and are prevalent

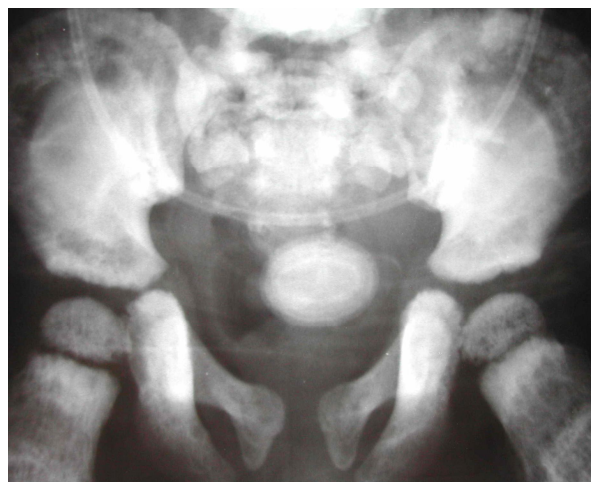
among children living in poor or rural regions [1-3]. Urinary system stones remain an endemic problem in a number of developing or underdeveloped countries in Africa and Asia [4, 5]. The symptoms and findings in children with bladder stones are usually urgency, frequency, incontinence, dysuria, pyuria, difficulty voiding, small caliber of urinary stream, lower abdominal pain and urinary intermittency, with fever reported in about 20-50% of these children [6]. Additionally, microscopic or

macroscopic hematuria in children with bladder stones has been noted in 33-90% of patients [4, 5]. Most bladder stones are composed of calcium oxalate (45-65%), followed by calcium phosphate (14-30%), and they are usually larger than 2.5 cm in diameter [7-10]. In this report, we present a case of a larger-than 2.5-cm bladder stone in a child.

### CASE REPORT

A 9-year-old male child presented to our medical service with suprapubic pain. The patient had a history of recurrent lower urinary tract infections. He had had urinary frequency, urgency, difficulty voiding, small caliber of urinary stream, lower abdominal pain, urinary intermittency and hematuria for one year. There was no family history of urinary stone disease. Physical examination revealed mild tenderness. On laboratory studies, blood urea nitrogen and serum creatinine levels were 98 mg/dL and 9.1 mg/dL, respectively. Hemogram showed leukocytosis. Renal ultrasound showed bilateral moderate-to-severe hydronephrosis. *Escherichia coli* growth was confirmed by

urine culture. X-ray revealed a large, round calcified pelvic calculus measuring 3.9 x 2.8 x 3.3 cm (Fig. 1).



**Fig. 1.** Plain abdominal film revealed a large stone in the bladder.

Broad-spectrum parenteral antibiotics were given according to culture sensitivity, and the patient underwent open cystolithotomy. An elliptical bladder stone was delivered smoothly (Fig. 2).



**Fig. 2.** A elliptical bladder stone was extracted by open vesicolithotomy.

The composition of the stone was reported as magnesium ammonium phosphate. The postoperative period was uneventful, and in the 6 months since the operation, the patient has remained symptom-free and has experienced no further stone formation.

## DISCUSSION

Urolithiasis in children is less commonly due to metabolic or congenital abnormalities. Bladder stones in developing nations are more commonly endemic in children because of dehydration, infection and a low-protein diet. Calcium-based stones in Western countries are relatively rare in the upper tract [9]. Bladder stones are usually rounded and may occur as singles or multiples. They can be small, or can be large enough to occupy the entire bladder. Bladder stones reach up to 5 cm in diameter in some parts of Asia. In a clinical study [11], 6.8% of urinary stones were bladder stones. Basaklar and Kale [5] reported that 26.5% of urinary tract stones were bladder stones. In 120 Tunisian children with urolithiasis, 22%

of bladder stones were composed of struvite [12].

The cause of urinary bladder stone formation in children is a diet that is low in animal proteins and consists mainly of cereals. Other factors include dehydration and a dietary phosphate deficiency. Bladder stones develop when urine becomes concentrated in the bladder, causing minerals in the urine to crystallize. Concentrated, stagnant urine is often the result of an inability to completely empty the bladder. Pediatric bladder stones most commonly consist of ammonium acid urate with or without calcium oxalate or calcium phosphate. Certain types of infections may cause the development of urinary stones. These infections produce an enzyme called urease, which causes the urine pH to increase, favoring the formation of magnesium ammonium phosphate (struvite) crystals. Some calcium crystals can also form. Frequently, large, difficult-to-treat staghorn stones develop. Infections agents

associated with urinary stones are *E. coli*, *Proteus sp.*, *Providencia sp.*, and some strains of *Klebsiella sp.*, *Pseudomonas sp.*, and *Enterococci* [3, 10, 13, 14]. In the present case, the urine culture grew *E. coli*. Based on our patient's family history, a hereditary calcium oxalate metabolic disorder was unlikely.

Recent improvements in the socio-economic facilities of some regions have changed the clinical appearance of all urinary stones. In Dubai [1], calcium oxalate was found in 78% of patients with bladder calculi, and acute urinary obstruction was a symptom of bladder stones. In Saudi Arabia [15], calcium oxalate stones were the most common type, followed by uric acid and phosphate stones. In Thailand, oxalate was found in upper urinary tract stones, and uric acid stones were found in the lower urinary tract [16].

Currently, abdominopelvic planar radiography is commonly used to identify radiopaque stones in children. Additionally, ultrasonography, intravenous pyelography

(IVP) and computed tomography (CT) are used for evaluation of these stones [1,4,14]. Bladder stones are usually single, large, rounded, and of homogeneous calcific density and thus are evident on plain radiograph or on excretion urography or cystography with a contrast agent. Ultrasonography is very helpful in confirming or detecting bladder stones [17]. Bladder stones do not always cause signs or symptoms and may be discovered during tests for other problems. When symptoms do occur, they can range from abdominal pain to blood in the urine. If bladder stones are small enough, they can pass on their own with no noticeable symptoms. Left untreated, bladder stones can cause infection, inflammatory edema, detrusor spasms and other complications. However, once they become larger, bladder stones can cause frequent urges to urinate, painful or difficult urination and hematuria. These stones can irritate the bladder wall, disrupt the flow of urine out of the bladder and cause infection [1, 17, 18].

The presentation of vesical calculi ranges from a complete absence of symptoms to the presence of suprapubic pain in 50% of cases, dysuria, intermittency, frequency, hesitancy, nocturia, and urinary retention. Parents of children with vesical calculi may notice priapism and occasional enuresis. Other common signs include terminal gross hematuria in 33-90% of children and sudden termination of voiding with some degree of associated pain referred to the tip of the penis, scrotum, perineum, back or hip.

Based on a literature survey of a total of 447 cases of bladder stones, management consisted of open vesicolithotomy in 307 cases (68.7%), extracorporeal short-wave lithotripsy in 63 cases (14.1%) and transurethral pneumatic cystolithotripsy in 77 cases (17.2%). The decision between endoscopic or open cystolithotomy depends on the size and number of the stones. If the stones are too large (>2.5 cm in diameter) or too numerous to be removed by endoscopic methods, open surgical removal may be

**CONFLICT OF INTEREST**

necessary. Open surgery is the preferred treatment of choice for removing bladder stones, and surgical intervention through cystolithotomy can achieve satisfactory results. Bladder outlet obstruction should be treated simultaneously. Early diagnosis and early treatment are necessary [8, 19-21].

In our case, the bladder stone was more than 3 cm in diameter and open vesicolithotomy was chosen. The postoperative period was uneventful, and in the 6 months since the operation, the patient has remained symptom-free and has experienced no further stone formation.

Large bladder stones can cause severe symptoms in children. Patients at risk for bladder stones in endemic regions should undergo periodic evaluation, at least with ultrasonography. Additionally, changes in the diet are needed to prevent the recurrence of bladder stones. It is very important to recognize that long-term pyuria and urinary symptoms can lead to large bladder stones and renal failure.

**None declared.**

**REFERENCES**

1. Hammad FT, Kaya M, Kazım E. Bladder calculi: did the clinical picture change? *Urology*. 2006; 67:1154–8.
2. Rahman M, Uddin A, Das GC, Akanda NI. A giant vesical calculus. *Mymensingh Med J*. 2007; 16 (2 Suppl):S57–59.
3. Hızlı F, Yılmaz E. A giant bladder struvite stone in an adolescent boy. *Urol Res*. 2012; 40:273–4.
4. Gillespie RS, Stapleton FB. Nephrolithiasis in children. *Pediatr Rev*. 2004;25:131–9.
5. Basaklar AC, Kale N. Experience with childhood urolithiasis: report of 196 cases. *Br J Urol*. 1991;67:203–5.
6. Chow KS, Chou CY. A Boy with a Large Bladder Stone. *Pediatr Neonatol*. 2008;49:150–3.
7. Erbagci A, Erbagci AB, Yılmaz M, et al. Pediatric urolithiasis—evaluation of risk factors in 95 children. *Scand J Urol Nephrol*. 2003;37:129–33.
8. Rizvi SAH, Naqvi SA, Hussain Z, et al. Pediatric urolithiasis: developing nation perspectives. *J Urol*. 2002;168:1522–5.
9. Trinchieri A. Epidemiology of urolithiasis: an update. *Clin Cases Miner Bone Metab*. 2008;5:101-6.
10. Wei W, Wang J. A huge bladder calculus causing acute renal failure. *Urol Res*. 2010; 38:231–2.
11. Gault MH, Chafe L. Relationship of frequency, age, sex, stone weight and composition in 15,624 stones: comparison of results for 1980 to 1983 and 1995 to 1998. *J Urol*. 2000;164:302-7.
12. Kamoun A, Daudon M, Abdelmoula J, et al. Urolithiasis in Tunisian children: a study of 120 cases based on Stone composition. *Pediatr Nephrol*. 1999;13:920– 5; discussion 926.
13. Stamey TA. Pathogenesis and treatment of urinary tract infections. Baltimore: Williams & Wilkins, 1980:430-474.
14. Sikora P, Glatz S, Beck BB, Stapenhorst L, Zajackowska M, Hesse A, Hoppe B.

- Urinary NAG in children with urolithiasis, nephrocalcinosis, or risk of urolithiasis. *Pediatr Nephrol.* 2003;18:996-9.
15. Khan AS, Rai ME, Gandapur, Pervaiz A, et al. Epidemiological risk factors and composition of urinary stones in Riyadh Saudi Arabia. *J Ayub Med Coll Abbottabad.* 2004;16:56-8.
16. Tanthanuch M, Apiwatgaroon A, Pripatnanont C. Urinary tract calculi in southern Thailand. *J Med Assoc Thai.* 2005;88:80-5.
17. Lebowitz RL, Vargas B. Stones in the urinary bladder in children and young adults. *AJR Am J Roentgenol.* 1987;148:491-5.
18. Ho K, Segura J. Lower Urinary Tract Calculi. In: Wein A, Kavoussi L, Novick A, Partin A, Peters C (eds). *Campbell-Walsh Urology.* 3. 9th. Philadelphia, Pa: Saunders Elsevier; 2007. pp. 2663-73.
19. Rodrigues Netto N Jr, Longo JA, Ikonomidis JA, Rodrigues Netto M. Extracorporeal shock wave lithotripsy in children. *J Urol.* 2002;167:2164-6.
20. Salah MA, Holman E, Toth C. Percutaneous suprapubic cystolithotripsy for pediatric bladder stones in a developing country. *Eur Urol.* 2001;39:466-70.
21. Smith JM, O'Flynn JD. Transurethral removal of bladder stone: the place of litholapaxy. *Br J Urol.* 1977;49:401-5.