

A Case study of a Rare Case of Turner's Hypoplasia and Unilaterally Fused Deciduous and Permanent Lateral Incisor Caused By Trauma

Verma, Leena

Sr. Asst. Prof., Dr. H.S. Judge Institute of Dental College, Punjab University, Chandigarh

Abstract

Orofacial trauma is a serious orodental and general health problem that may have medical, esthetic and psychological consequences for children and their parents. When the root of the primary tooth is close to the unerupted permanent tooth, primary tooth trauma may result in developmental disturbances and pulpal reaction in that permanent tooth. We report an unusual case of an 8 year old girl who met with trauma at 15 months of age in which injury to the primary dentition resulted in developmental disturbances in the crown of the permanent tooth and fusion between permanent and deciduous tooth. Localized malformation of the crown and enamel hypoplasia was treated with a light-cured composite resin restoration. The treatment of fused permanent and deciduous incisor is also discussed.

Introduction

Hypoplasia is defined as a quantitative defect of enamel visually and is histomorphologically identified as an external defect involving the surface of the enamel and associated with reduced thickness of enamel (*Ozturk et al, 2004*). Turner's hypoplasia usually manifests as a portion of missing or diminished enamel, generally affecting one or more permanent teeth in the oral cavity. If it involves anterior teeth, most likely cause is traumatic injuries leading to primary incisors being knocked out or driven into the alveolus affecting the permanent tooth bud. The affect of trauma are more pronounced if it occurs prior to third year of life. The topographic relationship of the primary teeth to the permanent tooth germ explains the potential for possible developmental disturbances

(*Andreasen & Andreasen, 1994*). The developmental defects of the permanent successor tooth range from mild alteration in enamel mineralization in form of simple white or yellow brown discoloration to crown dilaceration, crown duplication, root dilaceration, root duplication, odontome like malformation, disturbed eruption, partial or complete arrest of root formation to severe sequestration of the developing tooth germ (*Andreasen & Andreasen, 1994, Shafer, 2007*). Hypoplasia was categorized into the following types by *Silberman et al (2010)* Type I hypoplasia: Enamel discoloration, Type II hypoplasia (Abnormal coalescence), Type III hypoplasia (Some parts of enamel missing due to hypoplasia) & Type IV hypoplasia: A combination of previous three types of hypoplasia. According

to them both dentitions could be affected by enamel hypoplasia; however, the incidence is more severe in permanent dentition. The characteristics of clinical enamel hypoplasia include unfavorable esthetics, higher dentin sensitivity, malocclusion and dental caries susceptibility (White & Pharaoh, 2006). The treatment challenge in this type of injury is to promote a complete oral rehabilitation in both esthetics and function.

A case report of a 8-year-old female patient with chief complaint of anterior malformed teeth and abnormally large teeth in upper left maxillary region following a traumatic injury while playing is presented below.

CASE REPORT

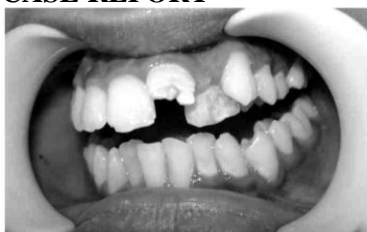

Fig. 1.

An 8-year-old female patient reported to the Department of Pedodontics and Preventive Dentistry with chief complaint of anterior malformed teeth and abnormally large teeth in upper left maxillary region. On clinical examination, the maxillary left central incisor showed yellowish brown discoloration with type IV enamel hypoplasia (enamel discoloration, abnormal coalescence, some parts of enamel missing) and left permanent lateral incisor was fused with deciduous lateral incisor (Figure 1).

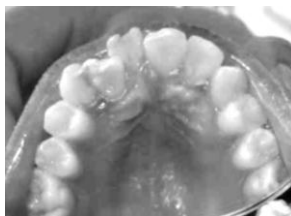

Fig. 2

The incisal aspect of the turner hypoplastic tooth showed a portion of missing or diminished enamel and the fused deciduous and permanent lateral incisor showed an extra cusp on the labial surface and talons cusp palatally (Figure 2).

The maxillary central incisor (hypoplastic tooth) was not tender on percussion and no caries was detected clinically. Patient had a history of trauma at the age of 15 months, followed by avulsion of left central incisor and intrusion of left lateral incisor. Her medical history was irrelevant with his condition. Intraoral Periapical Radiograph (IOPA) showed fusion of permanent left lateral incisor with deciduous left lateral incisor and diminished or missing enamel on left central incisor. (Figure 3)

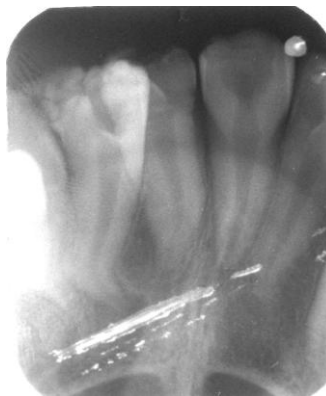

Fig. 3

The fused teeth <22-62> had an irregular labial and lingual surface with an incisal ditch with a labial groove. Both the

fused teeth were also caries free. The periapical radiograph exhibited that only the crowns of <22-62> were fused with non union of their pulp chambers and root canals. The pulp chamber of deciduous lateral incisor was resorbed and there was fusion of enamel only with permanent lateral incisor. Occlusal view revealed aberrant morphology of permanent left lateral incisor and also the presence of irregular surface of left central incisor (Figure-4).

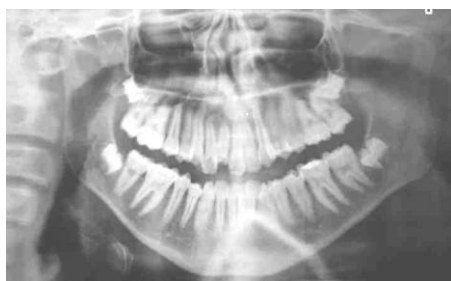


Fig. 4

Orthopantomogram confirmed the presence of fusion in deciduous and permanent left lateral incisor and Turner hypoplasia in left central incisor along with normal set of complementary teeth (Figure-5).

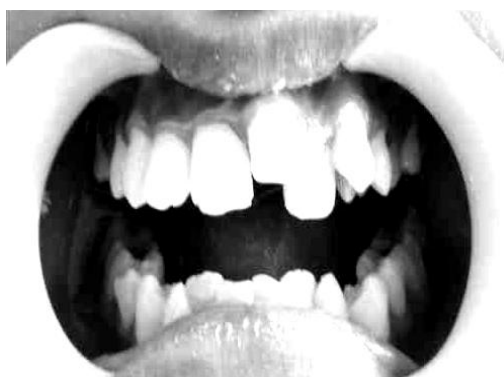

Fig. 5

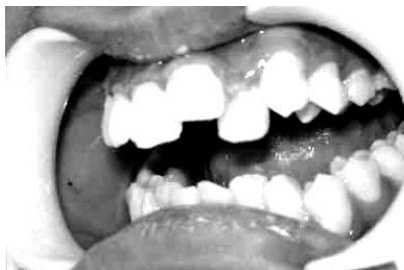

Fig. 6

A multidisciplinary approach was adopted for the management of the case. Esthetic treatment with palatal contouring and light cure composite restoration was performed on left central incisor. Composite build up was done for the proper shape of the teeth. Since the fusion of deciduous and permanent teeth was of only crown, therefore selective grinding of the resorbed crown of deciduous lateral incisor was done to give proper shape to permanent lateral incisor and keep the patient on regular follow up. (Figure 6)

Discussion

Hypoplasia is a disturbance that occurs at the time when teeth are developing and is associated with macroscopic enamel defects. Traumatic injuries to the primary dentition are very common, affecting from 4-30% of all children (Velasco, *et al*, 1997). If a traumatic injury occurs to a deciduous tooth during the period when the crown of the succeeding permanent tooth is being formed, there occurs disturbance in the ameloblastic layer of the permanent tooth and result in a hypoplastic tooth. The effect of trauma is more pronounced if it occurs prior to third year of life. This was first discovered by Turner in 1912. These single teeth are called Turner's teeth and the condition is called Turner's Hypoplasia. Diana Ribeiro *et al* (2009)

reported from their longitudinal study of 8 years that discolorations of enamel and/or enamel hypoplasia (46.08%) were the most prevalent sequelae on permanent dentition due to traumatic injury.⁷

Tooth fusion is defined as union between the dentin and/ or enamel of two or more separate developing teeth.^{1,2} The fusion may be partial or total depending upon the stage of tooth development at the time of union. If the contact occurs before the calcification stage, the teeth unite completely and form one large tooth. Incomplete fusion may be at root level if the contact and union occurs after formation of crown. Fusion can occur at the level of enamel or enamel and dentin, which results in the formation of one clinically enlarged crown. Fused teeth can have separated pulpal space, one pulp chamber and two canals or take the form of a large bifid crown with one pulpal space. Etiology of fusion is not fully explained. Some authors state that it is a result of physical forces that lead to the necrosis of epithelial tissue between the two joining buds, they come into contact and fuse.^{5, 6} According to other authors, fusion is a result of the persistence of the interdental lamina between the two buds during embryological development. Fusion may be unilateral or bilateral and most commonly occurs in primary teeth with more predilection for anterior teeth.⁷ Fusion may occur between two normal teeth or between a normal tooth and a supernumerary tooth. Clinically fused anterior teeth frequently have a groove or notch on the incisal edge that goes in buccolingual direction and radiographically, the dentin of fused teeth

always appears to be joined in some region with separate pulp chambers and canals.

In the rare case report we reported here, the patient had a history of trauma in their deciduous dentition below the age of 3 years and had type-IV enamel hypoplasia (enamel discoloration, abnormal coalescence, some parts of enamel missing) along with fusion of deciduous left lateral incisor and permanent left lateral incisor. The brown discoloration occurs due to disturbances in ameloblastic layer, leading to defective matrix formation caused by traumatic injuries, but the stretched inner enamel epithelium continues to induce the differentiation of new odontoblasts and hence the dentine formation is not disrupted. The fusion between deciduous lateral and permanent lateral incisor also occurred due to traumatic injury in the deciduous dentition which had led to fusion between the two teeth.

Thus, this a rare case report in which following trauma to deciduous dentition, there occurs fusion between deciduous lateral and permanent lateral incisor and Turner's hypoplasia in permanent central incisor. This is a rare occurrence not yet reported so far.

Conclusion: An injury to a young child's teeth can be physically and emotionally traumatic. The dentist must take time to carefully examine and analyze not only the damage itself, but also the possibilities of sequelae to the permanent tooth germ and the overall health of the child. For this reason, treatment of trauma in primary dentition must include long-term follow-up of sequelae in the permanent dentition. The case we report here stresses the importance of traumatic injuries to

primary dentition because of their effects on the permanent tooth germ.

References

- Ozturk, N, Zafar, S., Ozturk, B. 2004. Faculty of Dentistry, University of Selcuk, Konya, turkey. An interdisciplinary approach for restoring function and esthetic in patient with amelogenesis imperfecta and malocclusion: A clinical report. *J. Prosthetic Dentistry*, 92(2): 112-115.
- Andreasen, F.M. & Andreasen, J.O. 1994. *Textbook and color atlas of traumatic injuries to the teeth*. Mosby Co; p. 457-94.
- Shafer's textbook of oral pathology, 5 edition: page 75 Publisher: Elsevier 2007
- Golpaygani, V.M., Mehrdad, K., Mehrdad, A., Ansari, G. 2009. An evaluation of the rate of dental caries among hypoplastic and normal teeth: A case control study. *Res. J. Biol. Sci.*, 4: 537-41.
- White, S.C. & Pharaoh, M.J. 2006. Oral radiology Principles and Interpretation 5th edition page: 345-346. Publisher: Elsevier
- Velasco, L.F.L., Araujo, F.B, Ferreira, E.S., Velasco, L.E.L. 1997. Esthetic and functional treatment of a fused permanent tooth: A case report. *Quintessence Int.*, 28: 677-80.
- Andreasen, J.O. 1971. The effect of traumatic injuries to primary teeth on their permanent successor. *Scand. J. Dent. Res.*, 145: 229.
- do Espírito Santo Jácomo, D.R., Campos, V. 2009. Prevalence of sequelae in the permanent anterior teeth after trauma in their predecessors: a longitudinal study of 8 years. *Dent Traumatol.*, 25(3): 300-4.

