

# Laparobotic Duodenal Diverticulectomy: A Case Series and Operative Technique

Anuchit Lerstsirithong, M.D.\*, Thawatchai Akaraviputh, M.D.\*, Anusak Yiengpruksawan, M.D.\*\*

\*Department of Surgery, Faculty of Medicine Siriraj Hospital, Mahidol University, Bangkok 10700, Thailand,

\*\*The Valley Hospital, Ridgewood, NJ 07450, USA.

## ABSTRACT

**Objective:** Duodenal diverticulum is not uncommon but most are asymptomatic. Surgery is recommended only for the patients with symptoms. Although laparoscopic diverticulectomy can be done, it is often with significant difficulties due to inherent limitations of the laparoscopic technique and posterior location of the lesion. The advent of the robotic surgical technology with superior imaging and instrumentation may provide an alternative minimally invasive approach for this situation. We herein report our case series utilizing the daVinci Surgical System (dVSS) for duodenal diverticulectomy.

**Methods:** We retrospectively reviewed our robotic database for all duodenal procedures performed at a single institution (the Valley Hospital: VH). Only patients who underwent laparobotic duodenal diverticulectomy (LRDD) were included and their recorded videos reviewed. Data analyzed were patients' demographic, perioperative outcomes, and technical details. We used the daVinci Si (Intuitive Surgical Inc. Sunny Vale, Calif.) for all cases.

**Results:** 4 female patients underwent LRDD. All presented with abdominal pain. Diagnosis was made by CT scans or MRI with or without EGD. 3 patients had diverticula located in the second part of the duodenum (75%). Concomitant procedures (choledochoduodenostomy and CBD exploration) were performed in two patients. Mean operative time was 142.5 min. There was one complication but no mortality. Average length of stay was 4 days.

**Conclusion:** LRDD is feasible, efficient, and safe. The dVSS provides the surgeon improved visualization and enhanced dexterity to perform complex procedure.

**Keywords:** Duodenal diverticulum; duodenal diverticulectomy; robotic surgery; laparobotic duodenal diverticulectomy (Siriraj Med J 2017;69: 102-106)

## INTRODUCTION

Duodenal diverticulum was first reported by Chomel in 1710.<sup>1</sup> The true incidence of duodenal diverticula is unknown. However, published literature quote incidences ranging from 0.16% to 22%, depending on the diagnostic method.<sup>2-4</sup>

Most duodenal diverticulas are asymptomatic; and only 5% of patients experience symptoms resulting from complication.<sup>5</sup> Surgical treatment is recommended for symptomatic or complicated diverticulum.<sup>6</sup>

Several reports have described a laparoscopic approach for duodenal diverticula, with either diverticulectomy

or an inversion procedure.<sup>4,7-11</sup> However, because of the deep-seated and posterior location of the lesion and inherent disadvantages of laparoscopic approach that includes 2-D image, counter intuitive movement, and limited degree of freedom of movement of the instruments, these procedures can be frustrating and difficult. The advent of the daVinci Robotic Surgical System with a stable work platform, a magnified 3-dimensional image, and articulated instruments has provided an alternative MIS approach that allows more complex procedures to be performed with efficiency and safety.<sup>12,13</sup>

Correspondence to: Anusak Yiengpruksawan

E-mail: [yienga@me.com](mailto:yienga@me.com)

Received 30 December 2016 Revised 27 January 2017 Accepted 10 February 2017

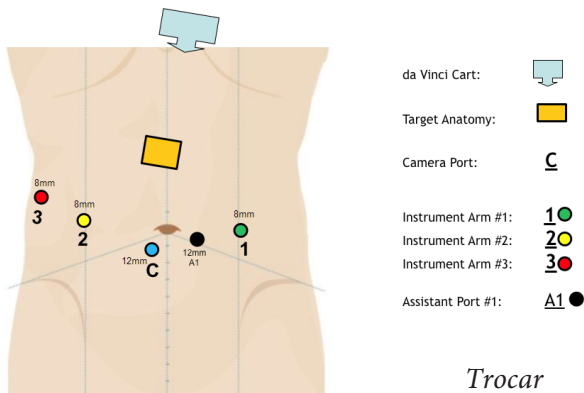
doi:10.14456/smj.2017.20

We herein report our experience utilizing the dVSS for duodenal diverticulectomy. Although we previously reported a case of robotic duodenal diverticulectomy,<sup>14</sup> to our knowledge, this is the first reported case series of LRDD to date.

**PATIENTS AND METHODS**

We retrospectively reviewed our prospectively collected robotic database for all duodenal procedures performed by one surgeon (AY) at a single institution (VH) from January 2008 to December 2015. Only patients who underwent laparoscopic duodenal diverticulectomy (LRDD) were included and their recorded videos reviewed for techniques and operative steps. Data analyzed were patients’ demographic, perioperative outcomes, and technical details. We used the daVinci Si (Intuitive Surgical Inc. Sunny Vale, Calif.) for all cases.

The robot setup and surgical steps are as follow:



ROBOTIC DUODENAL SURGERY

Fig 1. Trocar position

**ROBOTIC DUODENAL SURGERY**

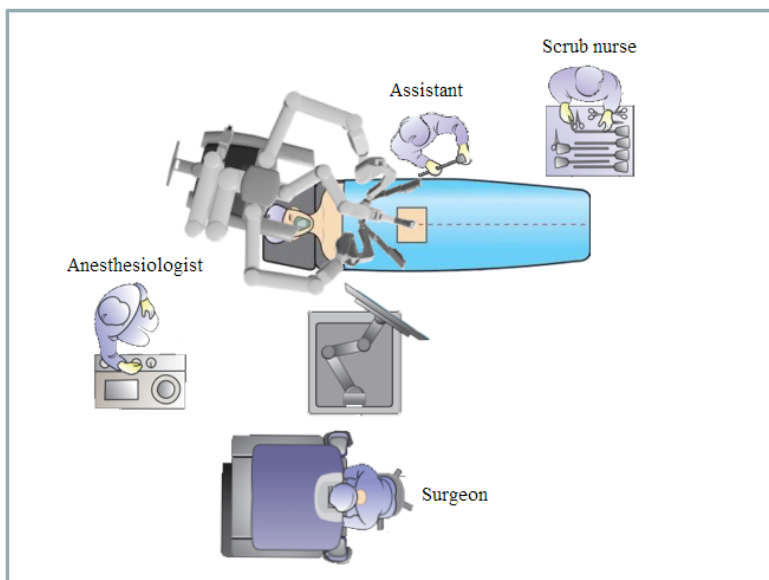


Fig 2. Robot setup

*Surgical steps*

Step 1: Extended Kocherization of the entire duodenum including the transverse third portion and pancreatic head.

Step 2: Identification and dissection of diverticulum - since the duodenal diverticulum is a herniation of duodenal mucosa/submucosa through the muscle defect; it is carefully dissected toward the duodenal wall until the neck of the diverticulum that lies between the separated muscles is identified (Fig 3).

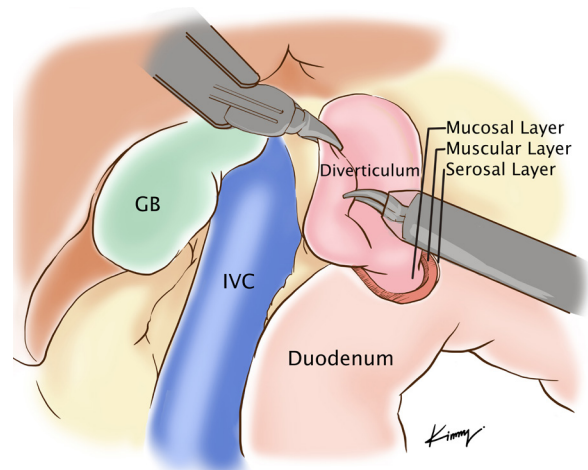
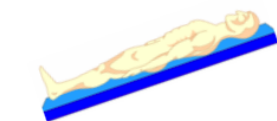


Fig 3. Dissection of diverticulum until neck of diverticulum.

Step 4: Transection of diverticulum at the neck by using laparoscopic linear stapler or with cautery and primary closure.

**Patient Position**



Reverse trendelenburg, supine



Tilt Left

Step 5: Approximation of duodenal wall defect (seromuscular layer) over the diverticular stump (Fig 4).

### RESULTS

There were 4 female patients with mean age of 64.5 years; and all presented with abdominal pain (Table 1). 2 patients also had jaundice, one from extrinsic compression by distended diverticulum (Fig 5) and the other from multiple common bile duct stones (Fig 6). Diagnosis was made by CT scan, MRI, and/or endoscopy. The diverticulum located in the second part of duodenum in 3 patients (75%). The largest size was 7 cm in diameter.

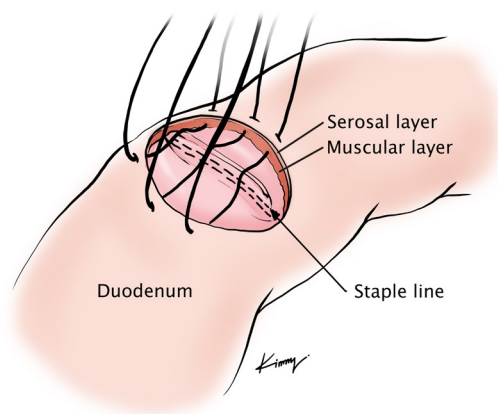


Fig 4. Approximation of duodenal wall defect.

TABLE 1. Demographic data.

| Patient no. | Gender | Age (yr.) | Clinical presentation                     | Diagnostic modality |
|-------------|--------|-----------|---|---------------------|
| 1           | F      | 78        | Epigastrium pain with cholestasis         | CT, EGD with EUS    |
| 2           | F      | 46        | Epigastrium pain                          | US, MRI, EUS        |
| 3           | F      | 84        | Abdominal discomfort and weight loss      | CT, MRI             |
| 4           | F      | 50        | Abdominal pain with intermittent diarrhea | MRI, EGD            |

**Abbreviations:** CT = Computerized Tomography, EGD = Esophagogastroduodenoscopy, EUS = Endoscopic Ultrasonography, MRI = Magnetic Resonance Imaging, US = Ultrasonography

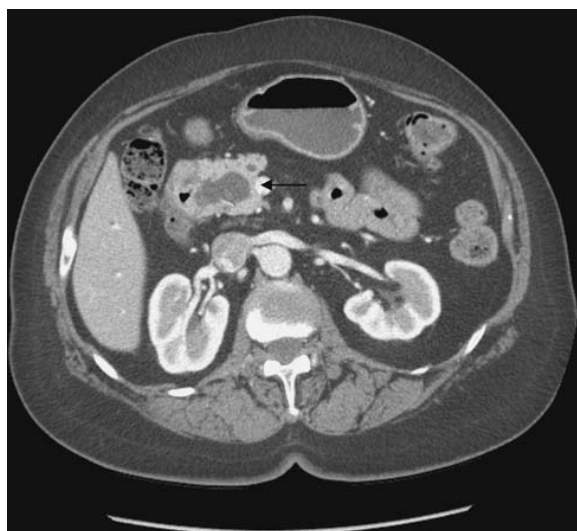

Fig 5. CT scan of abdomen revealing dilated common bile duct.

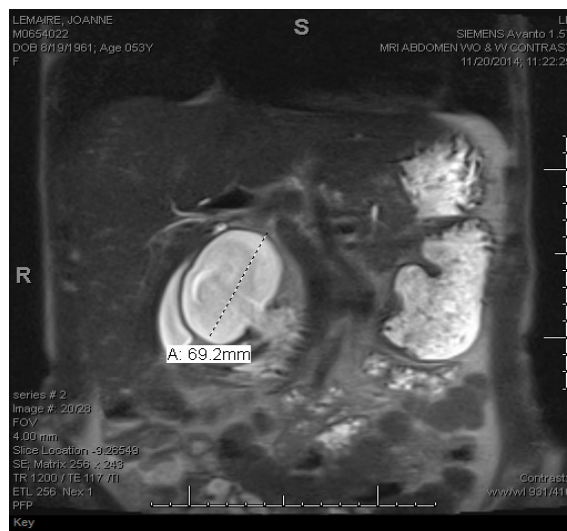

Fig 6. MRI revealed a large 7-cm diverticulum in the proximal 3<sup>rd</sup> part of duodenum.

Perioperative data and outcomes were summarized in Table 2. Two cases received concomitant procedure as choledochoduodenostomy and CBD exploration due to distal CBD obstruction. Mean operative time was

142.5 minutes and mean length of stay was 4 days. There was one postoperative complication from Clostridium difficile diarrhea, which was treated with Metronidazole.

**TABLE 2.** Perioperative data & outcomes.

| Patient no. | Operative time (min.) | Procedure  | LOS (days) | M&M                   |
|-------------|-----------------------|--|------------|-----------------------|
| 1           | 190                   | Diverticulectomy and choledochoduodenostomy                          | 6          | C. difficile diarrhea |
| 2           | 120                   | Diverticulectomy and cholecystectomy                                 | 3          | None                  |
| 3           | 160                   | Diverticulectomy, cholecystectomy, CBD exploration and stone removal | 4          | None                  |
| 4           | 100                   | Diverticulectomy   | 3          | None                  |

**Abbreviations:** LOS = Length of stay, M&M = Morbidity & Mortality, C. difficile = Clostridium difficile

## DISCUSSION

Duodenum is the second most common site of diverticula in the alimentary tract after the colon, followed by the jejunum, the ileum, and the stomach.<sup>15</sup> They are twice as prevalent in women and usually occur after the sixth decade. Duodenal diverticula (DD) can be classified into periampullary duodenal diverticula (PAD) and juxtampullary duodenal diverticula (JPDD). PAD are extraluminal mucosal out pouching of duodenum arising adjacent to or containing the ampulla of Vater or intraluminal portion of CBD. JPDD are defined as DD located within radius of 2 cm of major papilla, but not containing it.<sup>15</sup> The most common locations were the second portion (90%) and the medial wall (88%) of the duodenum and most are solitary.<sup>16</sup>

Although most patients with DD are asymptomatic, those with symptoms may present with abdominal pain, nausea, vomiting, diarrhea, steatorrhoea, and jaundice. Of the symptomatic patients, only 5% experience complications such as perforation. Contrast enhancing CT is currently the best imaging modality available and most sensitive for pre-operative diagnosis in perforated duodenal diverticulitis.<sup>17,18</sup>

Although surgery is generally not recommended for asymptomatic DD, it is the most effective treatment for complicated ones. Forsell and Key performed the first surgical treatment of duodenal diverticulum in 1915<sup>19</sup> followed by several others. The most common and effective treatment is diverticulectomy, which is accomplished by performing a wide Kocher maneuver that exposes the duodenum. The diverticulum is then excised, and the duodenum is closed in a transverse or longitudinal fashion, whichever produces the least amount of luminal obstruction. For the diverticulum that is embedded deep within the head of the pancreas, a duodenotomy is first performed. The diverticulum is identified, invaginated into the lumen, and then excised.

Since 1980, in an era of minimally invasive surgery, laparoscopic approach has gained increasing popularity among general surgeons. For duodenal diverticulum, laparoscopy has reportedly been used for both duodenal diverticulectomy and an inversion procedure. Callery et al. reported the first case of laparoscopic resection of the duodenal diverticulum with a stapler in 1994.<sup>9</sup> Subsequently Coelho et al. performed laparoscopic inversion of the duodenal diverticulum and closure of muscular defect.<sup>11</sup> Lee et al. reported laparoscopic diverticulectomy for a perforated duodenal diverticulum where the opening of the diverticulum was closed in 2 layers using intracorporeal hand-sewn sutures.<sup>7</sup> Recently, Dan et al. reported laparoscopic diverticulectomy for massive bleeding from duodenal diverticulum<sup>8</sup> and Pergel et al, reported laparoscopic diverticulectomy for treatment of a phytobezoar in the duodenal diverticulum.<sup>10</sup>

Despite the above laparoscopic success stories, laparoscopic approach for duodenal lesions remains out of reach for many general surgeons due to its long learning curve and inherent disadvantages of the visual platform and instruments. The advent of the dVSS has provided an alternative MIS approach that allows more surgeons to participate in complex procedures. The dVSS, unlike the laparoscopy, provides a stable visual platform, a magnified 3-dimensional high-resolution image, articulated instruments, intuitive hand-eye coordination, motion scaling, and better ergonomics. These advantages enhance surgeon's dexterity and precision and enable precise and time efficient intracorporeal maneuvers which are ideal for duodenal surgery.

We performed and reported our first LRDD in 2010<sup>14</sup> and have subsequently performed 3 others. We found the robotic approach to be beneficial for the difficult-to-reach area such as the second or third portion of the duodenum. It allowed us to perform LRDD with concomitant procedure such as choledochoduodenostomy

and CBD exploration without conversion. In one of our cases with PAD, we were able to avoid injuring the biliary and pancreatic ducts, which were close by, by carefully dissecting in the plane between the diverticular neck and the bilio-pancreatic tract until we could staple across the neck safely. This would have been exceedingly difficult with laparoscopy.

In conclusion, to our knowledge, this is the first case series of LRDD reported in the literature to date. LRDD is feasible, efficient, and safe provided that it is carefully planned and performed by an experienced robotic surgeon.

### Conflict of interest

The authors declare no conflict of interest.

### Funding

None

### Ethical approval

This paper is not a research study, but a case series which does not require ethical approval.

## REFERENCES

1. Chomel J. Report of a case of duodenal diverticulum containing gallstones. *Acad R Sci Paris* 1710;48-50.
2. Ackermann W. Diverticula and Variations of the Duodenum. *Ann Surg* 1943;117(3):403-13.
3. Leivonen MK, Halttunen JA, Kivilaakso EO. Duodenal diverticulum at endoscopic retrograde cholangiopancreatography, analysis of 123 patients. *Hepatogastroenterology* 1996;43(10):961-6.
4. Graur F, Bala O, Bodea R, Geczi-Toth I, Vlad L, Iancu C. Laparoscopic resection of duodenal diverticulum. A case report. *Rom J Gastroenterol* 2005;14(4):405-8.
5. Schnueriger B, Vorburger SA, Banz VM, Schoepfer AM, Candinas D. Diagnosis and management of the symptomatic duodenal diverticulum: a case series and a short review of the literature. *J Gastrointest Surg* 2008;12(9):1571-6.
6. Trondsen E, Rosseland AR, Bakka AO. Surgical management of duodenal diverticula. *Acta Chir Scand* 1990;156(5):383-6.
7. Lee HH, Hong JY, Oh SN, Jeon HM, Park CH, Song KY. Laparoscopic diverticulectomy for a perforated duodenal diverticulum: a case report. *J Laparoendosc Adv Surg Tech A* 2010;20(9):757-60.
8. Dan D, Bascombe N, Maharaj R, Hariharan S, Naraynsingh V. Laparoscopic diverticulectomy for massive hemorrhage in a duodenal diverticulum. *Surg Laparosc Endosc Percutan Tech* 2012;22(1):e39-41.
9. Callery MP, Aliperti G, Soper NJ. Laparoscopic duodenal diverticulectomy following hemorrhage. *Surg Laparosc Endosc* 1994;4(2):134-8.
10. Pergel A, Yucel AF, Aydin I, Sahin DA. Laparoscopic treatment of a phytobezoar in the duodenal diverticulum - Report of a case. *Int J Surg Case Rep* 2012;3(8):392-4.
11. Coelho JC, Sousa GS, Salvalaggio PR. Laparoscopic treatment of duodenal diverticulum. *Surg Laparosc Endosc* 1999;9(1):74-7.
12. Nguyen NT, Hinojosa MW, Finley D, Stevens M, Paya M. Application of robotics in general surgery: initial experience. *Am Surg* 2004;70(10):914-7.
13. Talamini MA, Chapman S, Horgan S, Melvin WS; Academic Robotics Group. A prospective analysis of 211 robotic-assisted surgical procedures. *Surg Endosc* 2003;17(10):1521-4.
14. Kella VK, Shakov E, Yiengpruksawan A. Laparoscopic duodenal diverticulectomy and choledochoduodenostomy: a case study and review of the literature. *J Robot Surg* 2010;3(4):249-52.
15. Mahajan SK KR, Chandel UK, Mokta J, Minhas SS. Duodenal diverticulum - Review of literature. *Indian J Surg* 2004;66:140-5.
16. Jang LC, Kim SW, Park YH, Kim JP. Symptomatic duodenal diverticulum. *World J Surg* 1995;19(5):729-33.
17. Song S. Management of Perforated Duodenal Diverticulum: Report of Two Cases. *Korean J Gastroenterol* 2015;66(3):159-63.
18. Rossetti A, Christian BN, Pascal B, Stephane D, Philippe M. Perforated duodenal diverticulum, a rare complication of a common pathology: A seven-patient case series. *World J Gastrointest Surg* 2013;5(3):47-50.
19. Maingot R. Gastric and duodenal diverticula. In: Maingot R. *Abdominal operations* Appleton Century Crofts, New York. 1980.p.141-56.