

# Patent Foramen Ovale and Stroke: Coincident or Real Association?

Chumpol Anamnart, M.D., Niphon Pongvarin, M.D., FRCP, FRI(T).\*

Department of Medicine, Faculty of Medicine Siriraj Hospital, Mahidol University, Bangkok 10700, Thailand.

## ABSTRACT

Stroke is a common cause of morbidity and mortality. Approximately 40% of strokes are cryptogenic, because patent foramen ovale (PFO) is commonly found in the normal population. They are conflicting data from studies examining the association between PFO and stroke. Various factors need to be considered such as atrial anatomic variations (PFO size, atrial septal aneurysm, eustachian valve anatomy), the presence of venous thrombosis, and the presence of hypercoagulable state. The presence of any of these findings increases the chance of PFO contributing to a stroke. Limited information suggests no advantage of warfarin over aspirin in preventing recurrent strokes. Both surgical and transcatheter devices have been shown to decrease the rate of subsequent embolic events substantially. Surgical and percutaneous PFO closures have not been directly compared. However, the percutaneous approach appears to be less invasive and so successful that it seems to be a reasonable consideration for first choice treatment of PFO.

**Keywords:** Stroke, patent foramen ovale

**Siriraj Med J 2011;63:106-110**

**E-journal:** <http://www.sirirajmedj.com>

The definite etiology of ischemic stroke in young patients is often not found despite extensive systematic investigations. Such strokes are classified as cryptogenic.<sup>1</sup> In patients with cryptogenic stroke, patent foramen ovale (PFO) can be detected in more than 50%, whereas its prevalence in the general population is at least 25%.<sup>2</sup> Therefore, PFO is likely associated with cryptogenic stroke. The presumed mechanism is paradoxical embolism of venous thrombotic material across the right-to-left shunt. Earlier studies have suggested that PFO is an incidental finding in patients with cryptogenic stroke and does not represent a risk factor for cerebral ischemia. On the other hand, later studies and a meta-analysis support PFO as a risk factor for stroke, and also found a strong association between the morphological characteristics of the PFO and the risk of embolic cerebrovascular events. The coincidence of an atrial septal aneurysm seem to increase the risk of brain infarction further.

Even assuming the PFO is related to the stroke, optimal treatment is uncertain. Antiplatelet therapy, anticoagulation, and closure of the PFO are all options, although, little definitive data exist to guide the choice of treatment.

## PFO embryology and anatomy

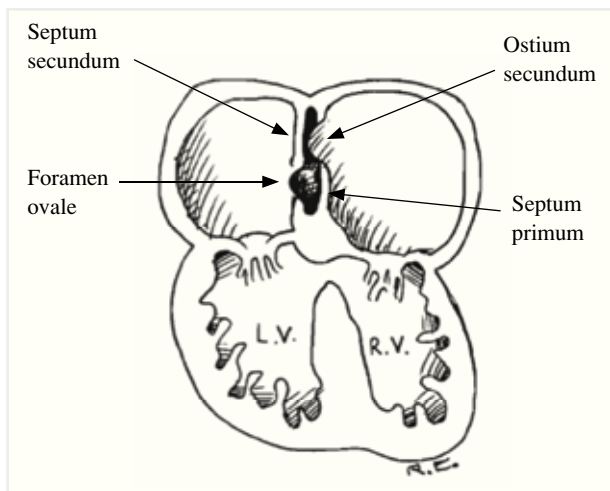
The foramen ovale is necessary for blood flow across the fetal atrial septum.<sup>3</sup> During fetal development, the interatrial septum arises from two septa, the septum primum, and septum secundum.<sup>4</sup> The septum primum form first, grows downwards from the roof of the primitive atrium and extends caudally. The septum secundum forms to the right of the septum primum, growing upwards from the interventricular septum. During fetal life, both septa have openings, the foramen secundum in the septum primum and the foramen ovale in the septum secundum (Fig 1).<sup>5</sup> Both of these ostia are part of the fetal interatrial pathway that allows maternally oxygenated blood to bypass the fetal pulmonary circulation in utero. At birth this interatrial passage is closed as pulmonary pressure falls and the left atrial pressure exceeds that on the right. Within a few months of life, the foramen ovale seals shut in most individuals. This fusion is completed by age two in about 75% of individuals, but patency occurs in the other 25%. It is a residual, oblique, slit-shaped defect resembling a tunnel. The reasons the PFO fails to close are unknown, but it is likely related to multifactorial inheritance.<sup>6</sup> The autopsy-derived prevalence of probe-patent PFO is about 27%, with decreasing prevalence at each decade of life.<sup>7</sup> The PFO slit width in the adult ranges from 1-19 mm (mean 4.9 mm) derived from postmortem formalin-fixed

Correspondence to: Niphon Pongvarin

E-mail: [niphonp.thailand@gmail.com](mailto:niphonp.thailand@gmail.com)

Received: 30 September 2010

Revised: 28 January 2011



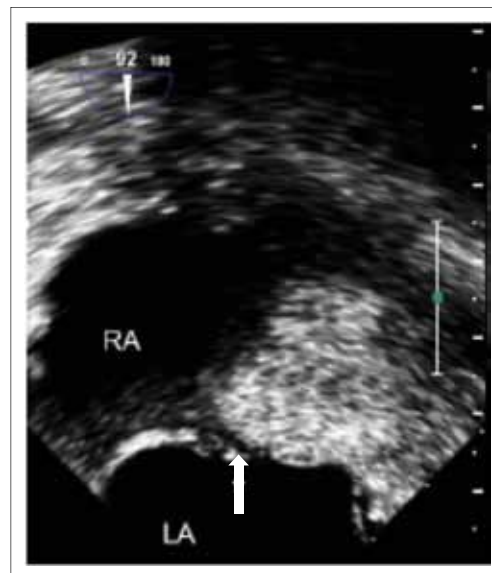**Fig 1.** Embryological cardiac development at 3 months of gestation. Note: LV = left ventricle, RV = right ventricle

specimens. The PFO size increases with each decade of life. The mean diameter in the first decade is 3.4 mm and in the tenth decade is 5.8 mm, perhaps reflecting size-based selection over time where a larger PFO remains patent and smaller defects close. Greater PFO size increases the risk of paradoxical embolism.

The PFO is associated with several anatomic abnormalities. A common association is atrial septal aneurysm (ASA), where part or all of the atrium septum shows aneurysmal dilatation, protruding into either atria. The ASA is defined as phasic septal excursion of at least 10 mm during the cardiac cycle. The term “aneurysm”, however, is a misnomer, as the defect does not consist of a weakened blood vessel wall, but rather a hypermobile septum primum which protrudes alternately into the right and left atria during each cardiac cycle. When the excursion of the septum exceeds a certain distance (criteria vary, but the most common definition is more than 10 mm), an ASA is considered present. Atrial septal aneurysm was found in 7.9% of stroke patients by biplane transesophageal echocardiography (TEE) and 15% by single-plane TEE.<sup>8,9</sup> A study in adults showed that 33% of patients with ASA also had PFO, although 32% had isolated ASA.<sup>10</sup> Thus, ASA is more frequent in subjects with PFO, and ASA predicts PFO. The odds of PFO are 4.6 times greater with ASA than without ASA.

### PFO detection

Patent foramen ovale may be detected by transthoracic echocardiography (TTE), transesophageal echocardiography (TEE) (Fig 2), 5 transcranial Doppler (TCD), and sometimes by transmitral Doppler. These techniques have been compared in studies of proven embolic stroke. One study revealed that TEE detected PFO with the most sensitivity, showing the prevalence of 39%. In this study, TTE found PFO in 18% and TCD found 27%.<sup>11</sup> All PFO detected by TTE and TCD were also detected by TEE. Six PFO that could not be detected by TCD were < 2 mm in size by TEE, implying that TCD may miss small defects. Patent foramen ovale detection can be augmented by cough or releasing a sustained Valsalva maneuver. It opens the foramen when the right atrium fills with blood from the abdomen, while the left atrium is volume depleted prior to blood passing through the pulmonary circulation. This maneuver is now considered necessary to find right-to-left



**Fig 2.** Transesophageal echocardiogram of a patent foramen ovale (arrow). LA = left atrium, RV = right atrium

shunts when performing echocardiography of any type, with or without contrast injection.

Transcranial Doppler is comparable to contrast TEE for detecting PFO-related right-to-left shunts, and it is easy to perform at the bedside. One study compared the sensitivity of transcranial color-coded sonography with TEE for detecting right-to-left cardiac shunts. It showed that TCD was as sensitive as contrast TEE.<sup>12</sup> Transcranial Doppler has recently been augmented by power M-mode, a new technology allowing power display with Doppler velocity and frequency signals over selectable depth ranges along the transducer beam.

### Association between PFO and stroke

The etiology of a stroke is either hemorrhagic or ischemic. However, approximately 40% of ischemic strokes have no clearly definable cause and are termed cryptogenic stroke. Furthermore, data from the Northern Manhattan Stroke Study reported recurrence rates for all stroke subtypes of 9.4% per year and 10% for cryptogenic stroke.<sup>13</sup> Lechat et al were the first to report an unusually high prevalence of PFO in patients who had cryptogenic stroke.<sup>14</sup> They studied the prevalence of PFO, detected by contrast surface echocardiography, in a population of 60 adults younger than 55 years with ischemic stroke. A PFO was found in 40% of the study population compared with 10% of a control group without stroke ( $P < 0.001$ ). In addition, a PFO was present in 54% of patients with cryptogenic stroke ( $P < 0.10$ ). A meta-analysis of case control studies found that PFO increased the relative risk of stroke by a factor of 1.83 (95% confidence interval, 1.25-2.66). In individuals younger than 55 years old, the relative risk was 3.10 (95%CI, 2.39-4.21). A similar association was not found in older patients ( $\geq 55$  years).<sup>15</sup> Not all studies have confirmed this association. Two population-based studies addressed the issue of PFO-related first-ever stroke risk prospectively,<sup>16,17</sup> one in the Olmsted county, MN, and the other in the northern Manhattan population of New York. Both studies failed to establish the role of PFO as an independent risk factor for stroke in the general population. There was only a non-significant trend towards a higher stroke incidence in persons with PFO in both studies.

Several conditions must be met for a paradoxical embolization through a PFO to occur. First, there must be a source of venous thrombus.<sup>18</sup> The thrombus must then embolize and while passing through the heart, it must be subjected to increased right heart pressure allowing the thrombus to pass through the PFO to systemic circulation. Once in the systemic circulation it must be directed to the brain and then lodge in a sufficiently large artery to cause a clinical stroke. Each element of this clinical scenario may be a relatively unlikely event, making the final result, a clinical stroke, even less likely. The source of thrombus in patients with PFO and suspected paradoxical embolus is uncertain. Deep venous thrombosis (DVT) is found in only a minority of patients. In one study of patients with PFO and suspected paradoxical emboli, only 14% had a clinically evident DVT, but contrast venography showed venous thrombus in 57%.<sup>19</sup> Such thrombi may form in superficial veins spontaneously after prolonged immobility or after minor trauma. However, it has been shown that when the DVT develops, it serves as the nidus for a barrage of thrombo-emboli directed at the right atria. Overt symptoms or physical examination findings of DVT are often absent in patients with stroke associated with PFO. Pelvic veins are likely an important source of paradoxical emboli in patients with PFO. Autopsies of patients with cryptogenic pulmonary emboli or paradoxical emboli have documented isolated pelvic thrombi in 16-22% of cases respectively.<sup>20</sup> Pelvic vein thrombi are difficult to detect even by lower extremity contrast venography. Magnetic resonance venography is an emerging diagnostic alternative. In the Paradoxical Emboli from Large Veins in Ischemic Stroke (PELVIS) study,<sup>21</sup> MR venography detected pelvic DVT more frequently in patients with cryptogenic stroke than in those with stroke of determined origin (20 vs 4%; P=0.025)

### Risk for recurrent stroke

After the first cryptogenic stroke associated with a PFO, the risk of recurrent stroke is increased, but only quite modestly, in the order of 2% per year with anti-thrombotic medication alone.<sup>22</sup> Given this intermediate rate of recurrence, extensive investigation has taken place to identify additional features that would permit stratifying patients with cryptogenic stroke and PFO into subgroups at higher and at lower risk. The strongest potentiator of stroke risk related to PFO is the coexistence of an ASA. PFO was detected by TEE using contrast or Doppler color in 70% of ASA patients,<sup>23</sup> suggesting that PFO detection is possible by intracardiac echocardiography. In the meta-analysis ASA alone was associated with both stroke and cryptogenic stroke, but the combination of PFO and ASA greatly magnified the risk. In patients with cryptogenic stroke, the odds ratio was 3.16 (95% CI, 2.30-4.35) for PFO, 3.65 (95% CI, 1.34-9.97) for ASA, and 23.26 (95% CI, 5.24-103.2) for PFO/ASA.<sup>15</sup> An additional potential risk stratification variable is the anatomic size of the PFO. A larger PFO may be associated with greater volumes of paradoxical blood flow and allow passage into the arterial circulation of larger clots more likely to cause symptomatic stroke. Several case-control studies have found that larger PFO size is associated with cryptogenic stroke, but others have failed to confirm this finding. Similarly, several studies have found that stroke patients with PFO have a greater frequency of right-to-left shunting at rest compared with controls. The degree of right-to-left shunting is related not only to PFO size, but also to the presence of a prominent

Eustachian valve. Before birth, the Eustachian valve directs oxygenated blood from the inferior vena cava towards and across the PFO into the systemic circulation. In patients with a PFO, a persisting Eustachian valve is frequently encountered directing the blood from the inferior vena cava to the interatrial septum, and a persisting Eustachian valve may prevent spontaneous closure of PFO after birth and may, therefore, doubly predispose a patient to a paradoxical embolism.<sup>24</sup>

Coagulation abnormalities may promote paradoxical emboli in patients with PFO and cryptogenic stroke. Chaturvedi studied 17 patients who presented with cryptogenic stroke and a PFO. A complete hematologic evaluation was performed in 16 patients. Hemostatic abnormalities were presented in 5 (31%) of 16 patients, including abnormal activated protein C resistance. All patients with an identified hypercoagulable disorder underwent anticoagulation with no reported stroke recurrence after 20 months. Although this study is small, it suggests hypercoagulability might be more prevalent in patients with PFO and stroke.<sup>25</sup>

In conclusion, the clinical features suggesting a true causative relationship between a PFO and a cryptogenic stroke are shown in the following listing<sup>3</sup>:

1. History
  - 1.1 Sedentary period prior onset
  - 1.2 Valsalva at onset
  - 1.3 Absence of common stroke risk factors
2. Anatomy
  - 2.1 Atrial septal aneurysm
  - 2.2 Large PFO size
  - 2.3 Prominent Eustachian valve
3. Physiology
  - 3.1 Shunt at rest
  - 3.2 Spontaneous Doppler flow
  - 3.3 Many bubbles cross on contrast injection
4. Neuroimaging and laboratory testing
  - 4.1 Embolic stroke topography
  - 4.2 Hypercoagulable state

### Treatment

There are no compelling clinical trial data available to guide treatment for patients with cryptogenic stroke and a PFO and no studies have investigated the treatment of choice for primary prevention in asymptomatic individuals. Treatment options for PFO in patients with stroke include antiplatelet therapy, anticoagulants, endovascular closure, or surgical closure. Treatment with antiplatelet therapy and anticoagulant therapy are intended to reduce venous thrombus formation and embolization, whereas closure of the interatrial septal defect with surgery or with an endovascular device is intended to eliminate access by embolic particles to the artery. Endovascular treatment has largely replaced surgical closure due to the higher morbidity rate associated with the surgical approach.

In a retrospective study by Mas et al in 132 patients younger than 60 years with PFO and cryptogenic stroke, patients were treated with either aspirin (250-500 mg/d) or oral anticoagulation (target international normalization ratio [INR], 2.0-3.0). The average annual rate of recurrence was 1.2% for stroke and 3.4% for the combined end point of TIA and stroke.<sup>26</sup> Similar recurrence rates with medical treatment were reported from the Lausanne stroke registry. Ninety-two patients with PFO and cryptogenic stroke were treated with aspirin (250-500 mg/d), whereas 37 patients were treated with oral anticoagulant (target INR, 2.0-3.0). In 8 patients, the regimen was switched to

aspirin after 3 months of oral anticoagulant. The mean annual rate of recurrence was 1.9% for stroke and 3.8% for the combined end point of TIA and stroke during a follow-up period of 3 years, with no statistically significant difference between the two antithrombotic drug regimens.<sup>27</sup> The largest cohort study, the French PFO/ASA study, was an unblinded trial of 881 patients with stroke. Of these 37% of the patients had a PFO and 1.7% had a PFO combined with an atrial septal aneurysm. All received acetylsalicylic acid (300 mg/d). After 4 years of follow up, the risk of recurrent stroke was 2.3% in patients with PFO compared with 4.2% in patients without cardiac abnormalities.<sup>28</sup> The Warfarin-Aspirin Recurrent Stroke Study (WARSS) was a prospective trial that randomized 2206 patients with ischemic stroke to either aspirin (325 mg/d) or warfarin (target INR, 1.4-2.8). This 2-year trial found no difference between the 2 therapies regarding end points of recurrent stroke or death.<sup>29</sup> PICSS (Patent Foramen Ovale in Cryptogenic Stroke Study)<sup>30</sup> was a sub-study of the randomized-controlled Warfarin-Aspirin Recurrent Stroke Study (WARSS). It compared acetylsalicylic acid and anticoagulation for the secondary prevention of stroke. A PFO was found in 39% of 265 patients with cryptogenic stroke and in 30% of 365 patients with a stroke of determined etiology. In addition, when the groups with and without a PFO were analyzed in relation to the efficacy of warfarin (mean INR, 2.04) or acetylsalicylic acid (325 mg/d), no significant differences were found. In PICSS acetylsalicylic acid and warfarin were equal in preventing recurrent stroke or death.

Surgical closure of the PFO provides an alternative to lifelong antiplatelet or anticoagulation therapy. Surgical treatment can potentially permanently close the interatrial defect, eliminating the need for medical therapy. The major disadvantage of surgical closure is that it requires both a thoracotomy and cardiopulmonary bypass. Although perioperative mortality is minimal, morbidity includes atrial fibrillation, pericardial drainage for effusion, repeat surgery for exploration for bleeding source, wound infection, and postpericardiotomy syndrome. Recurrence of cerebral ischemia may have been due to incomplete closure of the PFO. Dearani et al retrospectively analyzed 91 patients to determine the outcome of surgical closure of PFO in patients with prior ischemic neurologic events to define the rate of stroke or TIA recurrence and to identify risk factors for these recurrences.<sup>31</sup> All their patients underwent successful surgical closure (suture in 82, patch closure in 9) with a 2-year follow-up. They found that the overall freedom from TIAs and strokes was 92.5% at 1 year and 83.4% at 2 years. Of the many patient demographic and preoperative variables analyzed, only multiple neurologic events before PFO closure were a significant risk factor for TIA or stroke recurrence by univariate analysis ( $P = .05$ ).

Because of the morbidity of open heart surgery, catheter-based approaches to PFO are an attractive alternative. Percutaneous endovascular PFO closure theoretically offers the benefits of eradication of the right-to-left shunt without the risks associated with surgical intervention, nevertheless, complications can also occur. They include atrial wall perforation with pericardial effusion, device dislodgement or embolisation, device fractures, early and late free wall erosions, aortic regurgitation, thrombosis on the device and thrombus embolization, septal fibrosis, arrhythmias, venous access complications, air embolism through the transseptal sheath, and death.<sup>32</sup> However, growing experience with more careful manipulation of

catheters, wires, and devices, has increased the success rate of implantation close to 100% and decreased the rate of significant complications to 1%. Martin et al reported the immediate and long-term outcome in 110 consecutive patients who underwent percutaneous endovascular PFO closure because of paradoxical embolism.<sup>33</sup> Procedural success with successful device deployment without shunt was achieved in all the patients. One device migrated early, requiring surgical intervention (0.9%), and 1 device placement led to cardiac tamponade, requiring pericardiocentesis. Long-term follow-up of 2.3 years revealed 2 patients who experienced recurrent neurologic events (1 fatal stroke and 1 TIA) and 4 patients (3.6%) who required reintervention for device misalignment of the significant shunt. A Kaplan-Meier analysis showed a freedom from recurrent embolic events and reintervention of 96% and 90% at 1 and 5 years, respectively.

Comparisons between antithrombotic treatment and percutaneous endovascular PFO closure in patients with cryptogenic stroke are scarce and currently at the level of case-control studies. Windecker et al compared the risk of recurrence in 308 patients with cryptogenic stroke and PFO, who were treated either medically (158 patients) or underwent percutaneous PFO closure.<sup>34</sup> Patients undergoing percutaneous PFO closure had a larger right-to-left shunt ( $P=0.001$ ; 95% confidence interval [CI] 1.38 to 3.07) and were more likely to have suffered more than one cerebrovascular event ( $p = 0.03$ ; 95% CI 1.04 to 2.71). At four years of follow-up, percutaneous PFO closure resulted in a non-significant trend toward risk reduction of death, stroke, or transient ischemic attack (TIA) combined (8.5% vs. 24.3%;  $p = 0.05$ ; 95% CI 0.23 to 1.01), and of recurrent stroke or TIA (7.8% vs. 22.2%;  $p = 0.08$ ; 95% CI 0.23 to 1.11) compared with medical treatment. They concluded that percutaneous PFO closure appears at least as effective as medical treatment for the prevention of recurrent cerebrovascular events in cryptogenic stroke patients with PFO. It might be more effective than medical treatment in patients with complete closure and more than one cerebrovascular event.

## CONCLUSION

Stroke is a common cause of morbidity and mortality. Approximate 40% of strokes are cryptogenic. Because PFO is commonly found in the normal population, we need to identify a subset of cryptogenic stroke patients who are likely to have experienced paradoxical embolization. Various factors need be considered such as atrial anatomic variation (PFO size, ASA, Eustachian valve anatomy), hemodynamic parameters, presence of venous thrombosis, and presence of hypercoagulable state. The presence of any of these findings increases the chance of PFO contributing to stroke. Limited information suggests no advantage of warfarin over aspirin in preventing recurrent stroke. Both surgical and transcatheter devices have been shown to decrease the rate of subsequent embolic event substantially. Surgical and percutaneous PFO closure have not been directly compared. However, the percutaneous approach appears less invasive and so successful that it seems to be reasonable for first choice treatment.

## REFERENCES

1. Pongvarin N. Stroke in the young. Stroke. 2nd edition. Bangkok: Roenkaew Kanpim; 2001. p. 337-58.



2. Meissner I, Whisnant JP, Khandheria BK, Spittell PC, O'Fallon WM, Pascoe RD, et al. Prevalence of potential risk factors for stroke assessed by transesophageal echocardiography and carotid ultrasonography: the SPARC study. *Stroke Prevention: Assessment of risk in community.* Mayo Clin Proc. 1999 Sep;74(9):862-9.
3. Thaler DE, Saver JL. Cryptogenic stroke and patent foramen ovale. *Curr Opin Cardiol.* 2008 Nov;23(6):537-44.
4. Hara H, Virmani R, Ladich E, Mackey-Bojack S, Titus J, Reisman M, et al. Patent foramen ovale: current pathology, pathophysiology, and clinical status. *J Am Coll Cardiol.* 2005 Nov 1;46(9):1768-76.
5. Horton SC, Bunch TJ. Patent foramen ovale and stroke. *Mayo Clin Proc.* 2004 Jan;79(1):79-88.
6. Clark E. Pathogenetic mechanism of congenital cardiovascular malformations revisited. *Semin Perinatol.* 1996 Dec;20(6):465-72.
7. Hagen PT, Scholz DG, Edwards WD. Incidence and size of patent foramen ovale during the first 10 decades of life: an autopsy study of 965 normal heart. *Mayo Clin Proc.* 1984 Jan;59(1):17-20.
8. Agmon Y, Khandheria BK, Meissner I, Gentile F, Whisnant JP, Sicks JD, et al. Frequency of atrial septal aneurysms in patients with cerebral ischemic event. *Circulation.* 1999 Apr 20;99(15):1942-4.
9. Pearson AC, Nagelhout D, Castello R, Gomez CR, Labovitz AJ. Atrial septal aneurysm and stroke: a transesophageal echocardiographic study. *J Am Coll Cardiol.* 1991 Nov 1;18(5):1223-9.
10. Mücke A, Daniel WG, Angermann C, Spes C, Khandheria BK, Kronzon I, et al. Atrial septal aneurysm in adult patients. A multicenter study using transthoracic and transesophageal echocardiography. *Circulation.* 1995 Jun 1;91(11):2785-92.
11. Di Tullio M, Sacco RL, Venketasubramanian N, Sherman D, Mohr JP, Homma S. Comparison of diagnostic techniques for the detection of a patent foramen ovale in stroke patients. *Stroke.* 1993 Jul;24(7):1020-4.
12. Blersch WK, Draganski BM, Holmer SR, Koch HJ, Schlachetzki F, Bogdahn U, et al. Transcranial duplex sonography in the detection of patent foramen ovale. *Radiology.* 2002 Dec;225(3):693-9.
13. Sacco RL, Shi T, Zamanillo MC, Kargman DE. Predictors of mortality and recurrence after hospitalized cerebral infarction in an urban community: the Northern Manhattan Stroke Study. *Neurology.* 1994 Apr;44(4):626-34.
14. Lechat P, Mas JL, Lascault G, Loron P, Theard M, Klimczac M, et al. Prevalence of patent foramen ovale in patients with stroke. *N Engl J Med.* 1988 May 5;318(18):1148-52.
15. Overell JR, Bone I, Lees KR. Interatrial septal abnormalities and stroke: a meta-analysis of case-control studies. *Neurology.* 2000 Oct 24;55(8):1172-9.
16. Meissner I, Khandheria BK, Heit JA, Petty GW, Sheps SG, Schwartz GL, et al. Patent foramen ovale: innocent or guilty? Evidence from the population-based study. *Am Coll Cardiol.* 2006 Jan 17;47(2):440-5.
17. Di Tullio MR, Sacco RL, Sciacca RR, Jin Z, Homma S. Patent foramen ovale and the risk of ischemic stroke in a multiethnic population. *J Am Coll Cardiol.* 2007 Feb 20;49(7):797-802.
18. Lawrence R. PFO and stroke. What are the data?. *Cardiol in Rev.* 2008; 16:53-7.
19. Stöllberger C, Slany J, Schuster I, Leitner H, Winkler WB, Karnik R. The prevalence of deep venous thrombosis in patients with suspected paradoxical embolism. *Ann Intern Med.* 1993 Sep 15;119(6):461-5.
20. Kim D, Saver JL. Patent foramen ovale and stroke: What we do and don't know. *Rev Neurol Dis.* 2005 Winter;2(1):1-7.
21. Cramer SC, Rordorf G, Maki JH, Kramer LA, Grotta JC, Burgin WS, et al. Increase pelvic vein thrombi in cryptogenic stroke: result of the Paradoxical Emboli from Large Veins in Ischemic Stroke (PELVIS) study. *Stroke.* 2004 Jan;35(1):46-50.
22. Homma S, Sacco RL. Patent foramen ovale and stroke. *Circulation.* 2005 Aug 16;112(7):1063-72.
23. Marazano M, Roudaut R, Cohen A, Tribouilloy C, Malergues MC, Halphen C, et al. Atrial septal aneurysm. Morphological characteristics in a large population: pathological associations. A French multicenter studies on 259 patients investigated by transesophageal echocardiography. *Int J Cardiol.* 1995 Nov 10;52(1):59-65.
24. Schuchlenz HW, Saurer G, Weihs W, Rehak P. Persisting eustachian valve in adults: relation to patent foramen ovale and cerebrovascular events. *J Am Soc Echocardiogr.* 2004 Mar;17(3):231-3.
25. Chaturvedi S. Coagulation abnormalities in adults with cryptogenic stroke and patent foramen ovale. *J Neurol Sci.* 1998 Oct 8;160(2):158-60.
26. Mas JL, Zuber M. Recurrent cerebrovascular events in patients with patent foramen ovale, atrial septal aneurysm, or both and cryptogenic stroke or transient ischemic attack. French Study Group on Patent Foramen Ovale and Atrial Septal Aneurysm. *Am Heart J.* 1995 Nov;130(5):1083-8.
27. Bogousslavsky J, Garazi S, Jeanrenaud X, Aebischer N, Van Melle G. Lausanne Stroke with Paradoxical Embolism Study Group. Stroke recurrence in patients with patent foramen ovale: the Lausanne Study. *Neurology.* 1996 May;46(5):1301-5.
28. Mas JL, Arquizan C, Lamy C, Zuber M, Cabanes L, Derumeaux G, et al. Recurrent cerebrovascular events associated with patent foramen ovale, atrial septal aneurysm or both. *N Engl J Med.* 2001 Dec 13;345(24):1740-6.
29. Mohr JP, Thompson JL, Lazar RM, Levin B, Sacco RL, Furie KL, et al. A comparison of warfarin and aspirin for the prevention of recurrent ischemic stroke. *N Engl J Med.* 2001 Nov 15;345(20):1444-51.
30. Homma S, Sacco RL, Di Tullio MR, Sciacca RR, Mohr JP. PFO in Cryptogenic Stroke Study (PICSS) Investigators. Effect of medical treatment in stroke patients with patent foramen ovale: Patent foramen ovale in cryptogenic stroke study. *Circulation.* 2002 Jun 4;105(22):2625-31.
31. Dearani JA, Ugurlu BS, Danielson GK, Daly RC, McGregor CG, Mullany CJ, et al. Surgical patent foramen ovale closure for prevention of paradoxical embolism-related cerebrovascular ischemic events. *Circulation.* 1999 Nov 9;100(19 Suppl):II171-5.
32. Wöhrle J. Closure of patent foramen ovale after cryptogenic stroke. *Lancet.* 2006 Jul 29;368(9533):350-2.
33. Martín F, Sánchez PL, Doherty E, Colon-Hernandez PJ, Delgado G, Inglessis I, et al. Percutaneous transcatheter closure of patent foramen ovale in patients with paradoxical embolism. *Circulation.* 2002 Aug 27;106(9):1121-6.
34. Windecker S, Wahl A, Nedeltchev K, Arnold M, Schwerzmann M, Seiler C, et al. Comparison of medical treatment with percutaneous closure of patent foramen ovale in patients with cryptogenic stroke. *J Am Coll Cardiol.* 2004 Aug 18;44(4):750-8.