

Prurigo Pigmentosa-like Skin Lesion in Adult-onset Still's Disease: A Case Report and Literature Review

Voraphol Vejjabhinanta, M.D.*, Penvadee Pattanaprichakul, M.D.**

*Institute of Dermatology, Ministry of Public Health, Bangkok 10400, **Department of Dermatology, Faculty of Medicine Siriraj Hospital, Mahidol University, Bangkok 10700, Thailand.

ABSTRACT

A report of a 26-year-old woman with adult-onset Still's disease (AOSD) presenting with prolonged fever, arthralgia and reticulate papular eruptions on her abdomen and back without typical rash of AOSD. The skin lesion and fever subsided soon after the initial treatment by oral prednisolone of 40 mg/day. Prurigo pigmentosa-like skin rash is an atypical cutaneous eruption which has previously been reported in association with AOSD. We report an unusual case of AOSD presenting with atypical skin rash mimicking prurigo pigmentosa.

Keywords: Prurigo pigmentosa, adult-onset Still's disease

Siriraj Med J 2015;67:145-148

E-journal: <http://www.sirirajmedj.com>

INTRODUCTION

Adult-onset Still's disease (AOSD) is a systemic inflammatory disease with manifestation of high-grade intermittent fever, leukocytosis, arthralgia, and skin rash.¹ Typical skin rash is an evanescent salmon-pink maculopapular rash involving extremities and trunk, which is one of the major diagnostic criterion.^{2,3} The presence of the typical skin lesion is important to establish the diagnosis. However many cases of AOSD have been reported with various atypical skin rashes which are not familiar for the physicians causing delayed diagnosis. We report an unusual case of AOSD presenting with atypical skin rash mimicking prurigo pigmentosa.

CASE REPORT

A 26-year-old female presented with a 4-month history of high intermittent fever, arthralgia, weight loss, and one-month history of pruritic skin eruption on her trunk. She had previously been healthy without history of recent sore throat, mucosal ulcer, or photosensitivity. She had not taken any medications prior to the onset of the cutaneous lesion. She denied any history of drug allergy and food allergy. Her past history and family history were unremarkable. The patient was admitted in the in-patient department to investigate the cause of prolonged fever. On physical examination, there were high-grade fever of 39.4°C with mild pallor, multiple cervical lymph nodes enlargement and numerous pruritic brownish papules which became confluent to reticulate plaques on the abdomen, back and buttock (Fig 1). Arthralgia/arthritis and hepatosplenomegaly were not detected at the time of the examination. Labo-

Correspondence to: Penvadee Pattanaprichakul

E-mail: penvadee.pat@mahidol.ac.th

Received 22 January 2015

Revised 27 February 2015

Accepted 13 March 2015

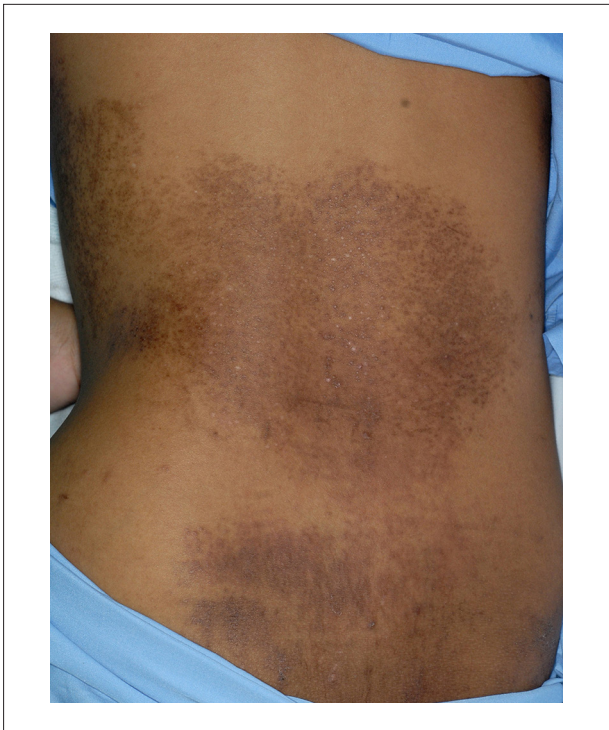

Fig 1. Discrete brownish papules which become confluent to form a reticulate pattern on the back.

ratory examinations showed leukocytosis with anemia (WBC 14,510/mm³, N 75%, L 13%, M 6%, E 5%, platelets 447,000/mm³ and hematocrit 26.8%), high serum ferritin level of 3,852 ng/ml and high lactate dehydrogenase (LDH) level of 2,570 U/L. The liver function showed mild elevation of liver enzymes (AST 62 U/L and ALT 115 U/L). Serum creatinine, urinalysis, and chest x-ray were normal. Antinuclear antibody (ANA) and rheumatoid factor (RF) were negative. Lesional biopsy from the abdomen revealed mild epidermal acanthosis with focal spongiosis and exocytosis of neutrophils. There were scattered dyskeratotic cells in all layers of the epidermis and focal vacuolar degenerations of basal cells were noted (Fig 2). There were superficial perivascular and interstitial infiltrates of lymphocytes, neutrophils, eosinophils and nuclear dusts without evidence of endothelial damage (Fig 3). Direct immunofluorescent study from the tissue biopsy revealed negative finding. After intensive investigation, there was no evidence of infections or malignancies, and the patient was finally diagnosed with ASOD. The patient was initially treated with oral prednisolone 40 mg/day. The skin eruption gradually disappeared soon after the initiation of

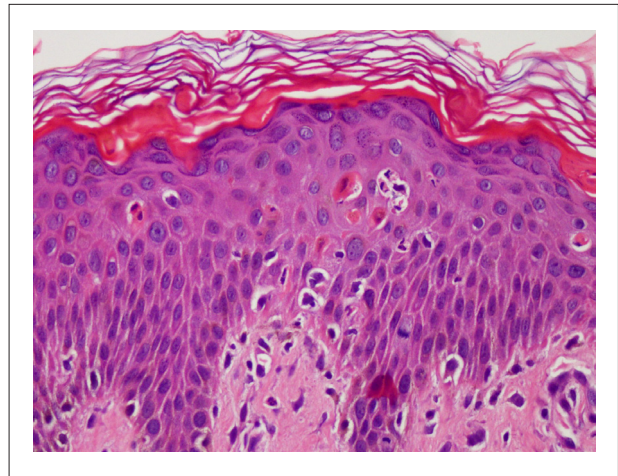


Fig 2. Epidermis shows mild acanthosis, exocytosis of neutrophils, scattered necrotic keratinocytes and focal basal vacuolar degeneration. (H&E x400)

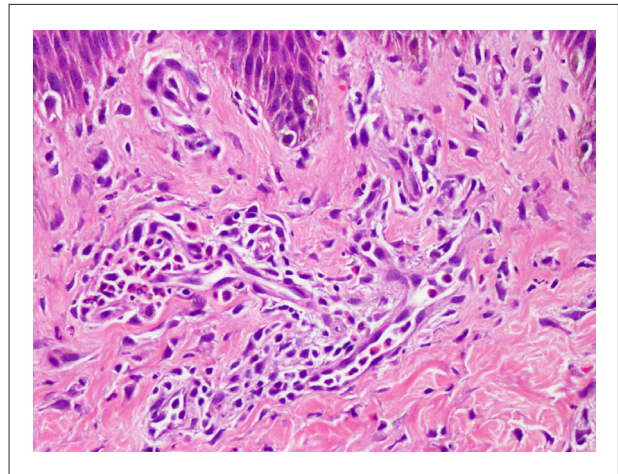


Fig 3. Perivascular and interstitial infiltrates of lymphocytes, neutrophils, eosinophils and nuclear dusts without vasculitis. (H&E x 400)

the treatment for AOSD. During a 1-year follow up, the patient had been receiving prednisolone 15 mg/day and azathioprine 50 mg/day orally for AOSD. Fever and the skin rash had disappeared without any recurrence. The overall condition had been improved with intermittent episodes of mild arthralgia.

DISCUSSION

Adult-onset Still's disease (AOSD) is a systemic inflammatory disease with manifestation of high-grade intermittent fever, leukocytosis, arthralgia, sore throat, lymphadenopathy, hepatosplenomegaly, serositis, and skin rash.¹ Typical skin rash is an evanescent salmon-pink

maculopapular rash involving extremities and trunk, which is one of the major diagnostic criterion.² The presence of the typical skin lesion is important to establish the diagnosis. However many cases of AOSD have been reported with various atypical skin rashes which are not familiar for the physicians causing delayed diagnosis. Etiology of AOSD is still unidentified, although various infectious organisms would act as triggers in genetically predisposed hosts.³ Along with the differential diagnosis of AOSD, malignant diseases need to be excluded including myeloproliferative disorders, solid tumors (kidney, colon, lung), and paraneoplasia.⁴ Diagnosis of AOSD requires the presence of definite major or minor criteria of Yamaguchi et al² or a combination of both, and absence of certain exclusions. Despite the fact that 90% of AOSD patients demonstrate some skin manifestations during the active episode, the typical salmon-pink evanescent rash is seen in up to 86% of patients with AOSD.⁵ Other skin manifestations including pruritus, urticarial plaques, facial rash, alopecia, erythema nodosum, Raynaud's phenomenon, and prurigo pigmentosa-like skin eruption have been reported, but are not common in AOSD. Prurigo pigmentosa (PP) is a rare inflammatory dermatologic disease of unknown cause, firstly, described by Nagashima et al⁶ in 1971. It is described by a rapid onset of pruritic erythematous papules, or papulovesicular eruptions typically involving the trunk and upper back, which coalesce to form a reticulate pattern. Lesion involutes in days leaving net-like pigmentation. Exacerbations and recurrences always occur periodically. Under microscopic examination, PP begins with superficial perivascular infiltrate of neutrophils, and shortly thereafter, neutrophils are scattered in dermal papillae and then sweep rapidly through an epidermis in which spongiosis, ballooning and necrotic keratinocytes are accompanied. Later on, eosinophils and lymphocytes come to predominate over neutrophils in dermal infiltrates with a patchy lichenoid pattern. Intraepidermal vesiculation follows spongiosis and sometimes subepidermal vesicle derives from vacuolar alteration of the basal keratinocytes. In aged lesions, the epidermis becomes acanthosis with parakeratosis, and a

small amount of melanophages begins to appear in the superficial dermis. Immunofluorescent studies are always non-specific.⁷ Several drugs such as minocycline, doxycycline, and dapsone are available for the treatment of PP. These drugs have both antibiotic and anti-inflammatory actions and they are also effective in the inhibition of migration of neutrophils, a mechanism which may explain their efficacy in PP. Many patients also experience spontaneous resolution of the eruption after a few weeks, but some patients reported recurrences within months or years later. In the literature review, articles by Tomaru K, et al⁸ in 2006 and Dowod T, et al⁹ in 2007 reported PP-like lesions in a patient with AOSD. In these cases, the patients developed PP-like lesions in addition to the typical evanescent rash of AOSD. In our case, after excluding all other certain conditions such as autoimmune diseases, infectious diseases and malignancies, AOSD was finally diagnosed. Almost all the criteria of AOSD were present except for typical evanescent rash and sore throat.

For the skin eruption in our patient, both clinical and histological findings are compatible with prurigo pigmentosa, which could be assumed to be an unusual cutaneous presentation of AOSD or the prurigo pigmentosa was coexistent with AOSD. There have been some literatures reporting the coexistence of skin lesions in AOSD, such as angioedema¹⁰, Sweet's syndrome¹¹, and erythema nodosum.¹² However, the skin lesions gradually disappeared after the initiation of the treatment for AOSD and have not been recurred since then. Therefore, we would consider the PP-like skin eruption in our patient was an atypical rash associated with AOSD.

In conclusion, it is important to recognize and be aware of various uncommon cutaneous eruptions of AOSD in order to establish early and correct diagnosis with prompt intervention to improve the patients' condition.

ACKNOWLEDGMENTS

The authors would like to thank the Department of Pathology, Faculty of Medicine Siriraj Hospital for the histopathological support of this present case.

REFERENCES

1. Dechant C, Krüger K. Adult-onset Still's disease Dtsch Med Wochenschr. 2011 Aug;136(33):1669-73.
2. Yamaguchi M, Ohta A, Tsunematsu T, Kasukawa R, Mizushima Y, Kashiwagi H, et al. Preliminary criteria for classification of adult Still's disease. J Rheumatol. 1992 Mar;19(3):424-30.
3. Bagnari V, Colina M, Ciancio G, Govoni M, Trotta F. Adult-onset Still's disease. Rheumatol Int. 2010 May;30(7):855-62.
4. Fautrel B. Adult-onset Still disease. Best Pract Res Clin Rheumatol. 2008 Oct;22(5):773-92.
5. Kaur S, Bamberry P, Dhar S. Persistent dermal plaque lesions in adult-onset Still's disease. Dermatology. 1994; 188(3):241-2.
6. Nagashima M, Ohshiro A, Shimizu N. A peculiar pruriginous dermatosis with gross reticular pigmentation. Jpn J Dermatol. 1971;81:38-39.
7. Boer A, Misago N, Wolter M, Kiryu H, Wang XD, Ackerman AB. Prurigo pigmentosa: a distinctive inflammatory disease of the skin. Am J Dermatopathol. 2003 Apr;25(2):117-29.
8. Tomaru K, Nagai Y, Ohyama N, Hasegawa M, Endo Y, Tamura A, et al. Adult-onset Still's disease with prurigo pigmentosa-like skin eruption. J Dermatol. 2006 Jan;33(1):55-58.
9. Dowod TAH, Khalel ESH, Mohammed MAA, Sharawy MAW, Alghabando SJ, Alsumait AY. Adult onset Still's disease and prurigo pigmentosa: An unusual association and review of literature. Pak J Med Sci. 2007 Oct-Dec;23(5):792-7.
10. Soy M. A case of adult-onset Still's disease presenting with angioedema. Clin Rheumatol. 2004 Feb;23(1):92.
11. Elinav H, Maly A, Ilan Y, Rubinow A, Naparstek Y, Amital H. The coexistence of Sweet's syndrome and Still's disease – is it merely a coincidence? J Am Acad Dermatol. 2004 May;50(5 Suppl):S90-92.
12. Torinuki W, Funyu T. Adult Still's disease manifesting as erythema nodosum. J Dermatol. 1996 Mar;23(3):216-7.