

Complete Remission After Definitive Radiotherapy in Carotid Body Tumor

Jiraporn Setakornnukul, M.D., Porntip Iampongpaiboon, M.Sc., Yoawalak Chansilpa, M.D.

Division of Radiation Oncology, Department of Radiology, Faculty of Medicine Siriraj Hospital, Mahidol University, Bangkok 10700, Thailand.

ABSTRACT

A 47-year-old woman with unresectable recurrent carotid body tumor was treated by 3-dimension conformal radiotherapy with total dose of 48 Gy in 16 fractions. Slow onset of tumor response, but eventually complete remission was noted with long-term tumor control at 5 years.

Keywords: Carotid body tumor, radiotherapy, complete remission

Siriraj Med J 2013;65:178-180

E-journal: <http://www.sirirajmedj.com>

INTRODUCTION

Abnormal neck masses have a variety of etiologies such as congenital, inflammatory, and neoplastic in origin. The most common cause of neoplasm is metastatic lymph node. Another rare benign tumor which should be considered in differential diagnosis is paragangliomas. In general, the principal treatment of this kind of tumor is surgery. However, radiotherapy is also effective treatment for inoperable cases. So far, only a few cases of carotid body tumor with complete response to radiotherapy have been reported.^{1,2} This case presentation is a rare case of unresectable recurrent carotid body tumor treated with 3-dimension conformal radiotherapy demonstrating slow tumor response, but eventually complete remission was noted with long-term tumor control at the Division of Radiation oncology, Department of Radiology, Faculty of Medicine Siriraj Hospital, Mahidol University, Bangkok, Thailand. From very good response to new protocol of treatment, radiotherapy can be considered as a good alternative treatment for inoperable carotid body tumors.

CASE REPORT

A 47-year-old woman presented with a right neck mass located around the bifurcation of her right carotid artery since 9 years ago. She was first treated by local

excision at a private hospital. Pathology revealed the histology of paraganglioma of carotid body tumor. She was in good health for 4 years before she developed her first recurrent neck mass at her previous surgical scar with 2 cms. in size. However, she had no signs and symptoms of catecholamine excess such as hypertension, headache, palpitation, and weight loss. She then underwent a second local excision. The pathology report was again paraganglioma with free surgical margin. Therefore, her final diagnosis was non-catecholamine secreting paraganglioma. Six months later, she developed a local recurrence. At that time, the mass was quite large with size 4x4x3 cm. and attached to her right common carotid artery and right internal carotid artery. Therefore, she was not suitable for surgery because of very high risk for surgical injury to these vessels. Finally, she was referred to our radiotherapy unit for definitive radiotherapy.

Investigations

The Computed Tomography (CT scan) was done for evaluation of the mass 4 months before her radiotherapy session (Fig 1). The findings showed a hyper-vascularized ill-defined irregular mass in the posterior styloid compartment of her right parapharyngeal space, 4.0x3.7x2.8 cm. in size. The tumor extended downward along the carotid sheath to the carotid bifurcation and caused postero-lateral displacement of the internal carotid artery. The carotid artery balloon test occlusion was performed and the patient could not clinically tolerate it.

Treatment

Definitive radiotherapy to the carotid body tumor was carried out between April 19th and May 15th 2007.

Correspondence to: Jiraporn Setakornnukul

E-mail: kookra015@hotmail.com

Received 14 February 2013

Revised 12 September 2013

Accepted 17 September 2013

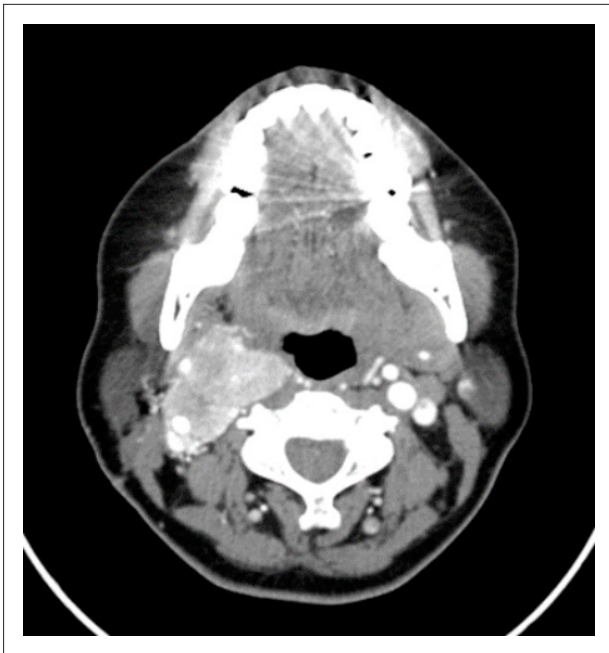


Fig 1. Computed Tomography before radiotherapy.

The radiation technique was 3D-conformal radiotherapy (3D-CRT) with 3 Gy/daily fraction to the total dose of 48 Gray (Gy.) in 16 Fractions which was equivalent to 54 Gray by conventional fractionation as calculated by LQ model (Linear-Quadratic model). The target volume was delineated according to ICRU 62 (International Commission on Radiation Units and Measurements). The GTV (gross target volume), which was defined as gross tumor, was shown on contrast CT scan. The CTV (clinical target volume) was the volume including GTV and 0.75 cm margin around. The PTV (planning target volume) was the volume including CTV and 0.75 cm margin around. The normal tissue constraint was limited within tolerance dose (Fig 2 and Table 1). During the second week of treatment, she developed mild to moderate degree of radiation induced esophagitis which was later relieved with medical treatment.

Outcomes and follow up

The patient was followed up at 2 months after radiation treatment. At that time, the tumor was 4.5x2.5 cm. in size and the acute radiation complication was totally resolved.

Six months later, the follow-up CT scan showed further decrease in tumor size down to 1.5x2.5x3.0 cm. Then, the patient was followed up clinically every three months for the first year. At 1 year follow-up, the tumor had almost totally regressed to just palpable in duration

TABLE 1. Normal tissue dose.

| Organ | Minimum dose (Gy) | Maximum dose (Gy) | Mean dose (Gy) |
|--------------|-------------------|-------------------|----------------|
| Thyroid | 3.37 | 38.40 | 14.03 |
| Larynx | 11.92 | 47.46 | 28.07 |
| Great vessel | 6.72 | 49.09 | 38.79 |
| Esophagus | 4.13 | 38.72 | 21.71 |
| Spinal cord | 2.36 | 39.28 | 29.58 |

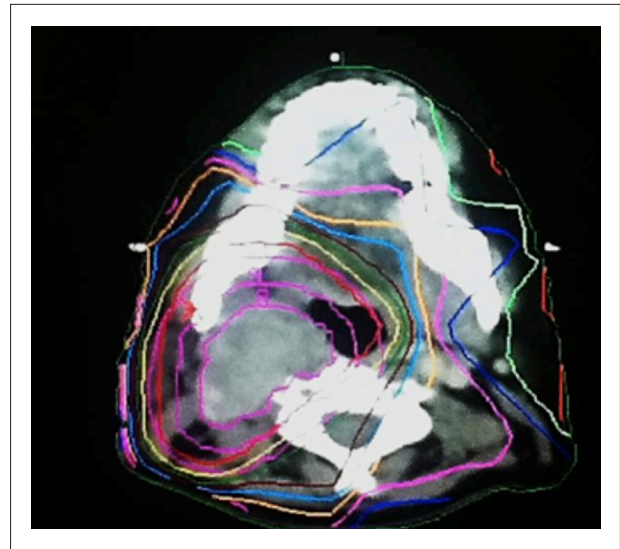


Fig 2. Isodose distributions in treatment planning.

which could not be differentiated from subcutaneous radiation fibrosis.

Unfortunately, she developed metastatic breast cancer, confirmed by core needle in July 2008. She also had lung and bone metastases concurrent with spinal cord compression which was treated by combined laminectomy and post-operative radiotherapy followed by palliative chemotherapy. Later on, the patient, underwent left mastectomy with axillary lymph node dissection and is now still alive with watchful follow-up.

For her carotid body tumor, by the fifth year her follow-up CT scan showed soft tissue density without enhancement about 0.5x1.0 cm. in the original area of tumor as shown on Fig 3. By such non-enhancing unremarkable findings, it may be confidentially interpreted as complete remission. In addition, she had no moderate or severe radiation toxicities from radiation treatment at all.

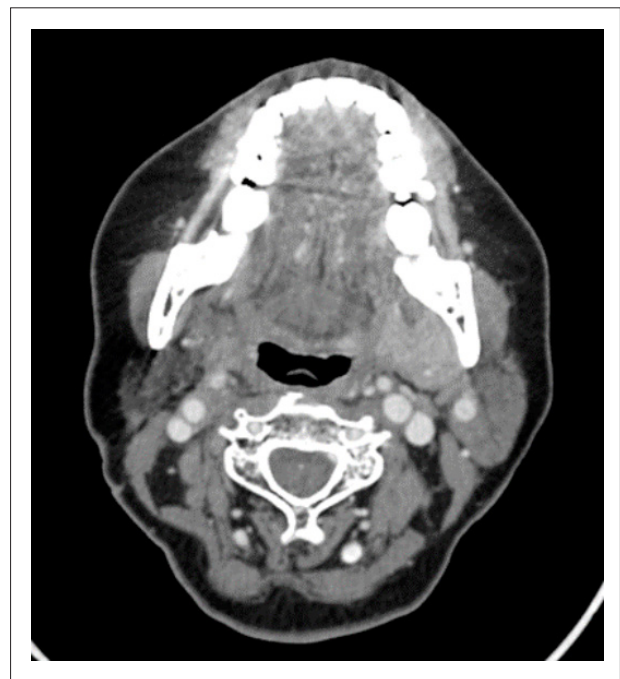

Fig 3. Computed Tomography after Radiotherapy 60 months.

DISCUSSION

Parangliomas are the tumor of paraganglia cells (glomus tumors) derived from neural crest. They are usually found at 4 locations.³ The first location is branchiogenic group which are jugulotympanic, carotid body, laryngeal, subclavian, and aorticopulmonary. The second location is intravagal (at the level of the jugular or no dose ganglion). The other two locations are aorticosympathetic and visceral autonomic groups. From all types, the two most common types are carotid body tumors (sometimes called chemodectomas) and jugulotympanic tumors (often called glomus jugulare tumors) which are located at head and neck regions. Parangliomas are generally a benign tumor, but sometimes develop malignant change with nodal and distant metastasis, so called malignant paraganglioma. They are found only in 5-15% of all paraganglioma tumors.⁴ There are many choices of treatment for paragangliomas including observation, surgery, external beam radiotherapy, and stereotactic radiotherapy. Nevertheless, surgery is the treatment of choice for the operative cases to take tissue for pathological study and provide a chance for total removal of tumors. The local control by surgery alone is approximately 85-100%.⁵ Most of the reports demonstrated local control with radiotherapy alone is approximately 85-100% comparable to surgery.⁵ Huy PT, et al., showed that treatment with radiotherapy can achieve comparable local control and less morbidity than surgical resection in paraganglioma.⁶

Regarding definitive radiation treatment of paraganglioma, there are many techniques, protocols and radiation dose ranges of treatment. Although stereotactic radiotherapy has been increasingly used and their results have been generally accepted,^{7,8} conventional radiotherapy and 3D radiotherapy are still commonly used in the place where stereotactic radiotherapy is not available. Many reports used a radiation dose of 45 Gy in 25 fractions, with a daily dose of 1.8 Gy.^{5,6} In our case, we used 3D-CRT technique which was a quite conformal and precise technique. Since paraganglioma is benign, it theoretically needs higher daily dose in order to achieve better tumor control. Therefore, we chose to use 48 Gy in 16 fractions with 3 Gy for daily dose. After a follow up time of 60 months, the tumor showed clinically complete response by our distinct radiotherapy schedule. Many studies report

good local control from radiotherapy; although, a few studies showed complete response. Huy PT, et al., had used conventional doses of radiation (45 Gy in 25 daily fractions, 1.8 Gy/fraction), and found that only one of 45 patients achieved complete response. However, the others were found to be stable disease and partial response in 69% and 24% of patients respectively.⁶ However, Schild SE, et al., reported that 4 of 9 patients (44.5%) had complete response from radiotherapy, while the others got partial response and stable disease in 11% and 44.5% of patients respectively.² One possible reason for high complete response in the Schild SE study is that there were some patients who received higher daily dose up to 2.4 Gy. In other words, daily dose more than 1.8 to 2 Gy may be more effective and provide higher probability to achieve complete response as found in our patient. For the late complication issue, our patient had no moderate to severe toxicity from our radiation schedule. According to our impression, the radiation schedule of 48 Gy in 16 fractions, 3 Gy/fraction, results in excellent tumor control and acceptable radiation toxicities.

REFERENCES

1. Valdagni R, Amichetti M. Radiation therapy of carotid body tumors. *Am J Clin Oncol.* 1990 Feb;13(1):45-8.
2. Schild SE, Foote RL, Buskirk SJ, Robinow JS, Bock FF, Cupps RE, et al. Results of radiotherapy for chemodectomas. *Mayo Clin Proc.* 1992 Jun; 67(6):537-40.
3. Tumors of the extra-adrenal paraganglion system. *Atlas of Tumor Pathology*, Armed Forces Institute of Pathology, 1974.
4. Manolidis S, Shohet JA, Jackson CG, Glasscock ME, 3rd. Malignant glomus tumors. *Laryngoscope.* 1999 Jan;109(1):30-4.
5. Hinerman RW, Amdur RJ, Morris CG, Kirwan J, Mendenhall WM. Definitive radiotherapy in the management of paragangliomas arising in the head and neck: a 35-year experience. *Head Neck.* 2008 Nov;30(11):1431-8.
6. Huy PT, Kania R, Duet M, Dessard-Diana B, Mazon JJ, Benhamed R. Evolving concepts in the management of jugular paraganglioma: a comparison of radiotherapy and surgery in 88 cases. *Skull Base.* 2009 Jan;19(1):83-91.
7. Wegner RE, Rodriguez KD, Heron DE, Hirsch BE, Ferris RL, Burton SA. Linac-based stereotactic body radiation therapy for treatment of glomus jugulare tumors. *Radiother Oncol.* 2010 Dec;97(3):395-8
8. Guss ZD, Batra S, Li G, Chang SD, Parsa AT, Rigamonti D, et al. Radiosurgery for glomus jugulare: history and recent progress. *Neurosurg Focus.* 2009 Dec;27(6):E5.