



Bilateral Primary Adrenal Lymphoma in a -59 year-old Female

Alireza Ahmadi (MD)¹, Sepideh Namdar (MD)², Sajjad Daneshyar (MD)^{2*}

¹Department of Hematology and Oncology, School of Medicine, Hamedan University of Medical Sciences, Hamedan, Iran.

²Student Research Committee, Hamedan University of Medical Sciences, Hamedan, Iran.

ARTICLE INFO

Article type

Case report

Article history

Received: 31 Oct 2017

Revised: 30 Nov 2017

Accepted: 25 Dec 2017

Keywords

Diffuse large B-cell lymphoma

Metastasis

Primary adrenal lymphoma

ABSTRACT

Occasionally, lymphoma involves the adrenal glands; however, primary adrenal lymphoma (PAL) is rare and only few cases have been reported. We report a case of a 59-year-old female with primary adrenal diffuse large B-cell lymphoma (DLBCL) manifested by weakness, fatigue, anorexia, and hyper pigmentation of skin. The patient initially responded to intravenous hydrocortisone in large doses by total remission of the symptoms. An abdominal computed tomography scan showed a hypodense mass in the right subdiaphragmatic space, which was suggestive of an adrenal gland tumor with adjacent liver involvement. Additionally, a smaller lesion with similar characteristics was found in the left adrenal gland. The results obtained from adrenal gland needle biopsy confirmed the diagnosis of DLBCL. Moreover, primary laboratory findings demonstrated hyponatremia, hyperkalemia, fasting blood sugar level of 153 mg/dl, and alkaline phosphatase level of 663 U/L. The mentioned symptoms and laboratory findings were indicative of adrenal insufficiency. After about 2 months, her level of consciousness decreased and urinary and fecal incontinence occurred. Therefore, brain involvement was suspected, and magnetic resonance imaging of the brain showed heterogeneous enhancement (24.8 mm) in the posterior aspect of the left temporal lobe together with patchy foci of enhancement in around the ventricular areas of the brain that showed metastatic lesions of PAL. This case should remind clinicians that PAL may be a cause of adrenal incidentaloma, especially when the patient presents with the symptoms of adrenal insufficiency.

Please cite this paper as:

Ahmadi A, Namdar S, Daneshyar S. Bilateral Primary Adrenal Lymphoma in a 59-year-old Female. *Rev Clin Med.* 2018;5(1):16-18.

Introduction

Although the adrenal glands have no lymphoid tissue, primary adrenal lymphoma (PAL) can be detected in less than 1% of cases of non-Hodgkin's lymphoma (1). The most common subtype of PAL is diffuse large B-cell lymphoma (DLBCL), which inflicts about 70% of all PAL cases (2,3). PAL is rare and includes less than 1% of patients with extranodal lymphomas. Furthermore, PAL is usually bilateral, while the secondary involvement of the adrenal glands is typically unilateral (4,5).

Primary involvement of the endocrine system in primary extranodal lymphoma is not frequent (3%) and most often involves the thyroid gland (6). Imbalance in immune system such as autoimmune diseases or infection caused by human immunodeficiency virus may predispose to PAL (7). This disease can present with the symptoms of adrenal insufficiency (8). Specifically, PAL predominantly affects elderly patients without nodular lesions.

*Corresponding author: Sajjad Daneshyar.

Student Research Committee, Hamedan University of Medical Sciences, Hamedan, Iran.

E-mail: s.danshyar72@yahoo.com

Tel: +989366531472

This is an Open Access article distributed under the terms of the Creative Commons Attribution License (<http://creativecommons.org/licenses/by/3.0>), which permits unrestricted use, distribution, and reproduction in any medium, provided the original work is properly cited.

The diagnosis of PAL is frequently challenging due to its nonspecific clinical manifestation and imaging results, and histopathology is the only method used to confirm the diagnosis (7). The prognosis of PAL is typically poor, and the one-year survival rate is 17.5% (5). We report a bilateral PAL case that maintained a high degree of clinical suspicion in order to early diagnosis and planning the treatment program.

Case report

A 59-year-old female patient was admitted to the Department of Hematology of Shahid Beheshti Hospital, Hamadan University of Medical Sciences, Hamadan, Iran, in 2015. She presented with weakness, fatigue, anorexia, and hyperpigmentation; in addition, she lost about 15 kg in 2 weeks. The patient's past medical history and drug history were both negative, and her family history was noncontributory. On admission, heart rate, body mass index, respiratory rate, and blood pressure were 62, 21.2, 15, and 160/80, respectively, and she was afebrile.

Regarding the physical examination, no enlarged superficial lymph node was palpable, and the abdomen was soft with no organomegaly or abdominal tenderness. According to the review of the body systems, the patient had no history of tachycardia, palpitation, flushing, headache, or chest pain. Initial laboratory test showed hyponatremia with a sodium level of 133 mmol/L (with the normal range of 136-146 mmol/L) and hyperkalemia with a potassium level of 5.2 mmol/L (with the normal range of 3.5-5.1 mmol/L). The levels of fasting blood sugar and alkaline phosphatase were 153 mg/dl and 663 U/L, respectively. The levels of the liver transaminases were normal.

Considering the mentioned symptoms and laboratory findings, adrenal insufficiency was suspected and an adrenocorticotrophic hormone stimulation test was performed. An intravenous contrast-enhanced spiral computed tomography (CT) scan of the abdomen and chest showed a mass in the right subdiaphragmatic space, superior to the right kidney and posterior to the liver, which led to the movement of inferior vena cava and liver.

These characteristics were indicative of an adrenal gland tumor with adjacent liver involvement (Figure 1). Moreover, a smaller lesion with similar specifications was observed in the left adrenal gland. The evaluation of the bone marrow biopsy and aspiration detected no bone marrow metastasis. Upper gastrointestinal endoscopy demonstrated erosive gastritis and the duodenum was normal. To obtain a diagnosis and possibly treat the patient, needle biopsy was performed from

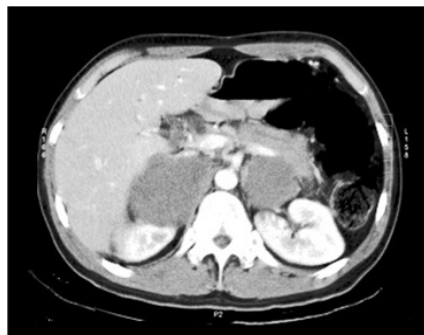

Figure 1. Computed tomography images of the abdomen revealed a hypo dense mass in the right sub diaphragmatic area , superior to the right kidney which was suggestive of an" adrenal tumor " with adjacent hepatic involvement.

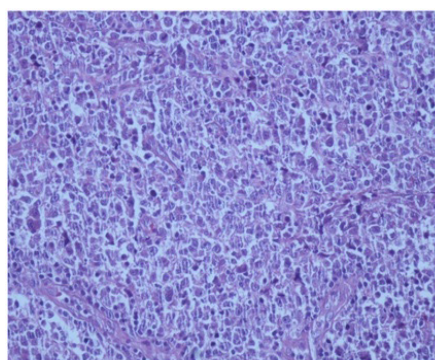


Figure 2. Histopathology image for Diffuse large B-cell lymphoma.

the left adrenal gland and histopathological examination revealed the presence of DLBCL (Figure 2).

After about 2 months, she experienced a depressed level of consciousness and urinary and fecal incontinence, which led to the diagnosis of the brain metastasis. The magnetic resonance imaging of the brain (with and without contrast) revealed homogenous contrast enhancement (24.8 mm) in the posterior aspect of the left temporal lobe together with patchy foci of enhancement in around the ventricular areas of the brain. After 4 months of the final diagnosis, the patient died despite receiving three sessions of chemotherapy in 2 months.

Discussion

Nowadays, with the increasing use of abdominal CT scans, more adenomas of the adrenal glands are incidentally detected (9). The exact pathogenesis of PAL remains to be determined; nevertheless, multifactorial associations have been described including autoimmunity-associated infectious diseases (e.g., infectious mononucleosis), immune dysfunction, originating from hematopoietic tissue resting within adrenal glands, and the mutations of the p53 and c-kit genes (10,11).

The tumors of the adrenal glands may be either

primary or secondary neoplasm. Primary adrenal tumors mainly consist of adenomas, adrenal carcinomas, adrenal cysts, pheochromocytomas, ganglioneuromas, and myelolipomas (7). Less than 5% of the adrenal incidentalomas are malignant and only 1 in 7 shows excessive production of any adrenal hormones including cortisol, catecholamines, and aldosterone (12).

DLBCL is the predominant histological subtype of adrenal tumors, which includes about 70% of PAL cases, whereas the T-immunophenotype subtype constitutes about 10% of all cases (13). PAL is an extremely rare disease and less than 100 cases have been reported in the last 40 years. Lymphoma may spread to other parts of the body and the involvement of the adrenal glands in malignant lymphoma is reported in 25% of autopsies (14).

Furthermore, adrenal glands have a rich blood supply; therefore, hematogenous metastasis to these glands is much more common than lymphatic metastasis. The most frequent cause of adrenal tumors is the metastatic infiltration of carcinomas originating from the lungs, breast, skin, and colon (15). Brain metastasis was detected in our patient. CT scan is the primary imaging study leading to the diagnosis of adrenal incidentalomas.

The clinical diagnosis of PAL is typically challenging due to its nonspecific clinical manifestations and uncommon presentations. Nonetheless, Ellis and Read showed that the most common symptoms of bilateral adrenal lymphomas are abdominal pain (67%), weight loss (67%), and fatigue or weakness (44%) (16). All of these symptoms can be observed in patients with adrenal insufficiency.

Our patient presented in this paper had no abdominal pain; however, she reported both weight loss and fatigue. In addition, the diagnosis of PAL is confirmed only with pathological evaluations (2). There are several treatment modalities including chemotherapy, surgery, surgery with chemotherapy or radiotherapy, and corticosteroid replacement therapy. Nevertheless, the prognosis of this disease is poor and the increased level of serum lactate dehydrogenase, advanced age, adrenal insufficiency, bilateral involvement, large tumor size, and the involvement of the other organs (15).

Most of the patients with PAL have a limited time of survival. The complete remission of the disease after the initiation of chemotherapy was reported in a few patients. Former studies indicated no remission in two patients with 12 months and 7 years follow-ups (1). Unfortunately, our patient died after receiving three sessions of chemotherapy.

Conclusion

Bilateral primary adrenal DLBCL is a rare disease. Considering the poor prognosis of PAL, early diagnosis is important to improve the survival rates.

Acknowledgement

The present study was supported by the Hamedan University of Medical Sciences, Hamedan, Iran.

Conflict of Interest

The authors declare no conflict of interest.

References

1. Mozos A, Ye H, Chuang WY, et al. Most primary adrenal lymphomas are diffuse large B-cell lymphomas with non-germinal center B-cell phenotype, BCL6 gene rearrangement and poor prognosis. *Mod Pathol*. 2009;22:1210-1217.
2. Erçolak V, Kara O, Günaldı M, et al. Bilateral Primary Adrenal Non-Hodgkin Lymphoma. *Turk J Haematol*. 2014;31:205-206.
3. Sánchez CDM, Ruiz L, González JL, et al. Acute adrenal insufficiency secondary to bilateral adrenal B-cell lymphoma: a case report and review of the literature. *Ecancermedicalscience*. 2016 ;10:634.
4. Hsu CW, Ho CL, Sheu WH, et al. Adrenal insufficiency caused by primary aggressive non-Hodgkin's lymphoma of bilateral adrenal glands: report of a case and literature review. *Ann Hematol*. 1999;78:151-154.
5. Kim YR, Kim JS, Min YH, et al. Prognostic factors in primary diffuse large B-cell lymphoma of adrenal gland treated with rituximab-CHOP chemotherapy from the Consortium for Improving Survival of Lymphoma (CISL). *J Hematol Oncol*. 2012;5:49.
6. Kim KM, Yoon DH, Lee SG, et al. A case of primary adrenal diffuse large B-cell lymphoma achieving complete remission with rituximab-CHOP chemotherapy. *J Korean Med Sci*. 2009;24:525-528.
7. Wakabayashi M, Sekiguchi Y, Shimada A, et al. Diffuse large B-cell lymphoma solely involving bilateral adrenal glands and stomach: report of an extremely rare case with review of the literature. *Int J Clin Exp Pathol*. 2014;7:8190-8197.
8. Kacem K, Zriba S, Lakhil RB, et al. Primary adrenal lymphoma. *Turk J Haematol*. 2014;31:188-191.
9. Korobkin M, Francis IR, Kloos RT, et al. The incidental adrenal mass. *Radiol Clin North Am*. 1996;34:1037-1054.
10. Ohsawa M, Tomita Y, Hashimoto M, et al. Malignant lymphoma of the adrenal gland: its possible correlation with the Epstein-Barr virus. *Mod Pathol*. 1996;9:534-543.
11. Padhi S, Sahoo J. Primary adrenal non Hodgkin lymphoma: changing trends. *Turk J Gastroenterol*. 2015;26:85-86.
12. Bilow B, Ahrén B. Adrenal incidentaloma—experience of a standardized diagnostic programme in the Swedish prospective study. *J Intern Med*. 2002;252:239-246.
13. Li Y, Sun H, Gao S, et al. Primary bilateral adrenal lymphoma: 2 case reports. *J Comput Assist Tomogr*. 2006;30:791-793.
14. Holm J, Breum L, Stenfeldt K, et al. Bilateral primary adrenal lymphoma presenting with adrenal insufficiency. *Case Rep Endocrinol*. 2012;2012:638298.
15. Aziz SA, Laway BA, Rangreze I, et al. Primary adrenal lymphoma: Differential involvement with varying adrenal function. *Indian J Endocrinol Metab*. 2011;15:220-223.
16. Ellis R, Read D. Bilateral adrenal non-Hodgkin's lymphoma with adrenal insufficiency. *Postgrad Med J*. 2000;76:508-509.