

## **RHINO-ORBITO-CEREBRAL MUCORMYCOSIS IN BASRAH - IRAQ**

**Ahmed M Al-Abbasi<sup>@</sup>, Ali Abdil-Wahab<sup>#</sup>, Abdil Razak Al-Jezani<sup>\$</sup>, Haider Sabri Hashim<sup>\*</sup> & Duraid Ahmed Al-Temimi<sup>&</sup>.**

<sup>@</sup>FICMS, FRCS, Professor of Otolaryngology, Basrah College of Medicine. <sup>#</sup>CABS, Otolaryngologist, Basrah General Hospital. <sup>\$</sup>FICMS, Neurosurgeon, AlSadir Teaching Hospital. <sup>\*</sup>FICMS, Otolaryngologist, Basrah General Hospital. <sup>&</sup>CABS, Otolaryngologist, Al Sadir Teaching Hospital, Basrah, IRAQ.

### **Abstract**

This study was designed to through some light on mucormycosis infection, its stages, risk factors, presenting clinical features and to suggest early diagnostic techniques.

A prospective explanatory study was carried out in the period between March 2011 to March 2016 for patients proved to be affected by this disease in Basrah General Hospital and different departments from all teaching hospitals in Basrah.

The total studied patients were 32 with male to females ratio 2.2:1. The mostly affected age group was those between 51-60 years (16 patients, 50%). Seventeen patients (53.1%) belonged to stage I, nine (28.1%) to stage II, the remaining 6 patients(18.7%) to stage III. Majority of affected patients were immuno-compromised 27(84.3%). Diabetes mellitus was the main single risk factor (12 patients, 44.4%). The commonest recorded symptom was facial pain and numbness in 27 patients (84.3%), and the most common sign was nasal crustations and eschar in 28 patients(87.5) .

This study concluded that surgeons should have an index of suspicion to be aware about this condition among the community, this can help in taking early preventive measures.

### **Introduction**

**M**ucormycosis is a term demonstrates a wide range of illnesses caused by infection commonly caused by Rhizopus species of fungi. In down sequence, other genera mucormycosis causing species includes Mucor, Cunninghamella, Apophysomyces, Absidia, Saksenaea, Rhizomucor, and several others. Most mucormycosis infections are extreme specially with risk factors, for example, diabetic ketoacidosis and neutropenia which are found in the majority of cases. Serious infection of the paranasal sinuses which may expand to the brain, is the widely recognized presentation<sup>1,2</sup>.

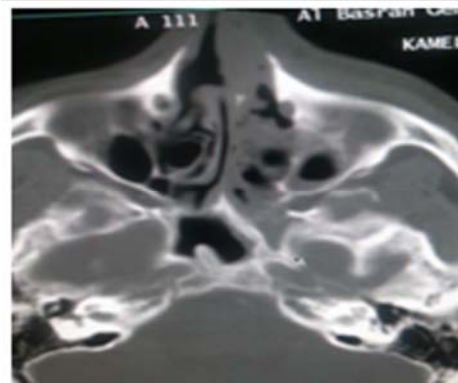
The infection happens following inward breath of contagious sporangiospores into the paranasal sinuses, and may then quickly extend into adjacent tissues<sup>3</sup>. Once the attacking fungus germinated, it will grow posteriorly to invade the sphenoid sinus, laterally to the cavernous

sinus to attack the orbits, inferiorly to attack the palate, or cranially to assault the brain<sup>4</sup>. The fungus goes intracranially all through either the orbital apex or ethmoid cribriform plate and this can lead to death. Occasionally, cerebral vascular invasion can lead to hematogenous distribution of the disease with or without progression of mycotic aneurysms<sup>5</sup>.

Mucormycosis ought to be considered as a medico-surgical crisis, antifungal therapy should be prescribed at any minor suggestion of the illness. Likewise, patients should have endoscopic assessment immediately so as to survey sinonasal structures and to take appropriate samples for histopathologic and microbiologic testing. Direct nasal smear and fungal cultures are helpful in the diagnosis, although negative results does not exclude the disease. Intraoperative frozen section is a specific

and sensitive strategy for making a quick conclusion of rhinocerebral zygomycosis. Discovery of non-septate, branching (at 90 degrees) hyphae without granuloma formation in the biopsy establishes the diagnosis. Fine-needle aspiration cytology seems to be a practical option to tissue biopsy. Computed tomography(CT) (fig.1), or magnetic resonance imaging (MRI) is fundamental for staging the

level of the condition as penetration of periantral fat planes may indicate the initial imaging proof of invasive fungal disease and should suggest the likelihood of invasive fungal sinusitis<sup>6</sup>. sufficient debridement for removal of all devitalized tissue up to healthy or bleeding borders is vital, and multiple debridements may be necessary in few patients<sup>7</sup>.



**Figure 1: Non-homogenous hyperdensity of right maxillary sinus**

The result of management is fine when the condition is anatomically constrained to the sinuses. In a study in India, the success rate of the treatment in stage I illness was 91%<sup>8</sup>. The contention for careful debridement of all influenced tissue in patients with mucormycosis, depends on the capacity of the fungus to expand along the walls and blood vessels lumen which can bring about necrotising arteritis and ischemic necrosis of the tissues prompting poor distribution of systemically administered drugs<sup>9,10</sup>.

### **Patients and Methods**

This is a prospective cross-sectional analytical study performed in the period between March 2011 to March 2016, in Basrah General Hospital. The study included all patients proved to have mucormycosis histopathologically and were admitted or referred to Basrah General Hospital. A special questionnaire form was prepared by the authors and filled by house officer doctors of the ward. Initial investigations included

complete blood counts, blood urea, serum creatinine, serum glucose. Rigid nasal endoscopy and biopsy was done for all patients and suspicious tissue was sent for histopathology. Computed tomography scanning of the paranasal sinuses, orbit, and brain, including axial and coronal sections was performed in all the cases to determine the extent of the disease.

Magnetic resonance imaging was performed only for 9 patients suspected to have intracranial invasions (having neurological abnormalities) but only 6 of them had real intracranial invasion.

The diagnosis was made in all cases by the presence of non-septate branching hyphae on histopathologic sections. The treatment was considered according to the currently suggested methods in textbooks. Following surgery (debridement) which was performed for all patients except six (4 has cerebral invasion and 2 refuse treatment), all patients were followed closely for disease progression and repeated debridement was done when necessary.

**Results**

This study included thirty two patients with mucormycosis, 22 (68.75%) were males and 10(31.25) were females, male to female ratio was 2.2:1. Age distribution of patients with mucor-

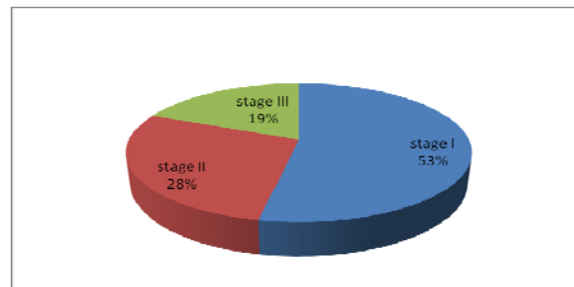
mycosis is shown in table I, the commonly affected age group was 51-60 years comprised 50% of the cases, while no patient was reported in ages between 11 to 40 years.

**Table I: Age and gender distribution of patients participating in this study.**

Age group	Males	Females	Total
0-10	2	1	3(9%)
11-20	0	0	0(0%)
21-30	0	0	0(0%)
31-40	0	0	0(0%)
41-50	2	1	3(9%)
51-60	12	4	16(50%)
61-70	1	2	3(9%)
70+	5	2	7(21.8%)
Total	22	10	32(100%)

Clinical stages of mucormycosis was shown in figure 2. Seventeen patients (53.1%) belonged to stage I (sino-nasal

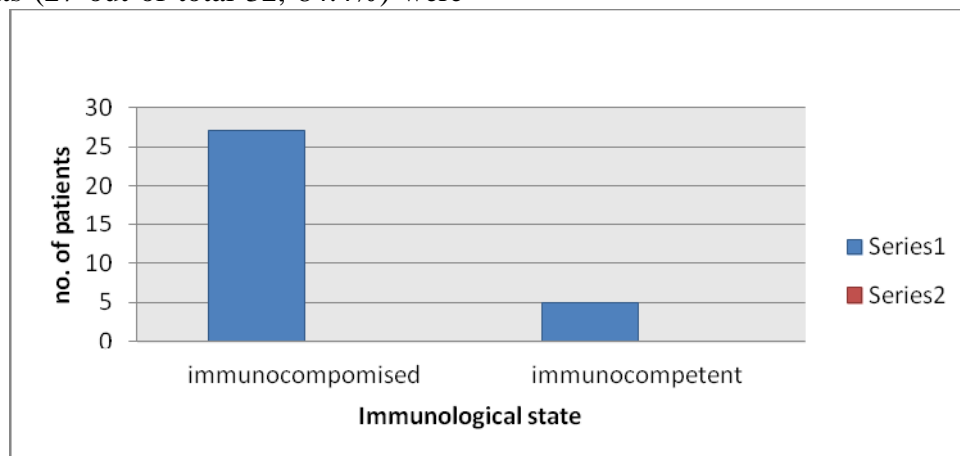
stage), 9 (28.1%) to stage II (rhino-orbital stage), the remaining 6 patients(18.7%) to stage III (rhino-obito-cerebral stage).



**Figure 2: Clinical stages of mucormycosis**

The immunological status of patients with mucormycosis is shown in figure 3, it is found that the majority of the studied patients (27 out of total 32, 84.4%) were

immuno-compromised, while the remaining 5 (15.6%) patients were immuno-competent.



**Figure 3: Immunological states of studied patients**

The majority of immuno-compromised patients were diabetics 14 (51.9%), followed by renal failure in which 8 patients (29.6%) were reported, 3 were leukemic children and 2 patients were

affected by lymphomas, one child had renal cell carcinoma for which cytotoxic drugs were given and 4 patients had multiple risk factors as demonstrated in figure 4.

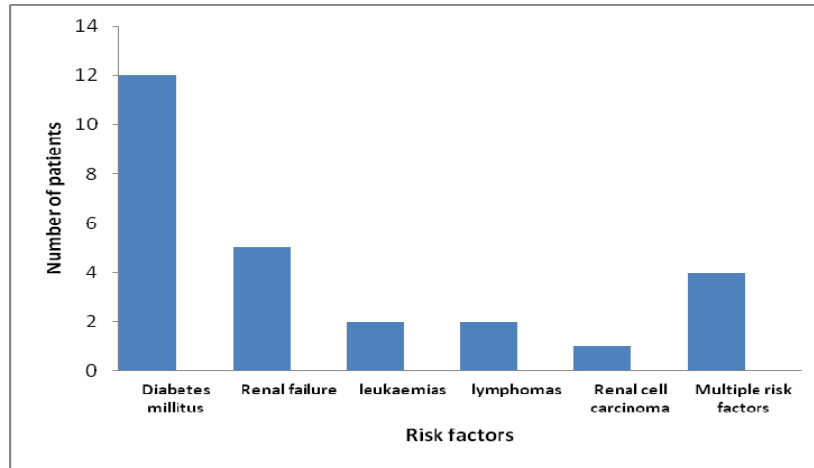


Figure 4: Risk factors for patients with mucormycosis

The distribution of symptoms and signs is illustrated in table II, it was found that the most frequent symptoms were facial pain and numbness (27, 84.3%), followed by

headache (20, 62.5%), nasal obstruction and anosmia (20, 62.5%), while the most frequent sign was nasal obstruction and eshcar (28, 87.5%).

Table II: Distribution of presenting symptoms and signs.

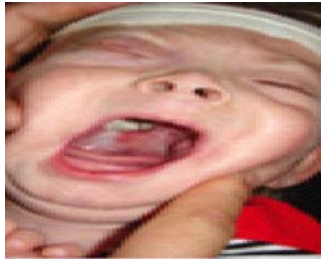Symptoms	No.	%	Signs	No.	%
Facial pain and numbness	27	84.3	Nasal crustation and eshcar	28	87.5
Headache	20	62.5	Facial edema	13	40.6
Nasal obstruction and anosmia	20	62.5	Periorbital oedema and redness	9	28.1
Fever	11	34.3	Ptosis	9	28.1
Ptosis	9	28.1	Turbinate necrosis	7	21.8
Nasal discharge	7	21.8	Palatal ulceration and perforation	6	18.7
Dizziness and vertigo	5	15.6	Facial palsy	5	15.6
Blurred vision	5	15.6	Altered mental function	2	6.2
			Dischrnging facial fistula	1	3.1

## Discussion

Rhino-orbito-cerebral (ROC) mucormycosis is generally uncommon disease<sup>11</sup>. The reasonable frequently diagnosed ROC mucormycosis in our community is most likely because of poor health care standard with low socio-economic and educational levels. In the

present study, males are more affected than females, the proportion was 2.2:1, probably in light of the fact that hazard factors were more typical in males in addition they have more exposure to infective organisms due to outdoor work. The mostly affected age group by ROC

mucormycosis in this study was 51-60 years(50%). Three kids have the disease in this series (9%) (figure 5).

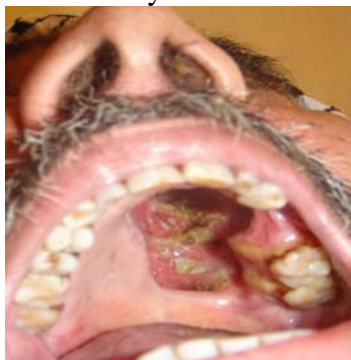

**Figure 5: Palatal perforation and crustation in a child with mucormycosis.**

The significant thing is that 5 out of 32 patents were immunocompetent, that raise the reality that ROC mucormycosis not just influence those with high risk. Invasive fungal diseases recently have been accounted to be increasing in immunocompetent patients.

Environmental and local variables may influence normal hosts and increases patient's hazard for having fungal paranasal sinus infections, including repetitive contact to food or air which is contaminated with mycotic spores. Root canal fillings, exposure to residential pets, chronic or recurrent bacterial sinusitis, and a long-standing use of wide-spectrum antibiotics or topical steroid use are also threat factors<sup>11</sup>.

The most widely recognized risk factor in this study is uncontrolled DM which constitutes 44.4% of the cases (figure 6), this runs with many authors<sup>12-14</sup>.



**Figure 6: Diabetic patient with perforated palate due to mucormycosis.**

As indicated by many investigations, the most essential conditions make patients susceptible to mucormycosis, comprise

malignant blood disease with or without stem cell transplantation, uncontrolled diabetes mellitus with or without diabetic ketoacidosis, long time and serious neutropenia, overload of iron, significant trauma, prolonged use of corticosteroids, illegal intravenous drug use, neonatal prematurity and malnourishment<sup>15</sup>. Apart from host-related risk factors, bad hospital environment may be responsible. Nosocomial mucormycosis has been related to contact air loaded with fungus because of building work, unhygienic air filters, or a variety of healthcare-related methods and equipments such as non-sterilized dressings of the wound, transdermal nitrate patches, intravenous catheters, tongue depressors or allopurinol pills<sup>16</sup>. Minimal iatrogenic outbreaks have been occurred<sup>17,18</sup>.

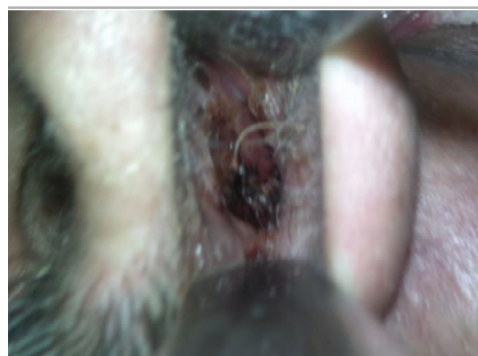In 36%–88% of the patients, diabetes mellitus is the primary predisposing reason for mucormycosis<sup>19-21</sup>, the most vulnerable are those with ketoacidosis<sup>22,23</sup>. Various patients with undiscovered or uncontrolled diabetes, mucormycosis is the first incident<sup>24</sup>. In fact, type1, type2, and secondary diabetes mellitus are hazard factors for mucormycosis<sup>25</sup>. The epidemiology of mucormycosis in diabetic cases is rising, Roden et al<sup>15</sup> found that diabetes includes 36% of 929 reported cases, yet there was a diminished recurrence of mucormycosis in diabetics with time. Nevertheless, mucormycosis remains an frightening hazard in diabetics<sup>26</sup>. A comprehensive retrospective study in France showed 9% annual increase in incidence of mucormycosis in diabetics<sup>27</sup>. In India, a study exhibited that 74% of cases with mucormycosis had uncontrolled diabetes; in 43% of them, diabetes was diagnosed for the first time<sup>28</sup>.

The frequently reported symptoms in the present investigation are; facial agony, numbness, headache, nasal discharge and anosmia, and the most widely recognized signs were; nasal crustation, eschar and



facial edema. These results goes with Spellberg and Talmi studies<sup>13,29</sup>.

The initial symptoms of ROC mucormycosis runs with those of sinusitis and periorbital cellulitis and include eye and or facial pain with numbness followed by visual impairment<sup>3</sup>. Clinical features that suggest mucormycosis in vulnerable individuals includes; headache, multiple cranial nerve palsies, orbital inflammation, eyelid edema, one-side periorbital facial pain, proptosis, ptosis, ophthalmoplegia, acute ocular motility changes, and acute loss of vision. A dark necrotic eschar is a trademark feature of mucormycosis (figure 7), but the absence of this finding does not exclude the likelihood of mucormycosis. Fever is conflicting and may not present in up to half of cases. The white blood cell count is classically high as long as the patient has working bone marrow<sup>30</sup>.



**Figure 7: Black crustation of nasal mucosa in a patient with mucormycosis.**

Conclusion; Index of suspicion by general practitioner, physician, and ENT house officer is very necessary in diagnosis of RCO mucormycosis. The disease can affect even immunocompetent persons, and early diagnosis by histopathological assessment of necrotic tissue is very supportive for earlier start of management.

## References

- 1.Kontoyiannis DP, Lewis RE. Agents of mucormycosis and Entomophthoromycosis. Mandell GL, Bennett GE, Dolin R, eds. Mandell, Douglas and Bennett's Principles and Practice of Infectious Diseases. 7th ed. Philadelphia, Pa: Churchill Livingstone; 2010. 3257-69.
- 2.Kwon-Chung KJ. Taxonomy of fungi causing mucormycosis and entomophthoromycosis (zygomycosis) and nomenclature of the disease: molecular mycologic perspectives. Clin Infect Dis. 2012 ; 54 Suppl 1:8-15.
- 3.RibesJA, Vanover-SamsCL, BakerDJ. Zygomycetes in human disease, Clin Microbiol Rev. 2000; 13 : 236-301
- 4.HosseiniSM, BorgheiP. Rhinocerebral mucormycosis: pathways of spread, Eur Arch Otorhinolaryngol. 2005; 262 : 932-8.
- 5.OrgucS, YuceturkAV, DemirMA, GoktanC. Rhinocerebral mucormycosis: perineural spread via the trigeminal nerve, J Clin Neurosci . 2005;12: 484-6.
- 6.Dhiwakar M. Thakar A, Bahador S. Improving outcomes in rhinocerebral mucormycosis: Early diagnostic pointers and prognostic factors. J Laryngol Otol 2003; 117: 861-5.
- 7.Ferguson BJ. Mucormycosis of the nose and paranasal sinuses. Otolaryngol Clin North Am .2000; 33: 349-65.
- 8.S Nithyanandam, Moire S Jacob, Ravindra R Battu, Reji K Thomas, Majorie A Correa, O D'Souza. Rhino-Orbito-Cerebral Mucormycosis. A Retrospective Analysis of Clinical Features and Treatment Outcomes. 2003 ; 51 : 231-236.
- 9.Ochi JW, Harris JP, Feldman JJ, Press GA. Rhinocerebral mucormycosis: Results of aggressive surgical debridement and amphotericin B. Laryngoscope. 1988; 98:1339-42.
- 10.Abedi E, Sismanis A, Choi K, Pastore P. Twenty-five years experience treating cerebro-rhino-orbital mucormycosis. Laryngoscope.1984; 94:1060-62.
- 11.Antonio Mastroianni. Le Infezioni in Medicina, n Paranasal sinus mucormycosis in an immunocompetent host: efficacy and safety of combination therapy with liposomal amphotericin B and adjuvant rHuGM-CSF.2004; 4: 278-283.
12. O'Neill BM, Alessi AS, George EB, Piro J. Disseminated rhinocerebral mucormycosis: a case report and review of the literature. J Oral Maxillofac Surg .2006; 64(2): 326-333.
13. Spellberg B, Edwards J JR, Ibrahim A. Novel perspectives on mucormycosis: patho-physiology, presentation, and management. Clin Microbiol Rev. 2005; 18(3): 556-569.
14. Nithyanandam S, Jacob MS, Battu RR, Thomas RK, Correa MA, D'Souza O. Rhino-orbito-cerebral mucormycosis. A retrospective analysis of clinical features and treatment outcomes Indian J Ophthalmol. 2003 Sep;51(3):231-6..
- 15.RodenMM, ZaoutisTE, BuchananWL, et al . Epidemiology and outcome of mucormycosis: a review of 929 reported cases, Clin Infect Dis. 2005;41:634-53
- 16.PetrikkosGL, SkiadaA, SambatakouH, et al . Mucormycosis: ten year experience in a tertiary-care centre in Greece, Eur J Clin Microbiol Infect Dis . 2003; 22: 753-6
- 17.AntoniadouA. Outbreaks of mucormycosis in hospitals, Clin Microbiol Infect 2009;15 : 5. 55-9
- 18.ChengVC, ChanJF, NganAH, et al . Outbreak of intestinal infection due to Rhizopus microsporus, J Clin Microbiol . 2009;47: 2834-43.
- 19.LudvigssonJ. Why diabetes incidence increases—a unifying theory, Ann N Y Acad Sci .2006; 1079 : 374-82.
- 20.JoshiN, CaputoGM, WeitekampMR, KarchmerAW. Infections in patients with diabetes mellitus, N Engl J Med . 1999; 341:1906-12.
- 21.ChayakulkeereeM, GhannoumMA, PerfectJR. Mucormycosis: the re-emerging fungal infection, Eur J Clin Microbiol Infect Dis.2006; 25: 215-29.
- 22.GreenbergRN, ScottLJ, VaughnHH, RibesJA. Zygomycosis (mucormycosis): emerging clinical importance and new treatments, Curr Opin Infect Dis . 2004; 17 :517-525.
- 23.Helderman JH, CooperHS, MannJ. Chronic phycormycosis in a controlled diabetic, Ann Intern Med. 1974; . 80: 419 .
- 24.BhansaliA, BhadadaS, SharmaA, et al . Presentation and outcome of rhino-orbital-cerebral mucormycosis in patients with diabetes, Postgrad Med J . 2004; 80: 670-4.
- 25.ChamilosG, LewisRE, KontoyiannisDP. Lovastatin has significant activity against zygomycetes and interacts synergistically with voriconazole, Antimicrob Agents Chemother . 2006; 50: 96-103.
- 26.ReedC, BryantR, IbrahimAS, et al . Combination polyene-caspofungin treatment of rhino-orbital-cerebral mucormycosis, Clin Infect Dis .2008; 47: 364-71.
- 27.MokCC, QueTL, TsuiEY, LamWY. Mucormycosis in systemic lupus erythematosus ,SeminArthritisRheum. 2003;33: 115-24.
- 28.ChakrabartiA, DasA, MandajJ, et al . The rising trend of invasive mucormycosis in patients with uncontrolled diabetes mellitus, Med Mycol . 2006; 44: 335- 42.
- 29.TalmiYP.Goldschmeid-Reouven A. Bakon M, et al. Rhino-orbital and rhino-orbitocerebral mucormycosis, Otolaryngol Head Neck Surg . 2002; 127: 22- 31.
- 30.George Petrikkos, Anna Skiada, Olivier Lortholary, Emmanuel Roilides, Thomas J. Walsh, Dimitrios P. Kontoyiannis, Epidemiology and Clinical Manifestations of Mucormycosis Clinical Infectious Diseases. 2012; 54:23–34.