

## Journal of Coastal Life Medicine

journal homepage: www.jclmm.com



Original article

doi: <https://doi.org/10.12980/jclm.5.2017J6-219>

©2017 by the Journal of Coastal Life Medicine. All rights reserved.

## Impact of ginger aqueous extract on carbimazole induced testicular degenerative alterations and oxidative stress in albino rats

Saber Abdel-Rahman Sakr\*, Sobhy Elsaid Hassab ELnaby, Yosry Aly Okdah, Ahmed Mohamed El-Shabka

Zoology Department, Faculty of Science, Menoufia University, Shebin El-kom, Egypt

## ARTICLE INFO

## Article history:

Received 21 Oct 2016

Received in revised form 7 Nov, 2nd

revised form 11 Nov 2016

Accepted 23 Feb 2017

Available online 27 Apr 2017

## Keywords:

*Zingiber officinale*

Carbimazole

Testis

Histology

Immunohistochemistry

Oxidative stress

## ABSTRACT

**Objective:** To evaluate the effect of ginger (*Zingiber officinale*) aqueous extract, a natural herb, with antioxidant properties, on testicular toxicity and oxidative stress induced by the antithyroid drug carbimazole in albino rats.

**Methods:** Four groups of male albino rats were used. Group I served as control. Group II rats were treated with ginger aqueous extract (24 mg/mL). Group III rats were given orally carbimazole (1.35 mg/kg bw). Group IV rats were given carbimazole and ginger extract. Animals were sacrificed and their testes were removed and stained with H&E for histological examination. Sperms were collected from epididymis for detection of sperm head abnormalities. Immunohistochemical expression of PCNA and Bax was detected in the testes. MDA, CAT and GSH were measured in the sera.

**Results:** Treating rats with carbimazole revealed significant alterations in the tissue of testis including decreased seminiferous epithelium height, decreased diameter of seminiferous tubule and changes in the spermatogenic layers arrangement. Intertubular hemorrhage and congested blood vessels were noted. An increase in sperm head abnormalities was recorded. Decreased cell proliferation was reflected by a decrease in PCNA expression, while the increase in apoptotic rate was accompanied with an increase in Bax expression. Oxidative stress was demonstrated by an increase in malondialdehyde and decrease in activity of catalase and glutathione. Combined treatment of carbimazole and aqueous ginger extract led to an improvement in histological, morphometrical, immunohistochemical changes and oxidative stress induced by carbimazole.

**Conclusions:** The ameliorative effects of ginger extract could be due to its antioxidant properties.

## 1. Introduction

Carbimazole is an antithyroid pharmaceutical utilized for treatment of Graves' disease worldwide and can likewise be utilized for the treatment of different diseases causing hyperthyroidism, for example, harmful nodular goiter. Carbimazole is a specialist drug as after ingestion it is changed over to the dynamic shape, methimazole. Methimazole keeps the thyroid peroxidase protein from coupling and iodinating the tyrosine stores on thyroglobulin, consequently diminishing the making of the thyroid hormones T3 and T4 (thyroxin)[1]. The use of carbimazole created a few side effects. Vilchez *et al.*[2] reported that carbimazole treatment realized both minor (*e.g.* pruritus, rash, urticaria, fever and

arthralgias) and conceivably life-threatening (*e.g.* agranulocytosis, hepatotoxicity with extraordinary cholestatic jaundice) impacts. It was reported that around 22 cases of cholestatic jaundice resulted from both methimazole and carbimazole[3]. Ali *et al.*[4] reported that carbimazole caused mild necrosis of renal tubules in rats. Pneumonic drain and necrotizing glomerulonephritis were accompanied with treatment of carbimazole[5]. Treating rats with carbimazole demonstrated various testicular modifications including clog of veins, degenerated interstitial tissue and degeneration of spermatogenic cells with apoptosis and necrosis[6]. Different impacts of carbimazole include increment of lipid peroxidation and reduction of the antioxidant enzymes[7].

Numerous characteristic items are being utilized to shield the tissues from different medications or chemicals-prompted toxicities. Ginger (*Zingiber officinale*), belongs to the family Zingiberaceae, is one among the plants which assume a critical part in pharmacology and treatment of different illnesses. In conventional Chinese and Indian medication, ginger has been utilized for treatment of an

\*Corresponding author: Saber Abdel-Rahman Sakr, Zoology Department, Faculty of Science, Menoufia University, Shebin El-kom, Egypt.

E-mail: sabsak@yahoo.com

The journal implements double-blind peer review practiced by specially invited international editorial board members.

extensive variety of diseases including stomach throbs, the runs, queasiness, asthma and respiratory clutters[8]. Ginger extract has different biological activities such as anticancer, antioxidant, anti-inflammation and antimicrobial effects[9,10]. Marx *et al.*[11] reported that ginger lessened platelet accumulation. As of late, ginger has obtained wide consideration because of its antiemetic and anticancer effects[12,13]. It was demonstrated that the long-term dietary addition of ginger has hypoglycemic and hypolipidemic effects[14]. Ginger diminishes testicular apoptosis in rats treated with gentamicin[15]. Mukherjee *et al.*[16] reported that ginger concentrate can improve phosphamidon affected oxidative stress and hepatotoxicity. It was reported that *Z. officinale* has ameliorative impact on testicular toxicity induced by metiram and this might be due to its antioxidant properties[17]. The present work focused on the impact of ginger concentrate on carbimazole-induced testicular changes in male albino rats.

## 2. Materials and methods

### 2.1. Ginger extract

Ginger (*Z. officinale*) rhizome was purchased from Shebin El-kom, Egypt. It was identified by a botanist at Botany Department, Faculty of Science, Menoufia University. One kilogram of ginger rhizome was cleaned, washed with running water, cut into little pieces, air dried and powdered. Then 125 g of the powder was macerated in 1000 mL of distilled water for 12 h at room temperature and separated. The concentration was 24 mg/mL. Every animal in the present study was orally given 1 mL of the concentrate[10]. The parts from new, dried, blend broiling and carbonized ginger concentrates were evaluated chromatographically by using the method of Li *et al.*[18] and five fundamental constituents (zingerone, 6-gingerol, 8-gingerol, 6-shogaol and 10-gingerol) were recorded.

### 2.2. Carbimazole

Carbimazole (antithyroid medication delivered by CID, Egypt) was bought from a nearby drug store as 5 mg/tablet.

### 2.3. Animal models and groups treatments

Mature male albino rats (*Ratus norvegicus*) weighing ( $120 \pm 5$ ) g were used. Rats were kept in the research facility with controlled temperature ( $24 \pm 2$ ) °C throughout the experiment. They were fed on a standard rat food made by 20% casein, 15% corn oil, 55% corn starch, 5% salt blend, and 5% vitaminized starch (Egyptian Company of Oils and Soap, Kafr-Elzayat, Egypt). Water was provided freely. The procedures of this experiment were in accordance with the guide for care and use of laboratory animals approved by Menoufia University, No.H1521. Rats were separated into 4 groups with 10 rats in each group. Group I rats were used as controls and were given physiological saline (0.9% NaCl). Group II rats were given 1 mL of ginger aqueous extract orally by a stomach tube (24 mg/mL) daily for three and six weeks. Group III rats were orally given carbimazole 1.35 mg/kg bw, equivalent to the therapeutic dose for human dissolved in distilled water by stomach tube[19]. Group IV rats were orally given 24 mg/mL of ginger extract by stomach tube followed by carbimazole (1.35 mg/kg bw) for three and six weeks.

### 2.4. Histological preparations

Five rats from every group were sacrificed after 3 and 6 weeks of the experiment. Promptly after execution, rats were dismembered, and testis was removed and fixed in 10% formalin liquid. After fixation, samples were dehydrated in a series of alcohol, cleared in two changes of xylene and embedded in liquid paraffin (mp. 50–58 °C). Then sections of 5 microns thickness were cut utilizing Reichert Jung 2030 microtome (West Germany) and mounted on clean slides without utilizing any glue medium. For histopathological examination, sections were stained with Ehrlich's haematoxylin and counterstained with eosin. The diameter of seminiferous tubules and height of the germinal epithelium were measured in the normal spermatogenic cells on the inner surface of the basement membrane through the most advanced cell types lining the lumen of the tubules.

### 2.5. Sperm head abnormalities

The suspensions of sperm were set up from cauda epididymis of rats by mincing the cauda in 2 mL of phosphate supported physiological saline. The resulting suspension was pipetted and filtered through an eighty micrometer stainless steel mesh to remove the tissue fragments. A suitable portion of every suspension was then blended in ratio of 10:1 with 1% eosin Y stain in distilled water and spread on a slide after 30 min to make the smears, left in air to dry, and were mounted under a cover slip with DPX. Then 1000 sperm cells in every suspension were analyzed for sperm head abnormalities by light microscopy (400×). The rate of sperm head abnormalities was determined in each group.

### 2.6. Immunohistochemical preparation

For immunohistochemical localization of Bax, and PCNA fixed wax sections were stained using the avidin-biotin peroxidase method. Formalin-fixed paraffin-embedded tissue sections were deparaffinized, and endogenous peroxidase activity was blocked with H<sub>2</sub>O<sub>2</sub> in methanol and the sections were heated in 0.01 mol/L citrate buffer in a microwave pressure cooker for 20 min. The slides were allowed to cool to room temperature, and nonspecific binding was blocked with normal horse serum for 20 min at room temperature. The MIB-1 monoclonal antibody was used for detection of nuclear PCNA, a marker of proliferating cells (1:40, code No. M7187, Dako, Cambridge, UK). Anti-Bax (Dako) monoclonal antibodies were used for detection of Bax. Counterstaining was performed using Mayer's hematoxylin (Cat. No. 94585, BioGenex, Menarini Diagnostics, Antony, France). Assessment for Bax was performed according to the following semi-quantitative scale: (-), negative; (+), equivocally positive; (++) , weakly positive; (+++) , positive; and (++++), strongly positive[20]. For PCNA, the mean of number of positively stained cells were counted in 10 tubules of 5 animals of each group.

### 2.7. Assessment of oxidative stress and antioxidant enzyme

To assess the oxidative stress and antioxidant enzymes in the serum, blood samples were collected by the vena cava puncture of control and treated animals after 3 and 6 weeks of treatment. Sera was isolated by centrifugation and stored at -20 °C. MDA concentration was measured according to Ohkawa *et al.*[21].

Glutathione level was assessed according to Ellman[22] in view of the oxidation of GSH by 5,5'-dithiobis-2-nitrobenzoic corrosive (DTNB) to quantify the lessened GSH substance of biological specimens. GSH responds with DNTB to give a yellow hued ion 5-thiol-2-nitrobenzoic acid (TNB). Catalase was determined according to Goth's colorimetric method[23]. Sample was incubated in H<sub>2</sub>O<sub>2</sub> substrate and the enzymatic reaction stopped by the addition of ammonium molybdate. The complex formed by molybdate and H<sub>2</sub>O<sub>2</sub> has yellow color which can be measured at 405 nm.

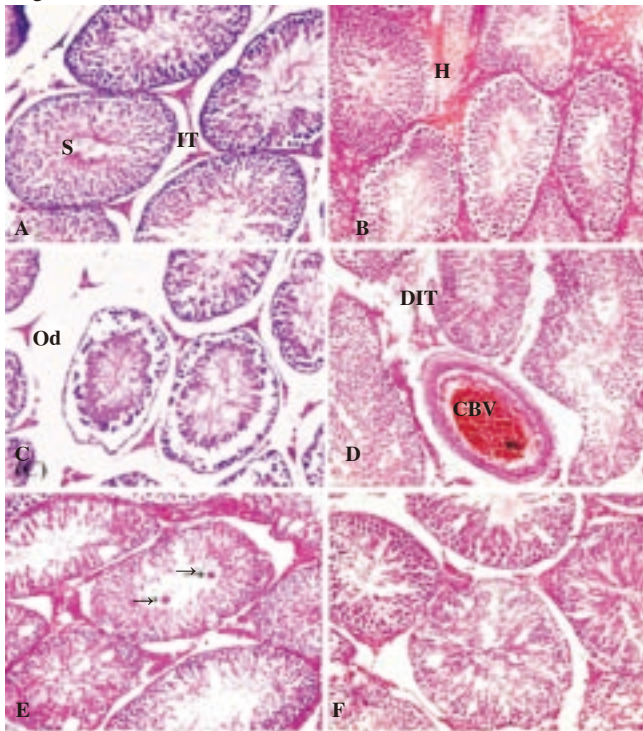
## 2.8. Statistical analysis

The results were expressed as mean  $\pm$  SD. The differences between the mean values were evaluated by ANOVA followed by Student's *t*-test using Minitab 12 computer program (Minitab Inc., State Collage, PA, USA).

## 3. Results

### 3.1. Histological results

Investigation of the testis of control animals demonstrated the average components of seminiferous tubules of control, spermatogenic cells, intertubular connective tissue and spermatozoa (Figure 1A).



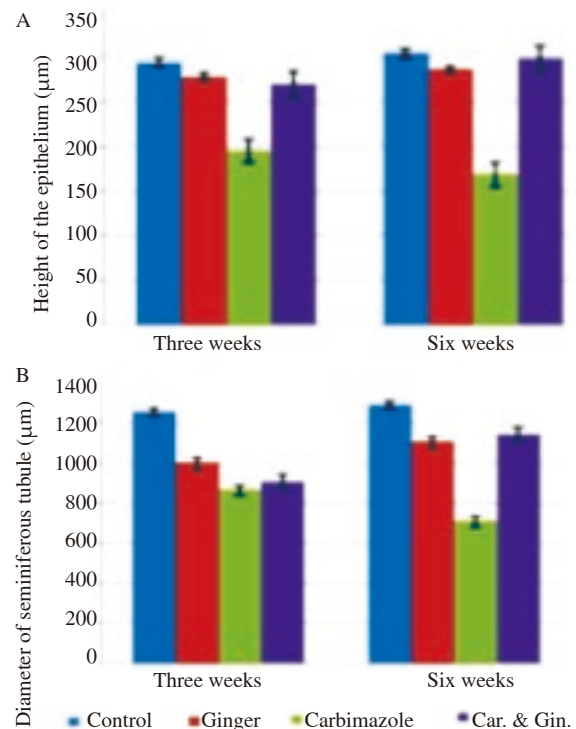
**Figure 1.** Histological results.

A: Section in testis of a control rat demonstrating ordinary seminiferous tubules. S: Sperms; IT: Interstitial tissue. B: Section in testis of a rat treated with carbimazole indicating intertubular hemorrhage (H) and lacking typical organization of spermatocytes and spermatogonia. C: Section in testis of a rat treated with carbimazole indicating degenerated germ cells and oedema (Od) and degenerated interstitial tissue. D: Section in testis of a rat treated with carbimazole demonstrating degenerated interstitial tissue (DIT) with congested blood vessel (CBV). E: Section in testis of a rat treated with carbimazole demonstrating multinucleated germ cells (arrows). F: Section in testis of a rat treated with carbimazole and ginger demonstrating a change in histological alterations induced by carbimazole, 400 $\times$ .

Animals getting ginger concentrate demonstrated ordinary histological appearance of the testis. Carbimazole treatment brought about an expansive number of seminiferous tubules lacking typical association of spermatocytes and spermatogonia with intertubular haemorrhage (Figure 1B). Moreover, numerous congested veins were showed with oedema in interstitial tissue (Figure 1C). The intertubular space got to be congested and had degenerative injuries of the interstitial Leydig cells (Figure 1D). Also, numerous different tubules had multinucleated germ cells with decrease of spermatogenic cells (Figure 1E). Seminiferous tubules degeneration with irregular boundaries was showed with exfoliated spermatogenic layer in the lumen of the tubules. Treated rats with carbimazole and ginger extract showed less prominent histopathological alterations in comparison with those of animals treated with carbimazole alone (Figure 1F).

### 3.2. Morphometric measurements

Rats treated with carbimazole for 3 and 6 weeks brought about decay of the seminiferous tubules. There was a significant decrease ( $P < 0.05$ ) in the diameter of the seminiferous tubules in rats treated with carbimazole compared to controls (Figure 2A). The height of germ cells of seminiferous tubules was diminished in contrasted with that of the control (Figure 2B). In compared with carbimazole treated rats, those treated with carbimazole and ginger demonstrated an alteration in the mean tubular diameter and germ cell height. In rats treated with ginger, the diameter and height of seminiferous tubules were normal.



**Figure 2.** Mean diameter of seminiferous tubules (A) and germ epithelial height (B) of testes of different groups.

### 3.3. Sperm head abnormalities

Sperm consists of head and tail. The head region is characterized by its basophilic affinity to haematoxylin stain and it is elongated



in shape. The base of the head is thick and the head tip has a hook-shape. The tail region is filament in shape and is much longer than the head region. The heads abnormality is represented by the following shapes: banana shape, without hook, amorphous in shape or hammer shape. Figure 3 shows that there is no significant alterations in average percentage of head abnormalities in control and ginger groups. The group treated with carbimazole showed significant ( $P < 0.05$ ) increase in sperm abnormalities after 3 weeks and 6 weeks. Combined treatment with both ginger and carbimazole significantly decreased the sperm heads abnormality in comparison with group treated with carbimazole alone.

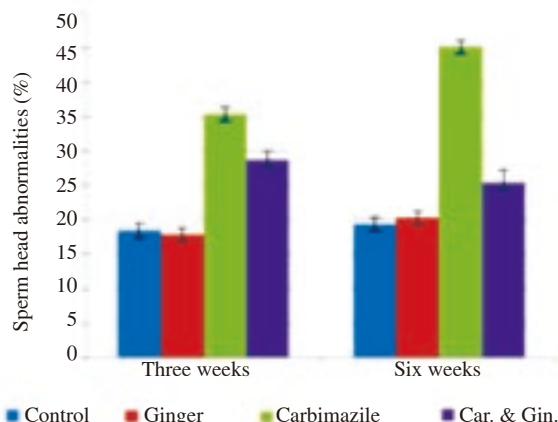


Figure 3. Percentage of sperm head abnormalities in different groups.

### 3.4. Immunohistochemical results

Table 1 demonstrates the expression of Bax in the testes of the different experimental groups. Testicular tissue obtained from control and ginger treated rats indicated frail articulation of Bax (Figure 4A), while treatment with carbimazole demonstrated expansion in articulation of Bax with the time (Figure 4B).

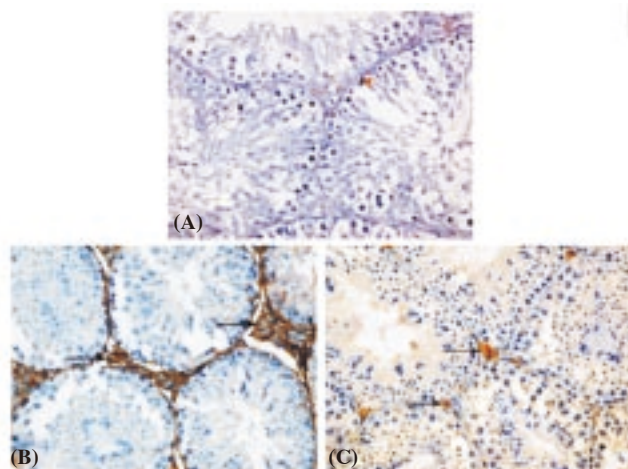


Figure 4. (A) Section in testis of a control group indicating weak expression of Bax in Leydig cells. (B) Section in testis of an animal treated with carbimazole demonstrating great expression of Bax expression. (C) Section in testis of an animal treated with carbimazole and ginger demonstrating decrease of Bax expression (A, 400×; B and C, 200×) following six weeks of treatment.

Treatment of rats with carbimazole and ginger concentrate diminished the outflow of Bax (Figure 4C). Stamped articulation of PCNA was recorded in the testes of control and ginger treated

rats (Figure 5A). Diminished articulation of PCNA was seen in rats treated with carbimazole (Figure 5B) while PCNA expression expanded in rats treated with carbimazole and ginger concentrate (Figure 5C). Figure 6 demonstrated the normal number of spermatogonial cells with positive PCNA in different groups.

Table 1

Bax expression in testes of animals in different groups.

Treatment group	Bax
Control	+
Ginger	+
Carbimazole 3 weeks	+++
Ginger + Carbimazole 3 weeks	+
Carbimazole 6weeks	++++
Ginger + Carbimazole 6 weeks	++

+: Equivocally positive; ++: Weakly positive; +++: Positive; ++++: Strongly positive.

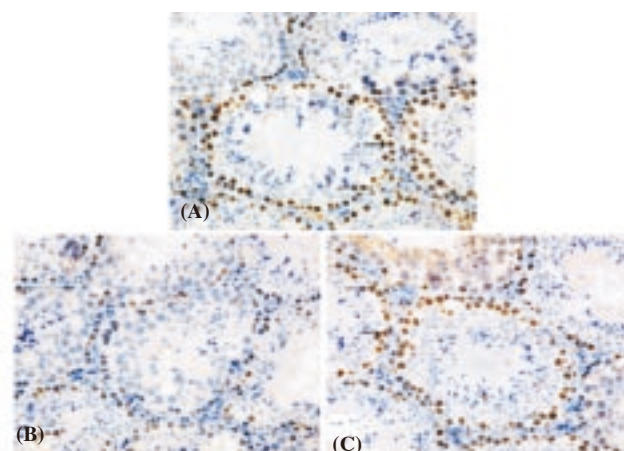


Figure 5. (A) Section in testis of a control rat demonstrating marked expression of PCNA. (B) Section in testis of a rat treated with carbimazole indicating reduction of PCNA expression. (C) An increase in PCNA expression after treatment with carbimazole and ginger (A-C, 200×).

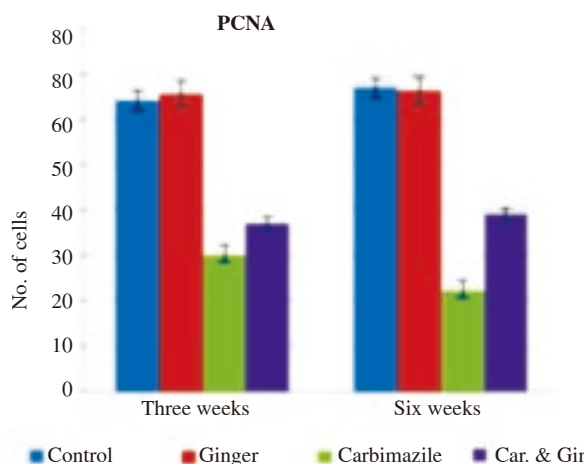
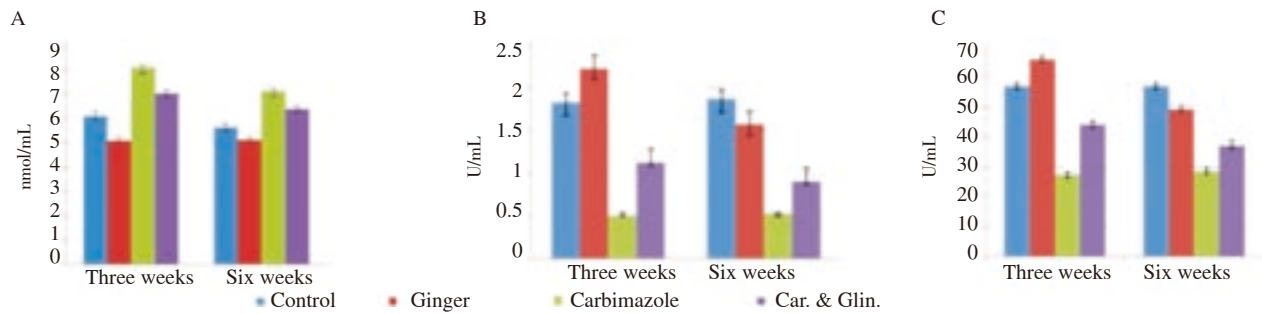


Figure 6. The number of positively stained spermatogonia with PCNA in testes of animals in different animal groups.

### 3.5. Assessment of oxidative stress and antioxidant enzymes

Data in Figure 7A shows that there was a marked elevation ( $P < 0.05$ ) in MDA level in the testes carbimazole group in comparison with the control. Animals treated with carbimazole and ginger



**Figure 7.** The effect of different treatments on MDA (A), glutathione (B) and catalase (C).

demonstrated a decline in the level of MDA. No changes were reported amongst control and ginger treated animals. Animals treated with carbimazole indicated significant ( $P < 0.05$ ) decrease in the activity of GSH and CAT when compared with control group. The of GSH and CAT activities were increased significantly in carbimazole and ginger group when compared with the carbimazole group. There is no significant change in GSH or CAT activities in rats treated with ginger alone (Figure 7B and C).

#### 4. Discussion

The antithyroid thioamide drug, carbimazole remains one of the mainstays of treatment for Graves' disease worldwide and can also be used for the treatment of other causes of hyperthyroidism, such as toxic nodular goiter. Carbimazole interferes with the production of thyroid hormones and is the thyroid peroxidase enzyme that is deactivated by methimazole (the active form of carbimazole), but it is associated with various adverse effects[24]. The present study showed that animals treated with carbimazole showed degeneration in seminiferous tubules with disorganization of germinal cells, decrease in epithelial height and diameter of seminiferous tubules. Regarding to the interstitium, there were congestion of the interstitial blood vessels and edema. Moreover, sperm head abnormalities were increased. These results were in agreement with Sakr *et al.*[6]. They revealed that exposing rats to carbimazole caused different histological changes included blood vessels congestion, hemorrhage, damage of interstitium and the spermatogenic cells showed apoptosis and necrosis. Maran *et al.*[25] recorded reduction of testes weight, decrease of leydig cell number and diameter, and reduction of peritubular myoid cell number after administration of methimazole to immature rats. Okdah[26] reported that methimazole caused significant decrease in diameter of seminiferous tubules and inhibition of spermatogenesis in rats. They found that the number of macrophages significantly increased in the testicular interstitium. Administration of methimazole for pregnant and lactating animals decreased testes weight and the number of leydig cells in neonatal Wistar rats. Also, it impaired the development and function of the testes[27]. Palmero *et al.*[28] reported that rats orally treated with methimazole characterized by an extreme reduction of body and testis.

Immunohistological studies revealed an increased expression of the proapoptotic protein, Bax in leydig cells in rats given carbimazole and a down-expression of PCNA in spermatogonia. Similarly, Huang

*et al.*[29] reported that administration of propylthiouracil to rats caused significant increase in expression of Bax in the hippocampus neurons of hypothyroid pups than that of control pups at all stages of development. The ratio of Bcl-2/Bax in hippocampus neurons of hypothyroid pups was lower than that of age-matched controls. Treating rats with propylthiouracil caused 25% reduction in PCNA staining in spermatogonia; however, in the control group more than 96% of spermatogonia were PCNA-positive cells[30]. A significant decrease in PCNA staining was found in psoriatic epidermis patients after treatment of with propylthiouracil and methimazole[31]. These results suggest that these drugs have an antiproliferative effect[32].

This work showed increased level in lipid peroxidation with a decreased enzymatic antioxidant status, glutathione and catalase, which were recorded in sera of rats treated with carbimazole. These results revealed that carbimazole induced oxidative stress which is in agreement with that obtained by some investigations. Testes homogenate of rats treated with carbimazole revealed a high lipid peroxidation with a decrease in the antioxidant enzymes SOD and CAT[6]. Heidari *et al.*[33] reported that a high reduction of oxidized glutathione (GSSG) was formed after treating with methimazole. N-methylthiourea toxicity was joined by a reduction in cellular GSH content. Joanta *et al.*[7] concluded that increased level of lipid peroxides were in both thyroid gland and serum, in animals treated with carbimazole. CAT and SOD activities in the thyroid gland decreased after carbimazole administration. Sakr *et al.*[34] found that carbimazole caused an increase in malondialdehyde concentration and decrease in the activity of CAT and SOD in the liver of rats.

Large number of plants and their extracts are now used in medicine and treatment of various diseases due to its antioxidant properties. In this work ginger aqueous extract was found to ameliorate the toxic testicular effect of carbimazole. This finding is in agreement with Aghaie *et al.*[35] as they observed that treatment with dual extract of pumpkin seed and *Z. officinale* improved sperm number and structure. Additionally, an improvement in epididymal epithelium and fibromuscular thickness was found in extract-treated rats when compared with control or cyclophosphamide groups. Sakr and Al-Amoudi[36] demonstrated that animals treated with deltamethrin and ginger showed an amelioration in the testicular alterations caused by deltamethrin. Sakr and Badawy[16] reported that *Z. officinale* has an ameliorative effect against testicular damage induced by metiram. Moreover, ginger aqueous extract was found to improve the histological and histochemical alterations induced by metalaxyl fungicide[37]. Bordbar *et al.*[38] showed that *Z. officinale* lowered

the testicular effect of busulfan in rats.

Ginger treatment caused a down-expression of Bax and an increase in the number of PCNA positive staining spermatogenic cells in testes, suggesting ginger extract is antiapoptotic and proliferative agent. Sakr and Al-Amoudi[36] demonstrated that expression of Bax was increased in Leydig cells and expression of p53 was increased in spermatocytes of testes of rats treated with deltamethrin. While treatment with ginger prompts a decrease in p53 and Bax expression. Ginger clearly restored the structural degenerative changes induced by acetic acid with overexpression of PCNA and reduction of isoform nitric oxide synthase (iNOS)[39]. Cadmium administration was found to increase the expression of the apoptotic caspase3 and decrease the expression of anti-apoptotic Bcl2 in liver and kidney. On the other hand, ginger counteracted the effects of Cd and down-regulated caspase3 and up-regulated Bcl2[40]. Zahedi *et al.*[15] investigated the effects of ginger on the apoptosis in testis in animals treated with gentamicin. The results revealed that apoptosis rate increased significantly in rats treated with gentamicin when compared with other groups. However, ginger could decrease apoptosis in rats treated with gentamicin and ginger.

Gingers decrease oxidative stress by decreasing the level of lipid peroxidation marker, malondialdehyde and increasing the activity of antioxidant enzymes (catalase and glutathione). These results are in agreement with Mukherjee *et al.*[16] as they showed an ameliorative effect of ginger extract against oxidative stress induced by phosphamidon. Aghaie *et al.*[35] reported that administration of dual treatment of pumpkin seed and *Z. officinale* extracts could increase the total antioxidant capacity level in cyclophosphamide-treated rats administration of coffee and ginger that demonstrated the capacity to scavenge free radicals and to restrain lipoygenase activity[41]. Rasyidah *et al.*[42] reported that rats treated with formalin and ethanolic ginger extract markedly elevated the CAT activity in compared with formalin group. Treatment with ginger showed a reduction in oxidative stress and increase of reduced glutathione (GSH) levels induced by chromate[43]. Superoxide dismutase, ascorbic acid, glutathione and uric acid levels were reduced and xanthine oxidase, glutathione-s-transferase activities were increased in alcohol treated rats while these parameters came to normalcy in ethanolic extract of ginger treated rats demonstrating the antioxidant effect of ginger[44]. Siddaraju and Dharmesh[45] demonstrated that ginger-free phenolic and ginger hydrolysed phenolic divisions showed free radical scavenging, inhibition of lipid peroxidation, protection of DNA and diminishing power abilities indicating strong antioxidant properties. Ghasemzadeh *et al.*[46] reported that young rhizome of *Z. officinale* had higher content of flavonoids with high antioxidant activity. It is concluded from the present study that treating rats with carbimazole induced significant alterations in the testicular tissue of rats. Moreover, a decrease in cell proliferation was reflected by the decrease in expression of PCNA, whereas the increase in apoptotic rate was revealed by overexpression of Bax. Oxidative stress was demonstrated by an increase in the level of malondialdehyde and decrease in activity of antioxidant enzymes (catalase and glutathione). Concomitant treatment with

aqueous ginger extract led to an improvement in histological, morphometrical, immunohistochemical changes and oxidative stress induced by carbimazole. The ameliorative effects of ginger extract could be attributed to antioxidant properties of its components.

### Conflict of interest statement

We declare that we have no conflict of interest.

### Acknowledgments

The authors are appreciative to Faculty of Science, Menoufia University, Shebin El-kom, Egypt for giving research facilities and instrument to do this work.

### References

- [1] Choi J, Jee JG. Repositioning of thiourea-containing drugs as tyrosinase inhibitors. *Int J Mol Sci* 2015; **16**: 28534-48.
- [2] Vilchez FJ, Torres I, Garcia-Valero A, López-Tinoco C, de Los Santos A, Aguilar-Diosdado M. Concomitant agranulocytosis and hepatotoxicity after treatment with carbimazole. *Ann Pharmacother* 2006; **40**(11): 2059-63.
- [3] Mikhail NE. Methimazole induced cholestatic jaundice. *South Med J* 2004; **97**: 178-82.
- [4] Ali BH, Bashir AA, Tanira MO. The effect of thyroxine or carbimazole treatment on gentamicin nephrotoxicity in rats. *Hum Exp Toxicol* 1995; **14**(1): 13-7.
- [5] Calañas-Continente A, Espinosa M, Manzano-García G, Santamaría R, Lopez-Rubio F, Aljama P. Necrotizing glomerulonephritis and pulmonary hemorrhage associated with carbimazole therapy. *Thyroid* 2005; **15**(3): 286-8.
- [6] Sakr SA, Mahran HA, Nofal AE. Effect of selenium on carbimazole-induced testicular damage and oxidative stress in albino rats. *J Trace Elem Med Biol* 2011; **25**(1): 59-66.
- [7] Joanta AE, Clichici S, Filip A, Daicovicu D. Lodide excess induces oxidative stress in blood and in thyroid gland. University of Bristol. *J Physiol* 2005; 567P, PC52. [Online] Available from: <http://www.physoc.org/proceedings/abstract/J%20Physiol%20567PPC52> [Accessed on 17th February, 2017]
- [8] Grzanna R, Lindmark L, Frondoza C. Ginger-A herbal medicinal product with broad anti-inflammatory actions. *J Med Food* 2005; **8**(2): 125-32.
- [9] Sharma JN, Srivastava KC, Gan EK. Suppressive effects of eugenol and ginger oil on arthritic rats. *Pharmacology* 1994; **49**(5): 314-8.
- [10] Kamtchoving P, Mbongue Fndio G, Dimo T, Jatsa H. Evaluation of androgenic activity of *Zingiber officinale* and *Pentadiplandra brazzeana* in male rats. *Asian J Androl* 2002; **4**: 299-301.
- [11] Marx W, McKavanagh D, McCarthy AL, Bird R, Ried K, Chan A, et al. Correction: the effect of ginger (*Zingiber officinale*) on platelet aggregation: a systematic literature review. *PLoS One* 2015; **10**(11): e0143675.
- [12] Wang CZ, Qi LW, Yuan CS. Cancer chemoprevention effects of ginger

- and its active constituents: potential for new drug discovery. *Am J Chin Med* 2015; **43**(7): 1351-63.
- [13] Ullah I, Subhan F, Ayaz M, Shah R, Ali G, Haq IU, et al. Anti-emetic mechanisms of *Zingiber officinale* against cisplatin induced emesis in the pigeon; behavioral and neurochemical correlates. *BMC Complement Altern Med* 2015; **15**: 34-42.
- [14] Ahmed R, Sharma S. Biochemical studies on combined effect of garlic (*Allium sativum* Linn) and ginger (*Zingiber officinale* Rosc) in albino rats. *Indian J Exp Biol* 1997; **35**: 841-3.
- [15] Zahedi A, Fathiazad F, Khaki A, Ahmadnejad B. Protective effect of ginger on gentamicin-induced apoptosis in testis of rats. *Adv Pharm Bull* 2012; **2**(2): 197-200.
- [16] Mukherjee S, Mukherjee N, Saini P, Roy P, Babu SP. Ginger extract ameliorates phosphamidon induced hepatotoxicity. *Indian J Exp Biol* 2015; **53**(9): 574-84.
- [17] Sakr SA, Badawy GM. Effect of ginger (*Zingiber officinale* R.) on metiram-inhibited spermatogenesis and induced apoptosis in albino mice. *J Appl Pharm Sci* 2011; **1**(4): 131-6.
- [18] Li Y, Hong Y, Han Y, Wang Y, Xia L. Chemical characterization and antioxidant activities comparison in fresh, dried, stir-frying and carbonized ginger. *J Chromatogr B Analyt Technol Biomed Life Sci* 2016; **1011**: 223-32.
- [19] Sakr SA, Mahran HA, Nofal AE. Effect of selenium on carbimazole-induced histopathological and histochemical alterations in prostate of albino rats. *Am J Med Med Sci* 2012; **2**(1): 5-11.
- [20] Al-Azemi M, Omu FE, Kehinde EO, Anim JT, Oriowo MA, Omu AE. Lithium protects against toxic effects of cadmium in the rat testes. *J Assist Reprod Genet* 2010; **27**: 469-76.
- [21] Ohkawa H, Ohishi N, Yagi K. Assay for lipid peroxidation in animal tissues by thiobarbituric acid reaction. *Anal Biochem* 1979; **95**: 351.
- [22] Ellman GL. Tissue sulphhydryl groups. *Arch Biochem Biophys* 1959; **82**: 70-7.
- [23] Góth L.A simple method for determination of serum catalase activity and revision of reference range. *Clin Chim Acta* 1991; **196**(2-3): 143-51.
- [24] Kota SK, Meher LK, Kota SK, Jammula S, Modi KD. Carbimazole-induced cholestatic hepatitis in Graves' disease. *Indian J Endocrinol Metab* 2013; **17**(2): 326-8.
- [25] Maran RR, Arunakaran J, Jeyaraj DA, Ravichandran K, Ravisankar B, Aruldhas MM. Transient neonatal hypothyroidism alters plasma and testicular sex steroid concentration in puberal rats. *Endocr Res* 2000; **26**(3): 411-29.
- [26] Okdah YA. Methimazole affected spermatogenesis and enhanced proliferation of testicular macrophages in albino rats. *World J Pharm* 2013; **1**(2): 55-60.
- [27] Cristovao FC, Bisi H, Mendon BB, Bianco AC, Bloise W. Severe and mild neonatal hypothyroidism mediate opposite effects on Leydig cells of rats. *Thyroid* 2002; **12**(1): 13-8.
- [28] Palmero S, de Marchis M, Gallo G, Fu E. Thyroid hormone affects the development of Sertoli cell function in the rat. *J Endocrinol* 1989; **123**(1): 105-11.
- [29] Huang XW, Zhao ZY, Ji C. Effects of hypothyroidism on apoptosis and the expression of Bcl-2 and Bax gene in the neonatal rat hippocampus neurons. *Chin J Pediatr* 2005; **43**(1): 48-52.
- [30] Tousson E, Ali EMM. Proliferating cell nuclear antigen as a molecular biomarker for spermatogenesis in PTU-induced hypothyroidism of rats. *Reprod Sci* 2011; **18**(7): 679-86.
- [31] Elias AN, Barr RJ, Rohan MK, Dangaran K. Effect of orally administered antithyroid thioureylenes on pcna and p53 expression in psoriatic lesions. *Int J Dermatol* 1995; **34**(4): 280-3.
- [32] Elias AN, Barr RJ, Nanda VS. p16 Expression in psoriatic lesions following therapy with propylthiouracil, an antithyroid thioureylene. *Int J Dermatol* 2004; **43**(12): 889-92.
- [33] Heidari R, Babaei H, Eghbal MA. Ameliorative effects of taurine against methimazole-induced cytotoxicity in isolated rat hepatocytes. *Sci Pharm* 2012; **80**(4): 987-99.
- [34] Sakr SA, Abdel-Ghafar FR, Abo-El-Yazid SM. Selenium ameliorates carbimazole induced hepatotoxicity and oxidative stress in albino rats. *J Coast Life Med* 2015; **3**(2): 139-45.
- [35] Aghaie S, Nikzad H, Mahabadi JA, Taghizadeh M, Azami-Tameh A, Taherian A, et al. Protective effect of combined pumpkin seed and ginger extracts on sperm characteristics, biochemical parameters and epididymal histology in adult male rats treated with cyclophosphamide. *Anat Sci Int* 2016; **91**(4): 382-90.
- [36] Sakr SA, Al-Amoudi WM. Effect of ginger extract on deltamethrin induced histomorphological and immunohistochemical changes in testes of albino rats. *Life Sci J* 2012; **9**(1): 771-8.
- [37] Sakr SA, Shalaby SY. Ginger extract protects metalaxyl-induced histomorphological and histochemical alterations in testes of albino mice. *J Appl Pharm Sci* 2011; **1**(10): 36-42.
- [38] Bordbar H, Esmaeilpour T, Dehghani F, Panjehshahin MR. Stereological study of the effect of ginger's alcoholic extract on the testis in busulfan-induced infertility in rats. *Iran J Reprod Med* 2013; **11**(6): 467-72.
- [39] El-Galil TIA, ElGhamrawy TA, El Sadik AO. The effect of n-acetylcysteine and ginger on acetic acid induced colitis in adult male albino rat: histological, immunohistochemical and morphometric study. *J Cytol Histol* 2015; **S3**: 021.
- [40] Baiomy AA, Mansour AA. Genetic and histopathological responses to cadmium toxicity in rabbit's kidney and liver: protection by ginger (*Zingiber officinale*). *Biol Trace Elem Res* 2016; **170**(2): 320-9.
- [41] Durak A, Gawlik-Dziki U, Kowlska I. Coffee with ginger - interactions of biologically active phytochemicals in the model system. *Food Chem* 2015; **166**: 261-9.
- [42] Rasyidah TI, Suhana S, H.Nur-Hidayah, Kaswandi MA, Noah RM. Evaluation of antioxidant activity of *Zingiber officinale* (ginger) on formalin-induced testicular toxicity in rats. *J Med Bioeng* 2014; **3**(3): 149-53.
- [43] Krim M, Messaadia A, Maida I, Aouacheri O, Saka S. Protective effect of ginger against toxicity induced by chromate in rats. *Ann Biol Clin (Paris)* 2013; **71**(2): 165-73.
- [44] Shanmugam KR, Ramakrishna CH, Mallikarjuna K, Reddy KS. Protective effect of ginger against alcohol-induced renal damage and antioxidant enzymes in male albino rats. *Indian J Exp Biol* 2010; **48**(2): 143-9.
- [45] Siddaraju MN, Dharmesh SM. Inhibition of gastric H<sup>+</sup>, K<sup>+</sup>-ATPase and *Helicobacter pylori* growth by phenolic antioxidants of *Zingiber officinale*. *Mol Nutr Food Res* 2007; **51**(3): 324-32.
- [46] Ghasemzadeh A, Jaafar HZE, Rahmat A. Antioxidant activities, total phenolics and flavonoids content in two varieties of Malaysia young ginger (*Zingiber officinale* Roscoe). *Molecules* 2010; **15**(6): 4324-43.