

Study on the incidence of ossified pterygospinous ligament with its clinical importance in associated neuralgias

K Ephraim Vikram Rao^{1,*}, BH Shiny Vinila²

¹Associate Professor, Dept. of Anatomy, Deccan College of Medical Sciences, Hyderabad, Telangana, ²Senior Lecturer, Dept. of Anatomy, Panineeya Mahavidyalaya Institute of Dental Sciences & Research Center, Hyderabad, Telangana

***Corresponding Author:**

Email: drvikram.anat@gmail.com

Abstract

Introduction: Close relation of ossified pterygospinous ligament to the foramen ovale can entrap the mandibular nerve and its branches and cause mandibular neuralgia. The present study aims to find the incidence of the ossified pterygospinous ligament.

Materials and Method: A total of 50 skulls were collected from the department of anatomy and 100 sides of 50 skulls were observed to find out the incidence of the pterygospinous bridges.

Results: Ossified pterygospinous ligament was observed in 14 sides of the skulls (14%). Ossification of the pterygospinous ligament was complete on 5 sides (5%). In 9 sides (9%), the pterygospinous bridge was incomplete.

Conclusion: Knowledge of the ossification of pterygospinous ligaments can improve understanding of complex clinical neuralgias associated with this region which will be helpful for anesthesiologists and surgeons while dealing with this region.

Keywords: Pterygospinous ligament, Pterygospinous bridge, Ossification, Neuralgia, Foramen of civinini

Received: 23rd March, 2017

Accepted: 10th July, 2017

Introduction

Sphenoid bone lies at the base of skull and has a central body, paired greater and lesser wings spreading laterally from it, and two pterygoid processes. Each pterygoid process descends perpendicularly from the junctions of greater wings and body of sphenoid and consists of medial and lateral plates. The medial pterygoid plate is narrower and longer while the lateral pterygoid plate is broad, thin, and everted. The pterygospinous ligament extends from the lateral plate of pterygoid process of sphenoid bone to the spine of sphenoid.⁽¹⁾ Civinini in 1835 described that the ossification of pterygospinous ligament leads to formation of pterygospinous foramen or Civinini foramen.⁽²⁾

Complete ossification of pterygospinous ligament may lead to alteration in the course of the mandibular nerve and cause the trunk of the mandibular nerve to redirect laterally and its branches, especially the lingual nerve and the inferior alveolar nerve which have to cross the extended lateral pterygoid plate. Because of this abnormal course, there is greater risk for neuralgia occurring due to the nerves becoming entrapped or compressed between the osseous structures and muscles.⁽³⁾ The presence of these ossified formations at the lateral surface of the lateral pterygoid plate may impede access to the foramen ovale during induction of anaesthesia of the trigeminal nerve.⁽⁴⁾ There may be failure of anaesthesia in cases of treatment of trigeminal neuralgia. It can also constitute an obstacle for mandibular nerve block which is a preferred method for pain relief in fractures of mandible or cancer patients.⁽⁵⁾

The present study was carried out to find out the incidence of ossification of the pterygospinous ligament and its morphology, which will be helpful for surgeons, anesthesiologists, anatomists and anthropologists while dealing with the infratemporal region.

Materials and Method

The present study was carried out on 100 sides of 50 Indian adult dry skulls of unspecified sex and age, obtained from the Department of Anatomy, Deccan College of Medical Sciences, Hyderabad. Damaged skulls and skulls with pathological conditions were excluded from the study. The bases of the skulls were examined to note the presence of pterygospinous bridges. The incidences based on the sides were noted. The gross appearance of pterygospinous bridges and their relations to foramen ovale were observed and photographs were taken. Classification was made, according to the degree of ossification of ligaments between the bones, as incomplete and complete. If bony bridges were extending from lateral pterygoid plate to apex of spine of the sphenoid bone, it was termed complete, and if ossification of pterygospinous ligament failed to make contact with the sphenoid spine, it was considered as incomplete. In complete pterygospinous bar, a well-formed pterygospinous foramen was present (Foramen of Civinini) while, in case of incomplete bar, a partial foramen was present.

Results

Out of 50 skulls studied 9 (18%) skulls were bearing ossified pterygospinous ligaments (Fig. 1). Among 100 sides, ossified pterygospinous ligament was observed in

14 (14%), in which complete pterygospinous bridge was present in 5(5%) and incomplete bridge was seen in 9 (9) sides.

Bilateral complete ossified pterygospinous bridge was observed in 2 (4%) skulls (Fig. 2). In 1 (2%) skull a unilateral complete pterygospinous bridge was observed on the right side and incomplete pterygospinous bridge was observed on the left side(Fig. 3). Bilateral incomplete bridge was observed in 3 (6%) skulls (Fig. 4) and unilateral incomplete pterygospinous bridges were observed in 2 skulls one on right side and another on left side.

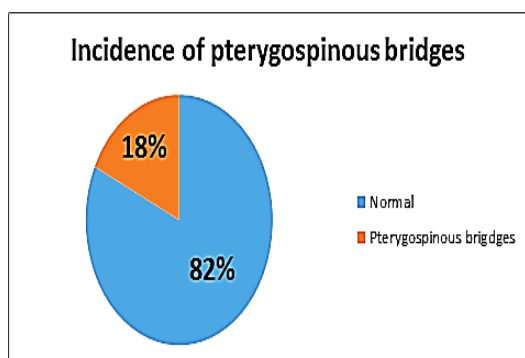


Fig. 1: Showing the incidence of pterygospinous bridges



Fig. 2: Bilateral complete pterygospinous bridge

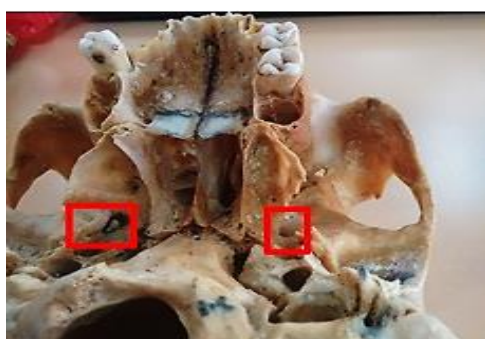


Fig. 3: Unilateral complete (right) and incomplete (left) pterygospinous bridges

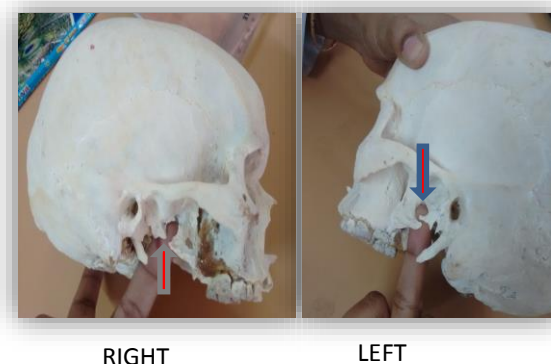


Fig. 4: Bilateral incomplete pterygospinous bridges

Discussion

The pterygospinous ligament is a thickening of fascia between the lateral and medial pterygoid muscles extending from the spine of sphenoid to the upper part of the posterior border of the lateral pterygoid plate. The pterygospinous ligament is occasionally replaced by muscular formations such as the pterygospinous muscle, which is inserted into the temporomandibular joint capsule extending to the articular disc. Sometimes the pterygospinous ligament may get ossified completely or incompletely.⁽⁶⁾

A wide pterygospinous bridge has been reported in the skulls of herbivores, rodents, carnivores and primates. A small pterygospinous bridge is seen in rodents but not seen in primates. Therefore the presence of pterygospinous bridge in humans is considered to be a phylogenetic remnant.⁽⁷⁻¹⁰⁾

The incidence of pterygospinous ligament ossification in the present study was 14% which was higher than the other Indian studies by Nayak et al., Shinde et al., which were 9.61% and 3.07% respectively. Another Indian study by Kamath et al., reported the incidence as 17% which was nearer to the results of present study.^(7,11,12) The incidence of ossified pterygospinous ligament has been reported by different authors with different ethnicity (Table 1).

Table 1: Comparison of the present study with other studies

Authors	Year	Ethnicity	Total incidence	Incomplete pterygospinous bridge	Complete pterygospinous bridge
Kapur et al ⁽⁴⁾	2000	Croat	18.36%	14.7%	3.6%
Peker et al ⁽¹⁵⁾	2001	Anatolian	5.5%	-	5.5%
Ludinghausen et al ⁽³⁾	2006	German	6%	-	6%
Antonopoulou et al ⁽¹⁶⁾	2008	Greek	14%	12%	2%
Agarwal et al ⁽¹⁷⁾	2012	Punjab Indian	9.72%	6.72%	2.98%
Yadav et al ⁽¹⁴⁾	2013	North Indian	10.2%	6.2%	4%
Present study	2017	South Indian	14%	9%	5%

Conclusion

The anatomical knowledge of the ossification of pterygospinous ligaments is essential for anaesthetists, radiologists, dentists and neurosurgeons to enhance the success of diagnostic evaluation and surgical approaches to the cranial base and other related procedures. The results of the present study show that the incidence of pterygospinous bars in South Indian population is higher than those in other ethnic groups which should be considered while dealing with cranial base procedures and surgeries involving this region.

References

1. Standring S, Borley NR, Collins P, Crossman AR, Gatzoulis MA, Healy JC, Johnson D, Mahadevan V, Newell RL, Wigley K. Gray's anatomy: the anatomical basis of clinical practice. 40th ed. London: Churchill Livingstone; 2008: 415.
2. Tebo HG, The pterygospinous bar in panoramic roentgenography, Oral Surgery, Oral Medicine, Oral Pathology. 1968; 26(5): 654–657.
3. Ludinghausen M, Kageyama I, Miura M, and Aikhatib M, Morphological peculiarities of the deep infratemporal fossa in advanced age. Surgical and Radiologic Anatomy. 2006; 28(3): 284–292.
4. Kapur E, Dilberović F, Redzepagić S, Berhamović E. Variation in the lateral plate of the pterygoid process and the lateral subzygomatic approach to the mandibular nerve. Med Arh. 2000; 54: 133-7.
5. Atamaz-Pinar Y, Arsu G, Aktan-Ekiz A, and Bilge O, Pterygospinous and pterygoalar bridges. Sendrom. 2004; 16(7): 66–69.
6. Peuker ET, Fischer G, and Filler TJ. Entrapment of the lingual nerve due to an ossified pterygospinous ligament. Clinical Anatomy. 2001; 14(4): 282–284.
7. Kamath K, Vasantha B. Anatomical Study of Pterygospinous and Pterygoalar Bar in Human Skulls with their Phylogeny and Clinical Significance. Journal of Clinical and Diagnostic Research. 2014; 8(9): AC10-AC13.
8. Piagkou M, Demesticha T, Piagkos G, Georgios A, Panagiotis S. Lingual nerve entrapment in muscular and osseous structures. Int J Oral Sci. 2010; 2: 181-89.
9. Devi JD, Mugunthan N, Anbalagan J, Sudha R, Shivadeep S. A study on ossified pterygospinous and pterygoalar ligaments in Indian skulls. Nat J Basic Med Sci. 2012; 3(2): 103-08.
10. Saran RS, Ananthi KS, Subramaniam A, Balaji MST, Vinaitha D, Vaithianathan G. Foramen of Civinini: A new anatomical guide for maxillofacial surgeons. J Clin Diagn Res. 2013; 7(7): 1271-75.
11. Nayak SR, Saralaya V, Prabhu LV, Pai MM, Vadgaonkar R, D'Costa S. Pterygospinous bar and foramina in Indian skulls: incidence and phylogenetic significance. Surg Rad Anat 2007; 29: 5–7.
12. Shinde V S, Mallikarjun M, and Patil R. A study on an ossified pterygospinous ligament. Journal of Clinical and Diagnostic Research. 2011; 5(5): 978–979.
13. S. Das and S. Paul, Ossified pterygospinous ligament and its clinical implications. Bratislavsk'e Lek'arske Listy. 2007; 108(3): 141–143.
14. Yadav A, Kumar V, Niranjan R. Pterygospinous Bar and Foramen in the Adult Human Skulls of North India: Its Incidence and Clinical Relevance. Anatomy Research International. 2014: 286794.
15. Peker T, Karaköse M, Anil A, Turgut HB, Gülekon N. The incidence of basal sphenoid bony bridges in dried crania and cadavers: their anthropological and clinical relevance. Eur J Morphol. 2002; 40: 171–180.
16. Antonopoulou M, Piagou M, Anagnostopoulou S. An anatomical study of the pterygospinous and pterygoalar bars and foramina: their clinical relevance. J Craniomaxillofac Surg. 2008; 36: 104–108.
17. Agarwal B, Gupta M, Kumar H. Ossified ligaments of the skull. Journal of the Anatomical Society of India. 2012; 61(1): 37–40.