

# “Comparison of three Different Endodontic Solvents in Regaining Apical Patency after Obturation with Gutta-Percha & Two Different Sealers.”

Dr. Harshraj Gawande<sup>1</sup>, Dr. Sharad Kokate<sup>2</sup>, Dr. Vibha Hegde<sup>3</sup>

PG Student<sup>1</sup>, Professor & Dean<sup>2</sup>, Professor & HOD<sup>3</sup>, Department of Conservative Dentistry and Endodontics YMT Dental College and Hospital, Kharghar, Navi Mumbai, Maharashtra, India<sup>1,2,3</sup>

## Access Online



### Introduction

During endodontic retreatment, complete removal of sealer is a challenge because there is risk of overzealous dentin removal associated with mechanical instrumentation<sup>1</sup>; hence chemical intervention remains the safest option. Chloroform is a common solvent used in endodontic retreatment<sup>2</sup> which is regarded as safe<sup>3</sup> along with eucalyptol, turpentine, and orange oil.<sup>4</sup> Now, because of the advent of resin sealers like AH Plus and MTA Fillapex, Endosolv R was introduced specifically for them. This study was designed to test if commonly used endodontic solvents have the ability to soften these resin based sealers to allow re-establishment of apical patency.

### Materials and Method

**Instrumentation and Obturation :** 90 extracted human mandibular premolars were selected for the study. Radiographs were taken to verify that each tooth had 1 canal and it was straight. The teeth were decoronated with a slow-speed diamond disc under water coolant. The canals were accessed, and the working length of each canal was determined by placing a #10 K-file so that the tip was visible at the apical foramen. Then, 1 mm was subtracted from the measured tooth length to gain the actual working length. A glide path of 20 (.02 taper size) was established, and the canals were instrumented using the crown down technique with ProTaper Universal rotary files (Dentsply Maillefer, Ballaigues, Switzerland) to a size of

### Abstract

**Introduction:** Organic solvents like Chloroform and Xylol are commonly used to facilitate removal by softening gutta-percha with sealer whereas Endosolv R is an endodontic solvent used to soften resin based sealers. Two commonly used sealers in Endodontics are MTA Fillapex (Mineral trioxide aggregate based) and AH-Plus.

**Aim:** To compare the ability of three commonly used endodontic solvents to soften gutta-percha and resin based sealers (two) to allow for the re-establishment of apical patency.

**Material and Methods:** Ninety extracted human mandibular premolar teeth were divided into two groups after instrumentation (n = 45) based on the sealer used; Group A was obturated with gutta-percha and AH Plus whereas MTA Fillapex was used in Group B. Both groups were divided into three subgroups (n = 15) based on the solvent used. Each subgroup was exposed to 1 of the following solvents: Chloroform, EndosolvE, EndosolvR.

**Results:** Patency was re-established in 100% of the teeth in Group B when tested with Chloroform or Endosolv R. Chloroform was 100% successful in establishing patency in both groups. The Chi-square and Fisher's exact test indicated a statistically significant difference between Endosolv E and the other tested solvents for Group B. Chloroform was found significantly better than Endosolv E in Group B and better than both Endosolv E and Endosolv R in Group A.

**Conclusion:** Chloroform and Endosolv R softened MTA Fillapex sufficiently to aid in re-establishing apical patency whereas Endosolv R considerably failed to establish patency through AH Plus during endodontic retreatment.

**Keywords:** AH Plus, Endosolv R, MTA Fillapex patency retreatment sealer solvent

25 (.08). After each file was used, the canal was irrigated with 3% NaOCl, and patency was reconfirmed. A 26.5-G side-vented needle was used with all irrigants to the working length. The final irrigation protocol for each canal was 3 ml 3% NaOCl followed by 3 ml 17% EDTA and a final irrigation of 3 ml 3% NaOCl to effectively remove the smear layer. The canals were dried with paper points, and patency was reconfirmed before obturation.

### Obturation

The instrumented teeth were divided into 2 groups (n = 45 for each group) i.e Group A and Group B based upon the sealer used for obturation. In Group A, AH Plus sealer (Dentsply, Konstanz, Germany) was introduced into the canal with a #25 Lentulo spiral to the working length until sealer was extruded from the apical foramen whereas MTA Fillapex sealer (Angelus Solucoes Odontologicas, Londrina PR, Brazil) was introduced in the canal in similar fashion in Group B [Figure 1]. In both groups, size 25 (.06) gutta-percha master cones were trimmed to fit 2 mm short of the working length, coated with sealer, and inserted into the canal to simulate a “short obturation” and allow for the evaluation of regaining patency mostly through sealer. The canals were obturated using Cold Lateral Condensation Obturation technique in both the groups [Figure 2]. A dense, 3-dimensional obturation was confirmed with digital radiographs taken from both a mesial-distal and a buccal-lingual view. A cotton pellet was placed over the obturation, and

the access was sealed with Type II GIC. The obturated samples were kept for 1 month before retreatment to ensure complete setting of the materials.

### Removal of the Obturation Material

After 4 weeks, the restoration and cotton pellet were removed from the samples. The coronal 3mm gutta-percha was removed using Gates Glidden drills so as to prepare a well for the solvent [Figure 3].

The 2 treatment groups were divided into the following 3 subgroups based upon the solvent to be tested: groups A1 and B1, chloroform (n = 15); groups A2 and B2, Endosolv E (Septodont, Saint-Maur, France) (n = 15); groups A3 and B3, Endosolv R (Septodont, Saint-Maur, France) (n = 15). In each subgroup, 2–3 drops of the test solvent were placed in the orifice adjacent to the remaining obturation material. An attempt was made to regain patency using a new #10 K-file. A #10 K-file was used because of its flexibility, which allowed for a better evaluation of the solvent's ability to soften the obturation material rather than the file's ability to penetrate the material. Patency was defined as visualization of the file from the anatomic apex [Figure 4]. If patency was unable to be re-established within 3 minutes after placing the solvent, the test was terminated and recorded as a failure. All sample preparations, treatments, and evaluations were performed by a single operator.

### Statistical Analysis

After data collection, data entry was done in Microsoft Excel and analyzed using the SPSS

software v20 (IBM Corp., Armonk, NY). To evaluate the differences between the abilities of the endodontic solvents to regain apical patency Fisher's exact test and Chi-square test were used. The Fisher exact test was used to determine significant differences between groups; the proportion of tests was successful (patency able to be regained) versus tests that were not successful. P values less than 0.05 were considered as significant.

**Results**

**Group A (AH-Plus)**

The number of samples in Group A in which the apical patency was re-established is given in Table 1. Chloroform was able to re-establish patency in all the specimens. The chi-square test and Fisher exact test indicated that there was a statistical difference between the Chloroform group and the other test groups ( $p < .005$ ) whereas there was no statistically significant difference between Endosolv E and Endosolv R group ( $p > 0.05$ ) [Table 3] [Graph 1].

**Group B (MTA Fillapex)**

Patency was re-established in all of the chloroform and Endosolv R samples [Table 2]. The chi-square test and Fisher exact test indicated that there was a statistical difference between the Endosolv E group and the other test groups ( $p < .05$ ) whereas no significant difference was seen between Endosolv R and Chloroform groups ( $p > .05$ ) [Table 4]. This showed the inefficiency of Endosolv E in removing the MTA Fillapex sealer [Graph 2].

Figure 1: Sealer packed in apical 2mm

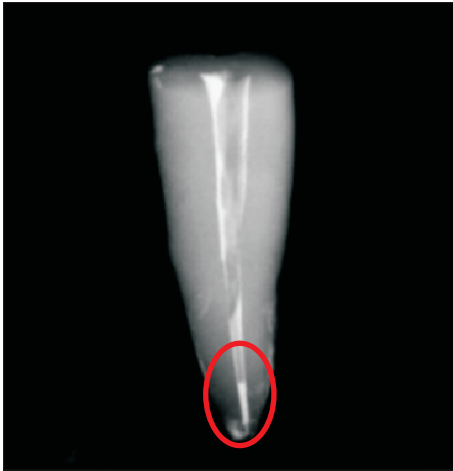

Figure 2: After complete Obturation

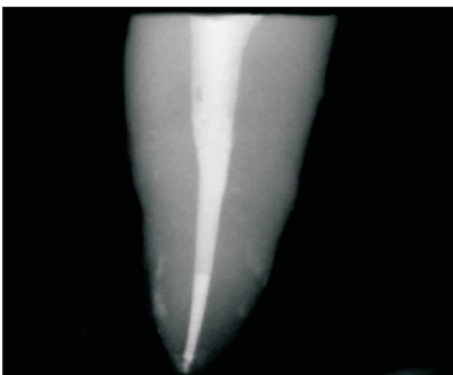


Figure 3: Removal of Coronal gutta-percha to make well for solvent placement

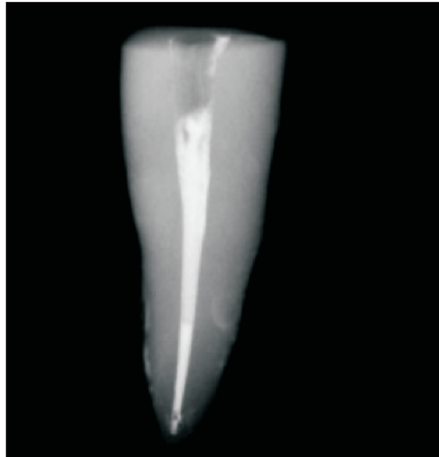


Figure 4: Re-establishment of Apical Patency

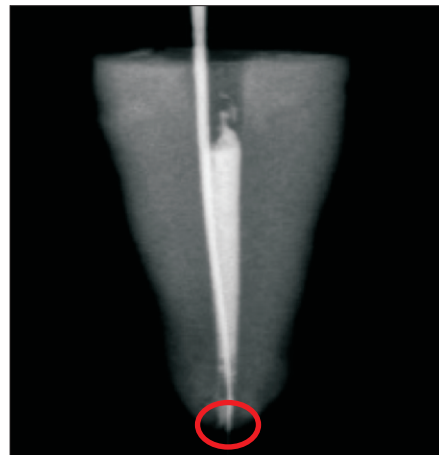
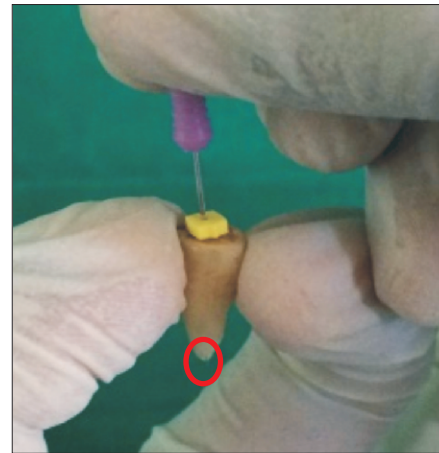

Table 1: Number of Specimens Filled with AH Plus and Gutta-percha showing establishment of apical patency

	Patency Established	
	Yes	No
Chloroform	15	0
Endosolv E	4	11
Endosolv R	8	7

Table 2: Number of Specimens Filled with MTA Fillapex and Gutta-percha showing establishment of apical patency.

	Patency Established	
	Yes	No
Chloroform	15	0
Endosolv E	7	8
Endosolv R	15	0

Table 3: Comparison between Endosolv E, Chloroform and Endosolv R for the establishment of apical patency in

	Patency Established		P-Value	
	Yes	No	Chi-Square	Fisher's
Endosolv E	4	11	0.0003	0.0005
Chloroform	15	0		
Endosolv R	8	7	0.003	0.006
Chloroform	15	0		
Endosolv E	4	11	0.136	0.254
Endosolv R	8	7		

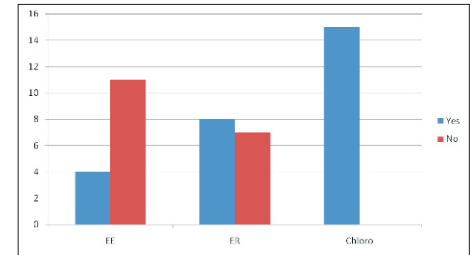
specimens obturated using AH Plus sealer

Table 4: Comparison between Endosolv E, Chloroform and Endosolv R for the establishment of apical patency in

	Patency Established		P-Value	
	Yes	No	Chi-Square	Fisher's
Endosolv E	7	8	0.001	0.002
Chloroform	15	0		
Endosolv R	15	0	NA	NA
Chloroform	15	0		
Endosolv E	7	8	0.001	0.002
Endosolv R	15	0		

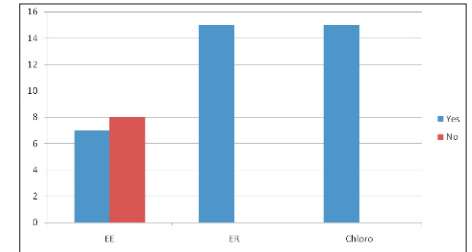
specimens obturated using MTA Fillapex sealer.

Graph 1: Graphical representation of comparison of the ability of the three solvents to re-establish the apical



patency in Group A (AH Plus).

Graph 2: Graphical representation of comparison of the ability of the three solvents to re-establish the apical patency in Group A (AH Plus) and Group B (MTA



Fillapex).

**Discussion**

Chloroform was the most effective and consistently softened all the sealers used in this study. Endosolv R consistently softened MTA Fillapex obturations in order to allow proper removal of the sealer and re-establish patency. Endosolv E was less effective in softening either of the used sealer, and Endosolv R failed to soften AH-Plus sealer sufficiently to allow for apical patency re-establishment.

In an effort to reduce the effect that gutta-percha would have on the ability to regain patency, master cones were seated 2 mm short

**Gawande, et al.: “Comparison of Three Different Endodontic Solvents in Regaining Apical Patency After Obturation With Gutta-Percha & Two Different Sealers.”**

of the working length. Also, #10 K-file was used to check patency because of its flexibility, which allowed for a better evaluation of the solvent's ability to soften the obturation material rather than the file's ability to penetrate the material.

Many studies have been carried out by different authors comparing the ability of different solvents to soften root canal filling materials such as gutta-percha and endodontic sealers.<sup>4,9</sup> Now, because eugenol based sealers were previously popular, Endosolv E was the solvent of choice which is recommended for the removal of gutta-percha and zinc oxide-eugenol filling materials from the root canal.<sup>10</sup> But after the advent of resin based sealers, Endosolv R which is formulated from formamide and phenyl-ethyl alcohol<sup>11</sup> achieved popularity as it is specifically designed to be used with resin-based materials. Because MTA Fillapex contains a resin matrix, perhaps this is the reason for the slight improvement in re-establishing patency. However, this does not hold true for AH-Plus group where Endosolv R was not that successful in re-establishing patency. This could be attributed to the reason that Endosolv R is meant to soften only phenolic type of resin<sup>10</sup> and MTA Fillapex being a salicylate based sealer<sup>12</sup> containing a phenolic ring was successfully

softened by this solvent. On the other hand, AH-Plus is an epoxide amine based sealer<sup>13</sup> and hence did not respond to Endosolv R solvent. Also, Endosolv E is a solvent used for softening Eugenol based sealers<sup>14</sup> and as both sealers used in this study were resin based, it failed to re-establish patency through both. This result indicates that the removal of AH-Plus may require additional methods. Chloroform and Endosolv R did allow for apical patency to be consistently re-established through MTA Fillapex sealer.

#### **Conclusion**

Chloroform and Endosolv R are commonly used endodontic solvents that successfully soften gutta-percha and MTA Fillapex sufficiently to allow for the re-establishment of patency. Endosolv R is found successful in sufficiently softening gutta-percha and MTA Fillapex to re-gain patency unlike AH-Plus sealer. Chloroform was found to be equally effective on both the sealers whereas on the other hand Endosolv E failed to re-establish patency through any.

#### **References**

- 1) Carpenter MT, Sidow SJ, Lindsey KW, Chuang A, McPherson JC. Regaining apical patency after obturation with gutta-percha and a sealer containing Mineral trioxide aggregate. *J Endod.* 2014;40:588-90.
- 2) Vranas RN, Hartwell GR, Moon PC. The effect of endodontic solutions on resorcinol formalin paste. *J Endod.* 2003;29:69-72.

- 3) McDonald MN, Vire DE. Chloroform in the endodontic operator. *J Endod.* 1992;18:301-3.
- 4) Tamse A, Unger U, Metzger Z, Rosenberg M. Gutta-percha solvents—a comparative study. *J Endod.* 1986;12:337-9.
- 5) Wilcox LR. Endodontic retreatment: ultrasonics and chloroform as the final step in reinstrumentation. *J Endod.* 1989;15:125-8.
- 6) Martos J, Gastal MT, Sommer L, Lund RG, Del Pino FA, Osinaga PW. Dissolving efficacy of organic solvents on root canal sealers. *Clin Oral Investig.* 2006;10:50-4.
- 7) Whitworth JM, Boursin EM. Dissolution of root canal sealer cements in volatile solvents. *IntEndod J.* 2000;33:19-24.
- 8) Kaplowitz GJ. Evaluation of gutta-percha solvents. *J Endod.* 1990;16:539-40.
- 9) Wilcox LR, Krell KV, Madison S, Rittman B. Endodontic retreatment: evaluation of gutta-percha and sealer removal and canal re-instrumentation. *J Endod.* 1987;13:453-7.
- 10) Gambrel MG, Hartwell GR, Moon PC, Cardon JW. The effect of endodontic solutions on resorcinol-formalin paste in teeth. *J Endod.* 2005;31:25-9.
- 11) Cohen AG. The efficiency of different solvents used in the retreatment of paste-filled root canals [master's thesis]. Boston: Boston University, 1986: 1-100.
- 12) Vitti RP, Prati C, Silva EJ, Sinhoreti MA, Zanchi CH, de Souza e Silva MG, et al. Physical properties of MTA Fillapex Sealer. *J Endod.* 2013;39:915-8.
- 13) Zmener O, Spielberg C, Lamberghini F, Rucci M. Sealing properties of a new epoxy resin-based root-canal sealer. *IntEndod J.* 1997;30:332-4.
- 14) Faria-Júnior NB, Loiola LE, Guerreiro-Tanomaru JM, Berbert FL, Tanomaru-Filho M. Effectiveness of three solvents and two associations of solvents on gutta-percha and resilon. *BrazDent J.* 2011;22:41-4.