



Document heading doi:10.1016/S2222-1808(12)60049-8

# Role of leukotrienes in NSAID induced gastric ulceration and inflammation in wistar rats

Maulik N Gandhi<sup>1</sup>, Siva Reddy Challa<sup>2\*</sup>, Pari Prasanth<sup>2</sup>, Tejal R Gandhi<sup>1</sup><sup>1</sup>Department of Pharmacology, Anand Pharmacy College, Anand, Gujarat, India<sup>2</sup>Department of Pharmacology, KVSRR Siddhartha College of Pharmaceutical Sciences, Vijayawada-520010

## ARTICLE INFO

*Article history:*

Received 25 March 2012

Received in revised form 5 April 2012

Accepted 27 May 2012

Available online 28 June 2012

*Keywords:*

Gastric ulcer

NSAID

Montelukast

Curcumin

Leukotrienes

Vascular permeability

## ABSTRACT

**Objective:** To evaluate the effects of Montelukast and Curcumin against indomethacin induced gastric damage in rats in order to assess the role of leukotriene (LTs) if any, in non steroidal anti-inflammatory drug (NSAID) induced gastroinflammation. **Methods:** The effects of Montelukast (10 mg/kg) and Curcumin (100 mg/kg) were observed on gastric lesion induced by Indomethacin. The blood samples were analyzed for neutrophil adhesion and lipid peroxide levels in gastric tissue measured spectrophotometrically. The skin vascular permeability study was performed by using compound 48/80 induced vascular permeability model. **Results:** Montelukast and Curcumin significantly reduced Indomethacin induced gastric lesion score. Pretreatment with Montelukast and Curcumin significantly counteracted Indomethacin induced gastropathy by a combination of its effect on inhibition of neutrophil adherence, through decrease in related production of free radicals that disrupts integrity of stomach mucosa and decrease in vascular permeability as compared to Indomethacin group. The results of the present study further indicates the role of 5-LOX metabolites in NSAIDs induced gastro inflammation and suggests that Montelukast and Curcumin counteracted the Indomethacin induced gastropathy by a combination of its effect on inhibition of neutrophil adherence and through decrease in related production of free radicals that disrupts integrity of stomach mucosa. **Conclusions:** Experimental data clearly demonstrated the role of LTs was indomethacin induced gastric ulcers. However, inhibition of ulcerogenic events by Montelukast and Curcumin is suggestive of an important balance between COX and 5-LOX products.

## 1. Introduction

Gastrointestinal damage induced by non-steroidal anti-inflammatory drugs (NSAIDs) is one of the most frequent adverse effects. These changes are presumably due to inhibition of Cyclooxygenase (COX), which is responsible for conversion of arachidonic acid to prostaglandin (PGs) that are needed to maintain the integrity of gastric mucosa[1]. It is well recognized that patients taking indomethacin or other NSAIDs for inflammatory disorders such as rheumatoid arthritis and ankylosing spondylitis

are likely to develop gastrointestinal mucosal injury. A number of mechanisms have been proposed to explain the mucosal damage induced by NSAIDs, most of which relate to the ability of these drugs to attenuate the synthesis of PGs[2]. However, there is an evidence that COX inhibition by NSAIDs diverting arachidonic acid metabolism to 5-lipoxygenase (5-LOX) pathway, suggests the possible role of leukotrienes (LTs) in vascular changes and mucosal damage associated with the use of NSAIDs. Thus, dual inhibitors of COX/LOX pathway, which would be gastro friendly was developed. However, role of LTs in NSAIDs induced gastropathy is debatable. Both supporting and opposing reports on the effect of 5-LOX inhibitor and leukotriene receptor antagonists (LTRA) against NSAIDs induced gastric damage are available[3]. Montelukast, a LTRA and curcumin, a dual inhibitor of COX/5-LOX have been reported to possess a potent anti-inflammatory effect

\*Corresponding author: Dr. Siva Reddy Challa, M.Pharm, Department of Pharmacology, KVSRR Siddhartha College of Pharmaceutical Sciences, Pinnamaneni Polyclinic Road, Siddhartha Nagar, Vijayawada-520010, Andhra Pradesh  
E-mail: [sivareddypharma@gmail.com](mailto:sivareddypharma@gmail.com)  
Mobile: 91+8008593009  
Telephone: 91+8662493346

and favorable gastro tolerability properties.

The present study was aimed to evaluate the effect of Montelukast and curcumin against gastric ulceration and inflammation in order to assess the role of LTs, if any, in NSAIDs induced gastro inflammation.

## 2. Materials and methods

### 2.1. Drugs and chemicals

Montelukast was obtained as a gift sample from Sun Pharmaceuticals Ltd (Ahmadabad, India). Curcumin was purchased from Sigma Chemical Company (St. Louis, USA). 2, 3, 5– triphenyl tetrazolium chloride was purchased from BDH chemicals Ltd (England). Thiopentone sodium was supplied by Abott Lab Ltd. (Ankleshwar, India). Evans blue was purchased from Sisco Research Laboratories Pvt Ltd (Mumbai, India). All other chemicals and reagents were used of analytical grade.

### 2.2. Animals

Albino Wistar rats (National Institute of Nutrition, Hyderabad, India), of either sex, weighing 200–250 g, were selected. Animals were maintained under standard laboratory conditions at  $(25 \pm 2)^\circ\text{C}$ , relative humidity  $(50 \pm 15)\%$  and normal photoperiod (12 h dark/12 h light). Commercial pellet diet (Rayon's Biotechnology Pvt Ltd, India) and water were provided *ad libitum*. The experimental protocol has been approved by the Institutional Animal Ethics Committee and by the Animal Regulatory Body of the Government (Regd. No. 993/a/06/CPCSEA).

### 2.3. Experimental design

The rats were randomly divided into 4 groups with 6 each. Group I: treated with indomethacin (100 mg/kg *p.o.*). Group II, treated with 0.1% Tween 80 solution + indomethacin (100 mg/kg, *p.o.*). Group 3 was treated with Montelukast (10 mg/kg, *p.o.*) + indomethacin (100 mg/kg, *p.o.*). Group 4, treated with Curcumin (100 mg/kg, *p.o.*) + Indomethacin (100 mg/kg, *p.o.*) were given. After 4 h of fasting indomethacin was given orally to all 4 groups. Montelukast and Curcumin were administered orally in 0.1% Tween 80 solution 30 min prior to oral indomethacin to group 3 and group 4 respectively, and control group received 0.1% Tween solution.

### 2.5. Visual gastric lesions and gastric lesion score

Ulcers were induced by a single oral dose of indomethacin, 100 mg/kg b.w., dissolving in distilled water administered after 4 h fasting of the rats. After 4 h of

indomethacin administration, all animals were sacrificed and stomachs were excised along its greater curvature. After rinsing with normal saline, the mucosas were examined for the presence of petechiae or frank hemorrhage lesions. Lesions were scored according to their length (a score of 5 for lesions with length between 1 and 3 mm; a score of 10 for lesions greater than 3 mm). The sums of total scores were used for comparison<sup>[4]</sup>. All treatment groups were coded to prevent measurement bias.

### 2.6. Determination of malondialdehyde (MDA) levels in gastric tissues

MDA levels in the gastric tissue were measured by the method developed by Ohkawa *et al.*<sup>[5]</sup> Lipid peroxidation is estimated in terms of TBAR species using MDA as standard.

About 1 mL of homogenized gastric tissue in 2 mL of normal saline was mixed with 24 % TCA and centrifuged at 2 000 rpm for 20 min. To 2 mL of protein-free supernatant, 1mL of fresh TBA 0.67% reagent was added, mixed thoroughly and heated at  $95^\circ\text{C}$  for 1 h in a water-bath. The suspension was then cooled to room temperature, centrifuged at 2 000 rpm for 10 min and the pink colored supernatant was taken for spectroscopic measurement at 532 nm for the assay of MDA. Lipid peroxide was expressed in terms of nm of MDA/gram of gastric tissue.

### 2.7. Determination of percent neutrophil adhesion

After 60 min of indomethacin administration blood was collected from retro-orbital plexus into heparinised vials and analyzed for total leukocyte count. The differential leukocyte count was performed by fixing the blood samples and staining the LTs and percent neutrophils in each sample was determined. After the initial counts, blood samples were incubated with 80 mg/ml of nylon fibers for 10 mins at  $37^\circ\text{C}$ . The incubated blood samples were again analyzed for total leukocyte count and differential leukocyte count<sup>[6]</sup>.

The product of total leukocyte count and percent neutrophils gave the neutrophil index of blood sample. Percent neutrophil adhesion was calculated from the following formula<sup>[6]</sup>:

$$\text{Neutrophil adhesion (\%)} = (\text{Nlu} - \text{Nlt})/\text{Nlu}$$

Where,

Nlu = Neutrophil index of untreated blood sample; and

Nlt = Neutrophil index of treated blood sample.

### 2.8. Determination of vascular permeability

The ventral sides of the animals were shaved. Five ml/kg of a 1% solution of Evan's blue was injected intravenously. One hour later the animals were dosed with the test compound

orally or intraperitoneally with the vehicle. Thirty minutes later, the animals were briefly anaesthetized with ether and compound 48/80 was injected intracutaneously at 3 sites both at left and ventral side. Ninety minutes after the injection of compound 48/80, the animals were sacrificed by ether anaesthesia[7]. The abdominal skin was removed and the dye was extracted.

### 2.9. Method for the extraction of extravasated dye in the skin

A piece of the skin containing extravasated dye was soaked overnight in a Stoppard glass tube containing 1 mL of 1 N KOH at 37°C. Then, 9 mL of mixed solution (5:13) of 0.6 N H<sub>3</sub>PO<sub>4</sub> and acetone is added to the tube. The tube is shaken vigorously for a few seconds and centrifuged at 3 000 rpm for 15 mins. Absorbance of supernatant is measured at 620 nm[8].

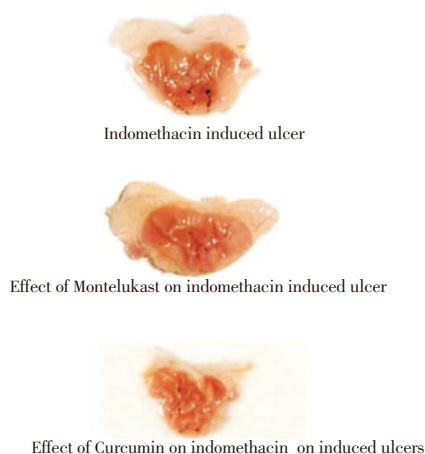
### 2.10. Statistical analysis

The results are expressed as mean  $\pm$  SD. Differences in all the parameters were determined by factorial one-way analysis of variance. Individual groups were compared using Tukey's test. Data were considered significant when  $P < 0.05$ . Statistical analysis was performed using Graph Pad Prism software (version 5).

## 3. Results

### 3.1. Visual gastric lesions

Indomethacin produced significant number of gastric lesions 4 h after dosing. Montelukast and curcumin caused significant ( $P < 0.05$ ) reduction in gastric lesion score as compared to control group. ( $P < 0.05$ ) (Figure 1).



**Figure 1.** Effect of Montelukast and curcumin on indomethacin induced gastric ulcers

### 3.2. Effect of Montelukast and curcumin on gastric lesion score

The gastric lesion score was  $43.25 \pm 4.63$  and  $42.00 \pm 1.90$  for control group and vehicle control, respectively. Pretreatment with Montelukast and curcumin significantly ( $P < 0.001$ ) reduced the generation of gastric lesion to  $21.00 \pm 4.00$  and  $25.63 \pm 2.45$ , respectively as compared indomethacin group (Table 1).

### 3.3 Effect of Montelukast and curcumin on induced percent neutrophil adhesion

In another study, 1 h after oral administration of indomethacin, blood samples were collected and neutrophil adhesion test was performed. Indomethacin induced a significant ( $P < 0.05$ ) adherence of neutrophils when compared to control group. Pretreatment with Montelukast and Curcumin significantly ( $P < 0.001$  and  $P < 0.001$ , respectively) reduced neutrophil adherence (Table 1).

### 3.4. Measurement of lipid peroxides as TBARS

The level of TBAR substances (index of lipid peroxidation) of gastric mucosa was  $16.23 \pm 0.13$  ng/mg of gastric tissue in indomethacin group, compared to  $10.63 \pm 0.22$  ng/mg of gastric tissue in control group. Pretreatment with Montelukast and curcumin significantly ( $P < 0.001$  and  $P < 0.001$ , respectively) reduced the generation of TBARS to  $13.41 \pm 0.42$  ng/mg and  $14.78 \pm 0.16$  ng/mg of gastric tissue, respectively as compared to indomethacin group (Table 1).

### 3.5. Vascular Permeability Study

The vascularity of the skin derived from Evan's blue administration was assessed after acute administration of indomethacin and pretreatment with Montelukast and curcumin. Indomethacin resulted in significant ( $P < 0.001$ ) increase in vascularity index when compared to control group. Montelukast and curcumin significantly ( $P < 0.05$  and  $P < 0.001$ , respectively) reversed indomethacin (100 mg/kg) induced vascular permeability (Table 1).

**Table 1**

Consolidated table of the data includes Visual gastric lesion score, neutrophil adhesion, Tissue MDA levels and vascularity index.

Groups	Visual Gastric score	Neutrophil adhesion(%)	Tissue MDA (nm/g)	Vascularity Index
Control	$43.25 \pm 4.63$	$23.03 \pm 1.62$	$16.23 \pm 0.13$	$0.026 \pm 0.001$
Vehicle control	$42.00 \pm 1.90$	$24.11 \pm 1.30$	$15.60 \pm 0.34$	$0.027 \pm 0.002$
Montelukast	$21.00 \pm 4.0$ ***	$8.95 \pm 1.65$ ***	$13.41 \pm 0.17$ ***	$0.019 \pm 0.000$ *
Curcumin	$25.63 \pm 2.45$ **	$10.23 \pm 1.59$ ***	$13.79 \pm 0.35$ ***	$0.015 \pm 0.001$ ***

\*:  $P < 0.05$ , \*\*:  $P < 0.01$ ; \*\*\*:  $P < 0.001$

## 4. Discussion

Long-term use of NSAIDs is the second most common cause of ulcers and the rate of NSAID induced ulcers is increasing, which presumably cause ulcers by disrupting mucosal defense and repair mechanisms.

### 4.1. Gastric lesion score

In the present study, NSAIDs, indomethacin, a non-selective COX inhibitor caused significant gastric ulcers by inhibiting the COX enzyme and thereby, reducing the synthesis of PGs. Inhibition of PGs synthesis can exert injurious actions on the gastric and duodenal mucosa as it abrogates a number of prostaglandin dependent defense mechanisms.

Inhibition of COX decreases mucus and bicarbonate secretion, reduces mucosal blood flow, and causes vascular injury, leukocyte accumulation, and reduces cell turnover. All these factors contribute to the genesis of mucosal damage (Halter et al., 2001). In the present study, Montelukast and curcumin significantly reduced gastric lesion score. COX inhibition by NSAIDs diverts arachidonic acid metabolism to 5-LOX pathway, suggests the possible role of LTs in vascular changes and mucosal damage<sup>[9]</sup>. So, it indicates that Montelukast and curcumin may reduce gastric ulcers by inhibiting the production of LTs. In support, recent study reported that Montelukast has shown anti-secretory, anti-apoptotic effects on pyloric ligation and water immersion stress induced peptic ulcer in rats<sup>[10]</sup>. In another study, Tepoxalin, a COX/LOX dual inhibitor was reported to prevent gastrointestinal ulceration when given 30 min prior to indomethacin treatment<sup>[11]</sup>.

### 4.2. Percentage of neutrophil adhesion and lipid peroxidation

Neutrophils have been implicated as mediators of the epithelial cell and microvascular dysfunction associated with several models of gastrointestinal mucosal injury. The circulating activated neutrophils appeared to be important in the development of gastric erosions and changes in vascular integrity following NSAIDs gastropathy<sup>[12, 13]</sup>. Also, the role of neutrophil derived oxygen free radicals in NSAIDs induced disruption of gastric membrane integrity is documented<sup>[14]</sup>. Recent study reported the gastroprotective effect of leukotriene receptor blocker montelukast in alendronet-induced lesions of the rat gastric mucosa<sup>[14–17]</sup>.

In the present study, Montelukast and curcumin have significantly inhibited the indomethacin induced neutrophil adhesion and this thereby decreasing the gastric

ulceration<sup>[18–20]</sup>. This was clearly evident from the decreased gastric lesion score. This was also further supported by the study, Licofelone, a novel 5-LOX/COX-inhibitor, attenuates leukocyte rolling and adhesion on endothelium under flow<sup>[22]</sup>. In the present study, indomethacin caused significant increase in TBARs as compared to control. LTB<sub>4</sub> can also stimulate the release of reactive oxygen metabolites from neutrophils, which contributes significantly to the tissue injury associated with mucosal inflammation<sup>[23]</sup>. Montelukast and Curcumin significantly decreased the elevated levels of TBAR species. This is further supported by another study, Licofelone, significantly reduced increase in TBAR species<sup>[22]</sup>.

### 4.3. Vascular permeability

Our result is further supported by Drewe et al. (2001)<sup>[24]</sup> which enhances paracellular permeability and epithelial destruction<sup>[25]</sup>. Oxygen radicals (superoxide of a secondary radical) are involved in the intestinal vascular permeability changes induced by ischemia. A study by Blisklager *et al.* (2002)<sup>[26]</sup> showed that Ischemic injured tissues recovered to control levels of resistance within three hours where as tissues treated with Indomethacin failed to fully recover. Indomethacin caused significant increase in vascularity index as compared to control. Pretreatment with Licofelone, significantly reduced vascular permeability<sup>[27]</sup>. In accordance with the previous findings, the present study demonstrated that Montelukast and curcumin also attenuated increased vascularity in rats.

So, Montelukast and curcumin offers the gastroprotection by inhibition of neutrophil adhesion and hence reduced generation of free radicals and vascular permeability.

In support of our results, Rainsford (1987) studies revealed that the multifactorial basis of gastro-intestinal (GI) damage from NSAIDs includes effects of these drugs in producing microvascular injury. Increased 5-lipoxygenase (5-LOX) activity reflected in production in the gastric efferent circulation of leukotriene C<sub>4</sub> was shown in pigs given i.g. indomethacin. Blockade of 5-LOX activity by highly selective inhibitors of this enzyme inhibits production of both gastric and intestinal LT in rats and mice<sup>[11]</sup>.

The data strongly suggest that Montelukast and curcumin conferred gastro protection by inhibiting the indomethacin induced increase in 5-LOX effectors. The results of the present study further indicates the role of 5-LOX metabolites in gastro inflammation and suggests that Montelukast and curcumin counteract the gastropathy by a combination of its effect on inhibition of neutrophil adherence and through decrease in related production of free radicals that disrupts integrity of stomach mucosa. However, the role of LTs in the pathogenesis of NSAIDs induced gastrointestinal

damage is controversial. There are evidences both in support and contrary to this hypothesis. Various studies have demonstrated the amelioration of NSAIDs induced gastric irritant effect by selective 5-LOX inhibitor and dual inhibitors. Thus, inhibition of ulcerogenic events by Montelukast and curcumin is suggestive of an important balance between COX and 5-LOX products.

### Acknowledgement

We are grateful to the Sun Pharmaceuticals Ltd for providing the gift sample of Montelukast.

### Conflict of interest statement

Authors declare that there are no conflicts of interests.

### References

- [1] Gyires K. Gastric mucosal protection: from prostaglandins to gene-therapy. *Curr Med Chem* 2005; **12**(2): 203–215.
- [2] Lane ME, Kim MJ. Assessment and prevention of gastrointestinal toxicity of non-steroidal anti-inflammatory drugs. *J Pharm Pharmacol* 2006; **58**(10): 1295–1304.
- [3] Takeuchi K, Tanaka A, Hayashi Y, Yokota A. COX inhibition and NSAID-induced gastric damage—roles in various pathogenic events. *Curr Top Med Chem* 2005; **5**(5): 475–486.
- [4] Padi SS, Jain NK, Singh S, Kulkarni SK. Pharmacological profile of parecoxib: a novel, potent injectable selective cyclooxygenase-2 inhibitor. *Eur J Pharmacol* 2004; **491**(1): 69–76.
- [5] Ohkawa H, Ohishi N, Yagi K. Assay for lipid peroxides in animal tissue by thiobarbituric acid reaction. *Anal Biochem* 1979; **95**: 351–358.
- [6] Padi SS, Jain NK, Singh S, Kulkarni SK. Pharmacological profile of parecoxib: a novel, potent injectable selective cyclooxygenase-2 inhibitor. *Eur J Pharmacol* 2004; **491**(1): 69–76.
- [7] Bennet AJ, West GB. Measurement of the changes in vascular permeability in rat skin. *J Pharmacol Meth* 1978; **1**: 105–108.
- [8] Shionoya H, Ohtak S. A new simple method for extraction of extravasated dye in the skin. *Japan J Pharmacol* 1975; **103**(25): 103.
- [9] Rainsford KD. The effects of 5-lipoxygenase inhibitors and leukotriene antagonists on the development of gastric lesions induced by non steroidal anti-inflammatory drugs in mice. *Agents Actions* 1987; **21**: 316.
- [10] Arunachalam M, Shailja S. Anti-secretory, anti-oxidative and antiapoptotic effects of montelukast on pyloric ligation and water immersion stress induced peptic ulcer in rats. *Prostag leukotr ess* 2010; **83**(1): 55–60.
- [11] Kirchner T, Aparicio B, Argentieri DC, Lau CY, Ritchie DM. Effects of tepoxalin, a dual inhibitor of cyclooxygenase/5-lipoxygenase, on events associated with NSAID-induced gastrointestinal inflammation. *Prostag leukotr ess* 1997; **56**(6): 417–423.
- [12] Cuciureanu M, Caruntu ID, Kuchar M, Nechifor M. The influence of leukotriene receptors antagonists on experimentally induced ulcer in rats. *Rev Med Chir Soc Med Nat Iasi* 2008; **112**(3): 750–756.
- [13] Goodman L, Coles TB, Budsberg S. Leukotriene inhibition in small animal medicine. *J Vet Pharmacol and Ther* 2008; **31**: 387–398.
- [14] Bandyopadhyay D, Chattopadhyay A. Reactive oxygen species-induced gastric ulceration: protection by melatonin. *Curr Med Chem* 2006; **13**(10): 1187–1202.
- [15] Pages Ahmed N, Saeed ZI, Tariq M. Abdominal lymphadenopathy: An atypical presentation of enteric fever. *Asian Pac J Trop Biomed* 2012; **2**(5): 409–410.
- [16] Alsaimary AE, Abdulnbi HM, Laibi A, Jwad AR. The occurrence of *Helicobacter pylori* in hydatid liver disease. *Asian Pac J Trop Biomed* 2012; **2**(3): 233–234
- [17] PagesOkokon JE, Udoh AE, Frank SG, Amazu LU. Anti-inflammatory and analgesic activities of *Melanthera scandens*. *Asian Pac J Trop Biomed* 2012; **2**(2): 144–148
- [18] Mandade RJ, Sreenivas SA, Sakarkar DM, Choudhury A. Pharmacological effects of aqueous-ethanolic extract of *Hibiscus rosasinensis* on volume and acidity of stimulated gastric secretion. *Asian Pac J Trop Med* 2011; **4**(11): 883–888
- [19] Lan C, Sun XN, Dong LW, Huang BL, Yuan S, Wu K. The role of endotoxin in the pathogenesis of gastric mucosal damage in cirrhotic rats with portal hypertensive gastropathy. *Asian Pac J Trop Med* 2011; **4**(3): 212–214.
- [20] Sundar R, Rao L, Vasudevan G, Gowda PBC, Radhakrishna RN. Gastric cryptococcal infection as an initial presentation of AIDS: a rare case report. *Asian Pac J Trop Med* 2011; **4**(1): 79–80.
- [21] Goksel S, Caner K, Sale C, Esra C, Gul AL. Gastroprotective effect of leukotriene receptor blocker montelukast in alendronet-induced lesions of the rat gastric mucosa. *Prostag leukotr ess* 2005; **72**: 1–11
- [22] Ulbrich H, Soehnlein O, Xie X, Eriksson EE, Lindbom L, Albrecht W, Laufer S, Dannhardt G. Licofelone, a novel 5-LOX/COX-inhibitor, attenuates leukocyte rolling and adhesion on endothelium under flow. *Biochem Pharmacol* 2005; **70**(1): 30–36.
- [23] Santos CL, Souza MH, Gomes AS, Lemos HP, Santos AA, Cunha FQ et al. Sildenafil prevents indomethacin-induced gastropathy in rats: role of leukocyte adherence and gastric blood flow. *Br J Pharmacol* 2005; **146**(4): 481–486.
- [24] Drewe J, Beglinger C, Fricker G. Effect of ischemia on intestinal permeability of lipopolysaccharides. *Eur J Clin Invest* 2001; **31**: 138–144.
- [25] Fink MP. Intestinal epithelial hyper permeability: update on the pathogenesis of gut mucosal barrier dysfunction in critical illness. *Curr Opin Crit Care* 2003; **9**: 143–151.
- [26] Bliklager AT, Zimmer DN, Young KM, Campbell NB, Little D, Argenzio RA. Recovery of ischemic-injured porcine ileum: evidence for a contributory role of COX-1 and COX-2. *Gut* 2002; **50**: 615–623.
- [27] Singh VP, Chandrasekhar SP, Shrinivas KK. Effect of licofelone against NSAIDs-induced gastrointestinal ulceration and inflammation. *India J Exp Biol* 2005; **43**: 247–253.