

THE PROPERTIES OF MECHANICAL INSTABILITY ON LUMBAR SPINE AT THE ADJACENT SEGMENT AFTER RIGID FIXATION

Ahmet KARAKASLI^a, Berivan CECEN^{b*}, Mehmet ERDURAN^c, Orcun TAYLAN^b, Onur HAPA^c, Hasan HAVITCIOGLU^{b,c}

MD, a Department of Orthopedics and Traumatology, Tire State Hospital, 35900 Izmir, Turkiye
b Department of Biomechanics, Health Sciences Institute, Dokuz Eylul University, 35340 Izmir, Turkiye
MD, c Department of Orthopedics and Traumatology, Dokuz Eylul University, 35340 Izmir, Turkiye

ABSTRACT

Posterior spinal interbodyfusion (PLIF) and rigid fixation have been frequently undertaken for lumbar arthrodesis. The effect of rigid fixation pedicle screw instrumentation on biomechanical behaviors of adjacent segment instability has not been well documented. Seventeen fresh-frozen lamb lumbar spines (Sacrum-T12) were used for current study. The biomechanical tests were performed by using the axial compression testing machine. The axial compression was applied to all amputee legs with the loading speed of 5 mm/min (max. 400 Newton). A specially designed fixture used to increase moment up to 8400 Nmm generated through the axial movement of the actuator was applied to each specimen to achieve the flexion and extension motions, axial neutral compression, right and left bending, respectively were applied to specimens. All specimens were tested intact and after implantation with posterior pedicle screws and rod fixation. During testing, intervertebral displacement at decompression levels L5-S1 was recorded continuously by extensometer. While preparing test specimen, suitable gauge marks (diamond mark for high accuracy) were selected for the test specimen. Gauge marks were applied to test specimen with pins due to sliding surface of test specimen. Gauge marks were attached to L5 and S1 to measure the (superior-inferior) and (anterior-posterior) displacement. At implanted rod spines of adjacent segment (S1-L5) group, neutral vertical (superior-inferior) displacements were showed lower data than transverse (anterior-posterior) displacements. When we checked the statistical data, there was a numerical difference and there was significant change between the intact spine and adjacent segment of axial compression and extension position. Also we compare data of the transverse (anterior-posterior) displacements at the lumbar spine after rigid fixation of adjacent segment; adjacent segment was greater than intact spine. Rigid fixation of lumbar spine alters range of motion (ROM) of adjacent segment level. Therefore abnormal stress and hyper mobility on adjacent segment causes spinal instability, which can develop facet joint degeneration and low back pain.

Key Words: Adjacent segment instability, Lumbar spine, Facet joint, Inter vertebral disc

1. INTRODUCTION

Instrumented lumbar spinal fusion is a common surgical procedure indication comprises degenerative disorders and lytic spondilolisthesis (Xu et al., 2006; Hongo et al., 2009; Yu et al., 2011). As a vertebral body become anteriorly displaced due to an isthmus defect, spondilolytic spondilolisthesis and degenerative disorders vertebral stenosis have been created vertebral stenosis created. This situation cause mechanical induced low back pain or it compresses the neural structures and causes neurological symptoms (Schulte et al., 2007; Yu et al., 2011; Ekman et al., 2009; Choi et al., 2009; Siewe et al., 2011). When instability of lumbar spine causes persistent pain or neurological impairment, it is usually treated using spinal fusion among the various fusion techniques (PLIF, TLIF, ALIF) with instrumentation

is one option. The alteration of biomechanical condition at the junction of fused and mobile segment is believed to lead to accelerated degeneration in adjacent motion segments. Adjacent segment disease has been reported to occur in up to 35% patients after spinal fusion (Xu et al., 2006; Axelsson et al., 2007). A higher fusion rate can be obtained in cases in which rigid fixation is performed using a pedicle screw as compared with that for the cases in which internal fixation was not performed and the postoperative period of using of a brace can be shortened with fixation using a pedicle screw (Schulte et al., 2007; Sim et al., 2010; Axelsson et al., 2007). The initial good results following a posterior spinal fusion degrade over time as adjacent mobile segments proximal and distal to the fusion degenerate over time (Axelsson et al., 2007). After an arthrodesis at L4-L5 (the most common level) of fusion the incidence of adjacent disc disease require additional surgery has been estimated to be 15% (Xu et al., 2006; Yu et al., 2011; Ekman et al., 2009). Progression of the free mobile segment next to spinal fusion is referred to as adjacent segment disease and includes disc degeneration, facet joint hypertrophy, spinal stenosis an even acquired spondilolisthesis (Sim et al., 2010). The etiology of the degeneration adjacent segment to fusion has not been clarified. There are two theories about adjacent segment disease; first theory, In-vitro the investigation has suggested that fusion increase the intradiscal pressure of adjacent segment and also that situation of relative hyper mobility is induced. Both observations would mean increased load on the segment. Another theory that claims that degeneration of the adjacent segment rather reflects the natural degenerative course of the aging disc (Xu et al., 2006; Schulte et al., 2007; Siewe et al., 2011; Cho et al., 2009; Phillips et al., 2009; Sim et al., 2010). Facet joint mobilization and intradiscal pressure measurements have been studied in detail after the long level fixation and fusion; however, there have been a few studies related with adjacent segment instability and amount of displacement.

The aim of this study is to identify the mechanical behavior and instability of adjacent segment after rigid fixation.

2. METHODS

2.1. Specimens

Seventeen fresh-frozen lamb spines were used for this study. The ages of lambs were between six to twelve months. The specimens didn't have any macroscopic and radiological diseases. Sacrum from T12 parts of the spine of each specimen was dissected. All of the specimens were frozen and thawed before tests during one night at room temperature. All of the specimens were potted with cement at the T12 vertebra and sacrum part.

2.2. The Biomechanical Tests

The current study was conducted in two groups. In the first group the specimens were tested intact spine and second implanted rod spine. The specimens were mounted for biomechanical test machine. A specially designed fixture used to increase moment up to 8400 Nmm generated through the axial movement of the actuator was applied to each specimen to achieve the flexion and extension motions, axial neutral compression, right and left bending, respectively were applied to specimens (Chung Tai et. al) In the axial neutral position 400N were applied to axial neutral compression (AG-I 10 kN, Shimadzu, Japanese) (Fig. 1).

Firstly the specimens that intact spine were tested. Second the transpedicular screws (30 x 4.5mm, mono axial Titanium screws) were implanted to the L5, L4, L3 vertebrae and fixed with two rods (6 x 100 mm, Titanium, Tpsan-Tibbi Aletler San. A.S.). During testing, intervertebral displacement at decompression levels L5-S1 was recorded continuously by extensometer (Non-contact Video Extensometer DVE-101/201, Shimadzu, Japanese). While preparing test specimen, suitable gauge marks (diamond mark for high accuracy) were selected for the test specimen. Gauge marks were applied to test specimen with pins due to sliding surface of test specimen. Gauge marks were attached to L5 and S1 to measure the (superior-inferior) and (anterior-posterior) displacement. The two non-contact cameras grabbed image of the gauge marks. Personal computer processed the gray-scale image and measured displacement of the gauge marks of each camera image to measure the elongation of the test specimens. The gauge mark displacement on the CCD screen was converted into actual displacement. The elongation between two gauge marks was calculated by subtracting the lower mark displacement from the upper mark displacement. The displacements values were recorded on personal computer connected with test machine and two non-contact cameras. The data of displacement was evaluated with Mann-Whitney U test using SPSS 11.0 for Windows.




Fig. 1. The axial compression tests which were applied to specimens; axial neutral compression (a), flexion (b) extension (c), right (d) and left bending positions (e), respectively.

3. RESULTS

Results of the positions at neutral vertical displacements are presented in Fig. 2 and transverse displacements are shown in Fig. 3.

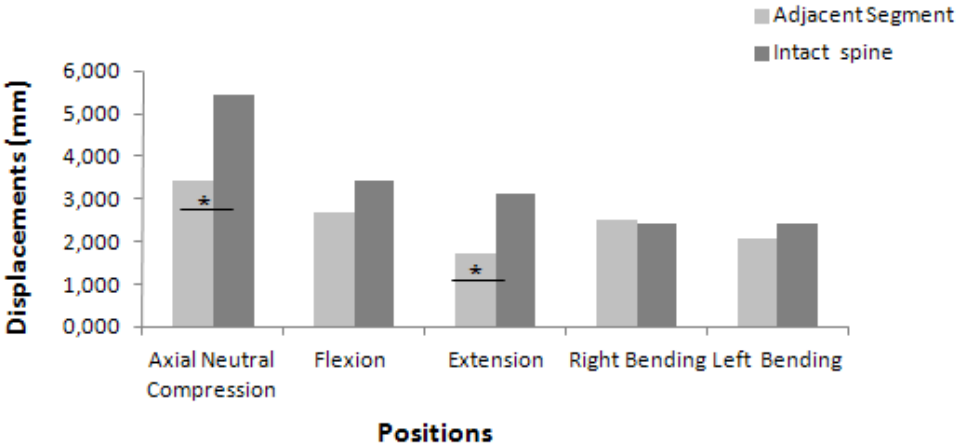


Fig. 5. Bar graph of neutral vertical displacements.

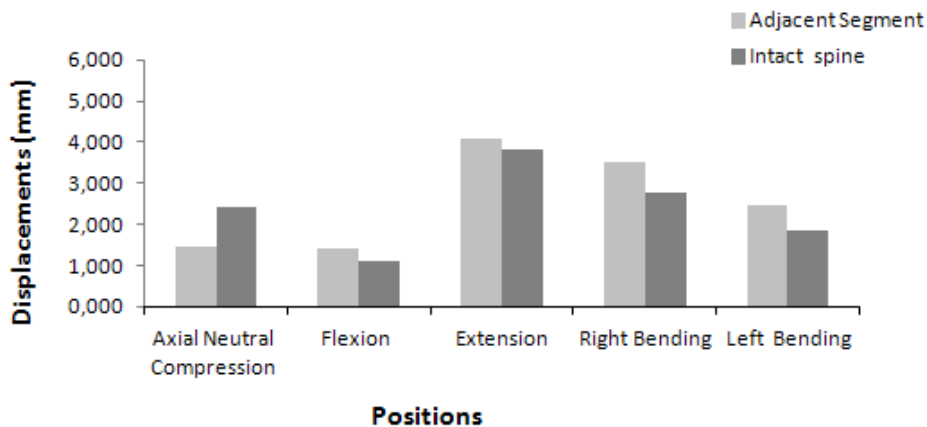


Fig. 6. Bar graph of transverse displacements. Serial-1 Adjacent Segment, Serial-2 Intact spine.

When the neutral vertical displacement values of the positions were compared, generally intact spine groups have demonstrated the highest displacement. There was a significant difference between intact spine and adjacent segment of axial neutral compression position ($p < 0.027$). Intact spine have exhibited the highest displacement and statistically difference at extension ($p < 0.015$). The intact spine group was showed the highest displacement at flexion but there was no significant difference between these groups. When the intact spine and the implanted spine groups were compared at left bending, there was not any statistically significant difference between these groups as well.

It was found that in transverse direction there was an increase in adjacent segment. Adjacent segment was showed highest displacement at flexion but it was insignificant. The data was confirmed that extension, right and left bending positions were again not significantly difference between adjacent segment and intact spine.

When the stiffness values of the groups were compared in vertical direction, left bending have demonstrated the highest value in intact spine group. On the other hand, right bending has demonstrated the highest stiffness values among all positions in adjacent segment.

It was noted that the stiffness of the transverse values at the intact spine groups was showed highest value in left bending position. Right bending stiffness seemed lowest value among all models. Axial neutral compression had higher stiffness values than the others in adjacent segment.

4. DISCUSSION

Much rigid instrumentation are in use including pedicle screw systems which have gained broad support because of greater initial stability, increased fusion rates, decreased requirements for external immobilization and an earlier return to work (Xu et al., 2006; Schulte et al., 2007; Ekman et al., 2009; Choi et al., 2009; Sim et al., 2010; Axelsson et al., 2007; Cheh et al., 2007). The absence of controlled motion is also considered to be one of contributing factors in implant failure and outcome adjacent segment disease (Xu et al., 2006; Hongo et al., 2009; Schulte et al., 2007; Yu et al., 2011; Ekman et al., 2009; Phillips et al., 2009; Sim et al., 2010). Biomechanical studies using both human and animal specimens demonstrated increase the mobility, mechanical stress and intradiscal pressure in motion adjacent segments to arthrodesis (Xu et al., 2006; Hongo et al., 2009; Phillips et al., 2009; Tai et al., 2008). This study reports on the displacement changes of the lamp spine to examine the adjacent segments instability and rigid fixation. Under laboratory conditions, we used lamb lumbar spines instead of human cadaveric spines. Although physiological structure such as spinal alignment number of lumbar segments of the lamb spines are somewhat different from those of human cadaveric spines, animal spines are most convenient choice to perform the experiment with long spinal segment for the reason that human cadaveric spines cannot be accessed (Xu et al., 2006; Hoogendoorn et al., 2008).

Several researchers have measured intradiscal pressure (IDP) or laminar strain for adjacent segments after rigid fixation, fusion and indirectly evaluated the load transmission through both the anterior and posterior spinal columns

IDP increase to some degree at adjacent segments for all directions except extension extension in all specimens (Sim et al., 2010). In current study adjacent segment instability was investigated biomechanically both intact spine and adjacent segment. Rigid fixation of larger spine segment provides a more complete anatomic scenario through which both inter-level and intra-level, inter action of the hard and soft tissues on motion can be considered (Phillips et al., 2009). Increase neutral zone around on the neutral zone posture of spine after destabilization procedure would put increase demand on musculature to provide the stability needed during activities of daily living. Increased muscle force would in turn increase stresses in the spinal components and may contribute to pain. After fusion increased motion at mobile levels is required to achieve the predetermined global ROM end point (Phillips et al., 2009; O'Leary et al., 2005).

Although there was a significant variation in intact spine and adjacent segment of axial neutral compression position, the displacements changes in intact spine were observed more than other groups in vertical. Additionally, there was statistically significant increase in displacement at extension. Our testing protocol constantly tested the intact spine followed by the L5, L4, L3 vertebrae. The other determination was there was an increase between intact spine and adjacent segment of axial neutral compression position.

In current experiment, adjacent segment displacements and instability were analyzed under axial compression in the intact and in spines following rigid fixation. Adjacent data in vertical displacement showed similar results. Our data indicated significant differences in vertical axial neutral compression displacements evaluated for adjacent and intact spine. Furthermore, the measurements showed significant differences in the vertical extension displacements assessed for adjacent and intact spine.

We noticed insignificant difference in the transverse displacement in axial neutral compression of the adjacent segment. We also examined the effect of the stiffness values in specimens. In the study presented here, in vertical, the average stiffness data assessed that left bending positions in intact spine, right bending positions in adjacent segment showed higher values. In transverse, the results indicated an increase in stiffness of left bending positions in intact spine group.

The present results illustrated that in the intact spine displacements were higher than the rigid fixation spine displacements because the rigid fixation increased the stability of spine. The rigid fixation was decreased the ROM of spine. Therefore, excessive motion and degeneration was occurred in adjacent segment of facet joints. Loss of segmental motion by instrumentation was compensated for by somewhat increase ROM in all directions at adjacent segments that is not only adjacent levels but also at other lumbar motion segments (Sim et al., 2010). Dynamic transpedicular instrumentation with the aims of avoiding stress shielding of graft and avoiding excessive stress on the bone and adjacent disc was able to share load with spinal segment without increasing angular ranges of motion. But optimal rigidity of instrumentation is still unclear clinically (Xu et al., 2006; Niemeyer et al., 2006). Dynamic fixation is able to reduce facet joint force at that level in contrast disc loads are not significantly reduced by such an implant (Zander et al., 2006). The maintenance of stability of the lumbar spine during movements therefore requires the coordinated movements of multiple motion segments (Niemeyer et al., 2006). In current study, in all positions, at adjacent segment, transverse displacements were greater than the intact spine displacements. This detected the anterior-posterior instability on the adjacent segment.

5. CONCLUSION

We conclude that, adjacent segment intervertebral transverse displacement of the lumbar spine, following rigid fixation was significantly greater than that of lumbar spine in intact. In all positions, transverse displacements have higher values except in axial neutral position. There is a numerical difference and a significant change between the intact spine and implanted spine in axial compression and extension position. Moreover, abnormal stress on adjacent segment may cause spinal instability. Rigid fixation of lumbar spine alters adjacent segment level ROM, depending on number of instrumented levels. After rigid fixation of spine on adjacent segment of the transverse and rotational instability has been outcome. In conclusion, the increased strain in the adjacent segment facet joint and the disc may develop facet joint degeneration and low back pain. Understanding the changing instability in the adjacent segment, and preventing the facet joint hyper mobility will shed light on the development of new dynamic implant designs and help us to avoid adjacent segment disease.

6. REFERENCES

1. Axelsson, P., Johnsson, R., Strömqvist, B., 2007. Adjacent segment hypermobility after lumbar spine fusion: no association with progressive degeneration of the segment 5 years after surgery. *Acta Orthopaedica* 78, 834-839.
2. Cardoso, M.J., Dmitriev, A.E., Helgeson, M., Lehman, R.A., Kuklo, T.R., Rosner, M.K., 2008. Does superior-segment facet violation or laminectomy destabilize the adjacent level in lumbar transpedicular fixation? An in vitro human cadaveric assessment. *Spine* 15, 2868-2873.
3. Cheh, G., Bridwell, K.H., Lenke, L.G., Buchowski, J.M., Daubs, M.D., Kim, Y., Baldus, C., 2007. Adjacent segment disease following lumbar/thoracolumbar fusion with pedicle screw instrumentation: a minimum 5-year follow-up. *Spine* 15, 2253-2257.
4. Choi, Y.S., 2009. Pathophysiology of Degenerative Disc disease. *Asian spine journal* 3, 39-44.
5. Lee, K.K., Teo, E.C., Qiu, T.X., Yang, K., 2004. Effect of facetectomy on lumbar spinal stability under sagittal plane loadings. *Spine* 29, 1624-1631.
6. Choi, Y., Kim, K., So, K., 2009. Adjacent segment instability after treatment with a Graf ligament at minimum 8 years' followup. *Clinical Orthopaedics and Related Research* 467, 1740-1746.
7. Ekman, P., Möller, H., Shalabi, A., Yu, Y.X., Hedlund, R., 2009. A prospective randomised study on the long-term effect of lumbar fusion on adjacent disc degeneration. *European Spine Journal* 18, 1175-1186.
8. Gay, R.E., Ilharreborde, B., Zhao, K., Boumediene, E., An, K.N., 2008. The effect of loading rate and degeneration on neutral region motion in human cadaveric lumbar motion segments. *Clinical Biomechanics* 23, 1-7.
9. Gédet, P., Haschtmann, D., Thistlethwaite, P.A., Ferguson, S.J., 2009. Comparative biomechanical investigation of a modular dynamic lumbar stabilization system and the Dynesys system. *European Spine Journal* 18, 1504-1511.
10. Hongo, M., Gay, R.E., Zhao, K.D., Ilharreborde, B., Huddleston, P.M., Berglund, L.J., An, K.N., 2009. Junction kinematics between proximal mobile and distal fused lumbar segments: biomechanical analysis of pedicle and hook constructs. *The Spine Journal* 9, 846-853.
11. Hoogendoorn, R.J., Helder, M.N., Wuisman, P.I., Bank, R.A., Everts, V.E., Smit, T.H., 2008. Adjacent segment degeneration: observations in a goat spinal fusion study. *Spine* 33, 1337-1343.
12. Jegapragasan, M., Cook, D.J., Gladowski, D.A., Kanter, A.S., Cheng, B.C., 2011. Characterization of articulation of the lumbar facets in the human cadaveric spine using a facet-based coordinate system. *The Spine Journal* 11, 340-346.
13. Niemeyer, T.K., Koriller, M., Claes, L., Kettler, A., Werner, K., Wilke, H.J., 2006. In vitro study of biomechanical behavior of anterior and transforaminal lumbar interbody instrumentation techniques. *Neurosurgery* 59, 1271-1276.
14. O'Leary, P., Nicolakis, M., Lorenz, M.A., Voronov, L.I., Zindrick, M.R., Ghanayem, A., Havey, R.M., Carandang, G., Sartori, M., Gaitanis, I.N., Fronczak, S., Patwardhan, A.G., 2005. Response of Charité total disc replacement under physiologic loads: prosthesis component motion patterns. *The Spine Journal* 5, 590-599.
15. Phillips, F.M., Tzermiadianos, M.N., Voronov, L.I., Havey, R.M., Carandang, G., Renner, S.M., Rosler, D.M., Ochoa, J.A., Patwardhan, A.G., 2009. Effect of the Total Facet Arthroplasty System after complete laminectomy-facetectomy on the biomechanics of implanted and adjacent segments. *The Spine Journal* 9, 96-102.
16. Rousseau, M.A., Bradford, D.S., Hadi, T.M., Pedersen, K.L., Jeffery, C., 2006. The instant axis of rotation influences facet forces at L5/S1 during flexion/extension and lateral bending. *European Spine Journal* 15, 299-307.
17. Schollum, M.L., Robertson, P.A., Broom, N.D., 2010. How age influences unravelling morphology of annular lamellae - a study of interfibre cohesivity in the lumbar disc. *Journal of Anatomy* 216, 310-319.
18. Schulte, T.L., Leistra, F., Bullmann, V., Osada, N., Vieth, V., Marquardt, B., Lerner, T., Liljenqvist, U., Hackenberg, L., 2007. Disc height reduction in adjacent segments and clinical outcome 10 years after lumbar 360 degrees fusion. *European Spine Journal* 6, 2152-2158.
19. Siewe, J., Otto, C., Knoell, P., Koriller, M., Stein, G., Kaulhausen, T., Eysel, P., Zarghooni, K., Franklin, J., Sobottke, R., 2011. Comparison of standard fusion with a "topping off" system in lumbar spine surgery: a protocol for a randomized controlled trial. *BMC Musculoskeletal Disorders* 18, 239.
20. Sim, H.B., Murovic, J.A., Cho, B.Y., Lim, T.J., Park, J., 2010. Biomechanical comparison of single-level posterior versus transforaminal lumbar interbody fusions with bilateral pedicle screw fixation: segmental stability and the effects on adjacent motion segments. *Journal of Neurosurgery: Spine* 12, 700-708.
21. Tai, C.L., Hsieh, P.H., Chen, W.P., Chen, L.H., Chen, W.J., Lai, P.L., 2008. Biomechanical comparison of lumbar spine instability between laminectomy and bilateral laminotomy for spinal stenosis syndrome - an experimental study in porcine model. *BMC Musculoskeletal Disorders* 11, 84.

22. Yu, C.H., Lee, J.E., Yang, J.J., Chang, B.S., Lee, C.K., Chang. 2011. Adjacent segment Degeneration after Single-Level PLIF: Comparison between Spondylolytic Spondylolisthesis, Degenerative spondylolisthesis and Spinal Stenosis. *Asian Spinal Journal* 5, 82-90
23. Xu, H.Z., Wang, X.Y., Chi, Y.L., Zhu, Q.A., Lin, Y., Huang, Q.S., Dai, L.Y., 2006. Biomechanical evaluation of a dynamic pedicle screw fixation device. *Clinical Biomechanics* 21, 330-336.
24. Zander, T., Rohlmann, A., Burra, N.K., Bergmann, G., 2006. Effect of a posterior dynamic implant adjacent to a rigid spinal fixator. *Clinical Biomechanics* 21, 767-774.