

The Study of Different Presentations of Breast Lumps in Radiographic Imaging

Shalini Saraswat¹, Amit Kumar²

¹Assistant Professor, Department of Radiodiagnosis, Teerthanker Mahaveer Medical College & Research Centre, Moradabad - 24400, U.P., India,

²Assistant Professor, Department of ENT, Teerthanker Mahaveer Medical College & Research Centre, Moradabad - 24400, U.P., India

Introduction: Breast USG is an established and accurate tool for the primary evaluation of breast lumps and pathology. It also compliments X- ray mammography in further evaluation and characterization of breast masses and thus avoids surgeries in benign breast diseases and pathology. **Method:** For USG examination of the breast lumps, a linear-array transducer of 5-7 MHz frequency is required with a good resolution machine. **Results:** We present a pictorial essay on the role of USG in evaluation and characterization of various breast lumps and pathology. **Conclusion:** Breast sonography considerably improves the visualization and evaluation of lumps in mammographically radiodense breasts and helpful in the characterization of it, either as solid or cystic lesion. It also improves the specificity of X-ray mammography when used as an adjunct to it. It is also helpful in guiding FNAC/biopsy from the breast masses.

Keywords: Breast, Sono-mammography, ultrasound, X- ray mammography

INTRODUCTION

Because of increased incidence of breast cancer in females, a breast lump may worry both the patient and clinician. Breast ultrasonography is appropriate investigation for the initial evaluation of a female younger than 30 years with a palpable breast lump and also helpful in the evaluation of X- ray mammographic abnormalities i.e. masses, focal asymmetric densities, areas of architectural distortion and palpable abnormalities not seen mammographically.¹ Additional imaging with MRI and FNAC/biopsy might be needed in the cases, for the confirmation of the sonographic diagnosis.

USG guided core-needle biopsy (CNB) is a frequently performed and accurate alternative to stereotactic/excisional biopsy.^{2,3} USG may be guided aspiration of symptomatic cysts, complicated cysts, and possible abscesses are also readily performed.⁴

USG feature analysis of breast masses continues to improve,⁵ though interobserver variability continues to be a problem, in avoiding biopsy.^{6,7} An illustrated Breast Imaging Reporting and Data System (BI-RADS) ultrasonographic lexicon⁸ helpful in improving observer performance.

METHOD

For USG examination of the breast lumps, a linear-array transducer of 5-7 MHz frequency is required with a

good resolution machine. The patient is scanned in the supine position for the inner part of the breast and then in the contralateral posterior oblique position with the ipsilateral raised arm, for the axilla and upper outer quadrants.

RESULT & DISCUSSION

Normal anatomy [Figure 1]

On sonography, normal breast parenchyma has alternate hyperechoic and hypo echoic layers:

Skin – hyperechoic

Subcutaneous fat – hypoechoic

Fibroglandular breast parenchyma – hyper echoic

Retromammary fat – hypo echoic

Muscle (Pectoralis major)– hyperechoic

Cooper's ligaments are echogenic bands that suspend the breast from the superficial layer of the fascia.

Ductal ectasia [Figure 2]

Duct ectasia most commonly affects the ducts in Retroareolar region but may also involve the smaller peripheral ducts. USG shows tubular anechoic dilated structures or ducts filled with echoes (Figure 2), and there may be associated nipple discharge. Duct ectasia

Corresponding Author:

Dr. Shalini Saraswat, Assistant Professor, Department of Radiodiagnosis, Teerthanker Mahaveer Medical College & Research Centre, Moradabad, U.P., India. E-mail: drshalinisaraswat@yahoo.com

usually present as a painful breast and/or palpable lump, or the condition may be asymptomatic and apparent only at imaging as an incidental finding.

Breast cysts [Figure 3a, 3b]

Simple cysts in the breast are anechoic lesions on USG, with a thin echogenic capsule, posterior acoustic enhancement, and thin clear edge shadow. Complex cysts are heterogeneous, have internal echoes, septations, thick irregular walls or internal solid components. Complex cysts, especially those with internal solid components, may turn out to be malignant on histopathology.⁹

Intraductal and intracystic papillomas/papillary carcinoma [Figure 4a, 4b]

Breast Papillomas may be intracystic (Figure 4a) or intraductal (Figure 4b). They could not be differentiated from papillary carcinomas only by sonographic features. FNAC/biopsy of the lesions is required to rule out malignancy. Intraductal papillomas/carcinomas usually present with a complaint of bloody nipple discharge.

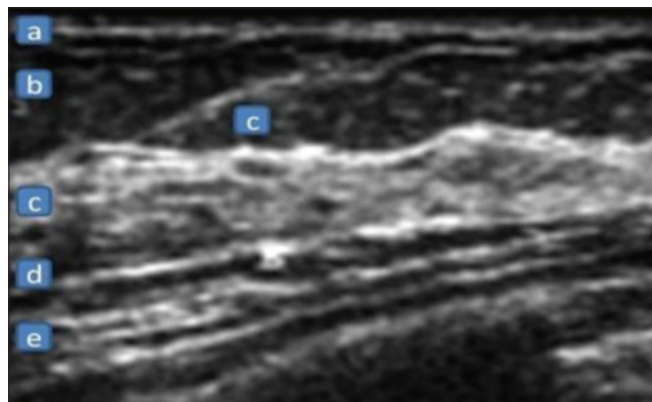


Figure 1 : Normal breast anatomy on USG. a) hyperechoic- skin, b) hypoechoic-subcutaneous fat, c) hyperechoic- fibroglanular breast parenchyma, d) hypoechoic- retromammary fat, e) hyperechoic -muscle. c) Cooper's ligaments

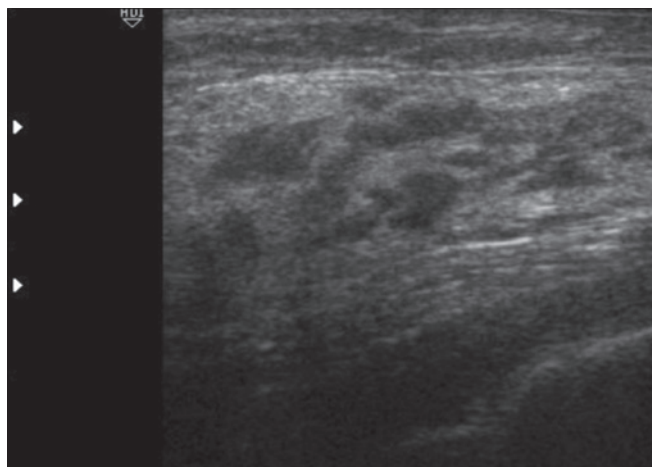


Figure 2: Breast USG shows dilated ducts in Retroareolar region

Fibroadenoma [Figure 5]

Fibroadenoma is the most common benign breast tumor in young females. It may increase in size during adolescence, pregnancy and lactation. It may also present with atrophic changes after menopause. On USG, it is usually homogenous, well-defined, hypoechoic, oval, wider than tall, with/without posterior acoustic enhancement. The calcifications within a fibroadenoma are usually of the coarse variety and may show posterior acoustic shadowing on USG. Fibroadenomas with complex features on USG have a higher incidence of transformation into breast cancer.¹⁰

Juvenile breast fibroadenoma [Figure 6]

Juvenile fibroadenoma is the most frequent benign tumor of the breast in adolescents and young females, tends to be between 11 and 18 years, which coincides with the puberty onset.^{11,12}

Giant breast fibroadenoma [Figure 7]

Giant fibroadenoma is defined to be more than 5 cm in diameter, and/or weighing more than 500gm.¹² Giant fibroadenomas are rare breast lesions, representing less than 4% of all fibroadenomas. They present as a rapidly growing, well circumscribed, unilateral breast mass lesion. Its close differential is Cystosarcoma Phyllodes Tumors on USG.

Intramammary/axillary lymph nodes [Figure 8a, 8b]

Lymph nodes are most commonly located in the upper outer quadrant, primarily in the Axillary tail region. Hilar notch and fatty hilum should be visible to make the diagnosis. Normal intramammary lymph nodes are usually less than

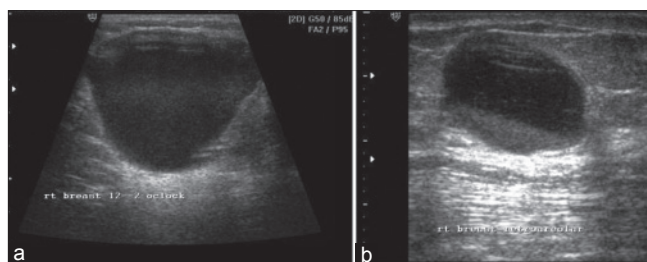


Figure 3a, 3b: Breast USG shows a simple anechoic cystic lesion with posterior acoustic enhancement (Fig.3a). Another complex cystic lesion with dense internal echoes, layered in dependent region (Fig.3b)

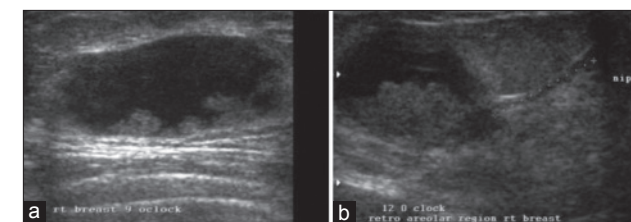


Figure 4a, 4b: Intracystic (Fig.4a) and intraductal papillomas (Fig.4b). Breast USG in a 46-year-old female with a palpable lump and bloody right nipple discharge shows a complex cystic lesion with an intracystic, solid echogenic polypoidal mass (Fig.4a). Another patient with similar complaints shows a dilated duct in retroareolar region along with intraductal polypoidal solid echogenic component (Fig.4b)

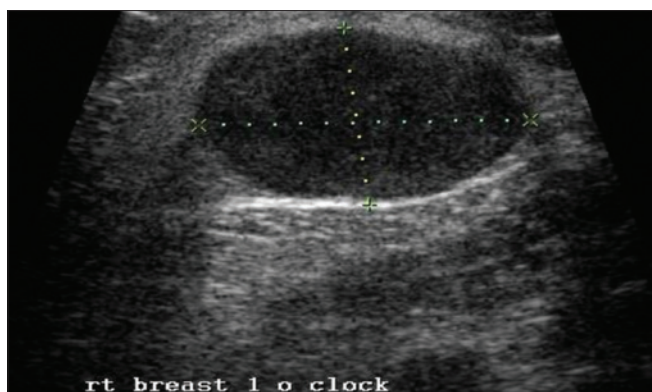


Figure 5: Fibroadenoma. Breast USG in a 29-year-old female shows a homogenous, hypoechoic, gently macrolobulated lesion with edge shadow, suggestive of a fibroadenoma

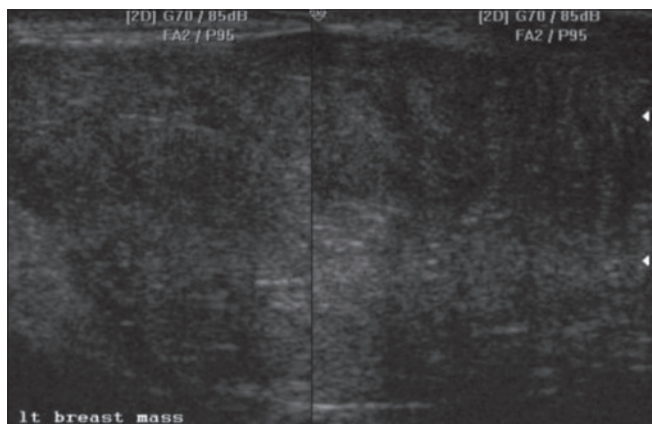


Figure 6: 13-year-old girl with unilateral breast hypertrophy. On USG, a large, well-defined hypoechoic mass lesion is noted in left breast

1 cm in short axis diameter along with loss of fatty hilum and increased vascularity on color Doppler.

Galactoceles [Figure 9]

It usually occurs during lactation or shortly after stoppage of breast-feeding, caused by an obstruction in milk duct. At X-ray mammography, galactoceles may present as an indeterminate mass, unless fat-fluid level is seen within. Even if the fat-fluid level is not present, a benign pathology can be considered, by the identification of fat within the lesion. US may show a complex mass. The diagnosis should make on the basis of the clinical history and aspiration.

Cystosarcoma phyllodes tumors [Figure 10]

They are fibroepithelial stromal tumors of the breast. These can be either benign or malignant. They are rapidly growing tumors, with high recurrence rate and may even metastasize in rare cases. On USG, these are usually benign-looking lesions with internal clefts, cystic spaces and are moderately vascular on Doppler.¹³

Breast abscess [Figure 11a, 11b, 11c]

Breast abscess is usually present clinically with high-grade fever, painful breast lump, skin erythema and edema. Acute

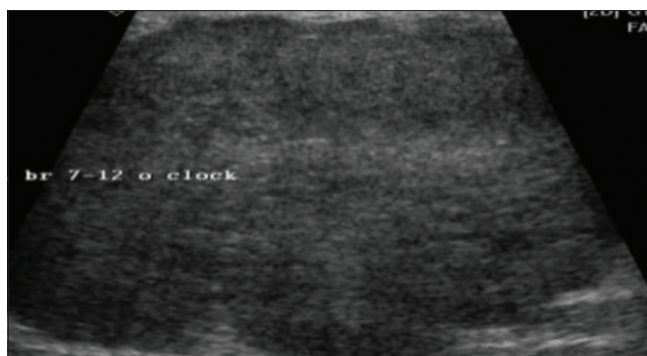


Figure 7: Giant fibroadenoma: A large, well circumscribed, lobulated, hypoechoic mass lesion in right breast at 7 – 12 o'clock position measuring approximately, 10.2 x 8.4cm

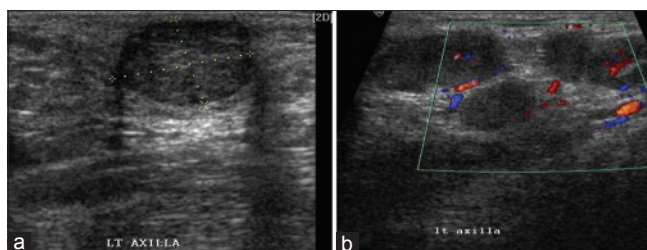


Figure 8a, 8b: Breast USG in a 40 years female shows an enlarged intramammary hypoechoic lymph node in left axillary tail region with loss of fatty hilum (Fig.8a). Another patient with left axillary lymphadenopathy shows multiple enlarged hypoechoic lymph nodes on USG with increased vascularity on color Doppler (Fig. 8b)

abscesses may occur during lactation, due to blockage in the duct with secondary milk collection and infection.

Breast edema [Figure 12]

Edema of the breast can occur in inflammatory/infective conditions, following surgery or radiation. It may also occur due to venous or lymphatic obstruction as present in neoplastic etiology.

Lipomas [Figure 13]

These are fatty tumors in the breast parenchyma and vary in appearance on USG, ranging from uniformly echogenic to heterogeneous or completely anechoic lesions e.g.: Oil cysts.

Hamartomas or fibroadenolipomas [Figure 14]

These are fat-containing, benign tumors in the breast parenchyma along with varying amount of fibrous tissue. They are heterogeneous in nature with mixed internal hypoechoic and echogenic areas.

Fat necrosis in breast [Figure 15]

Fat necrosis is a common entity. However, may pose a difficulty to clinicians and sonologist, because of its different manifestations and USG appearances. Fat necrosis may result from accidental trauma, after surgery or radiation therapy.¹⁴ When symptomatic, fat necrosis typically presents as a small, painless, ill-defined breast mass. The sonographic features are varied and depend on the degree

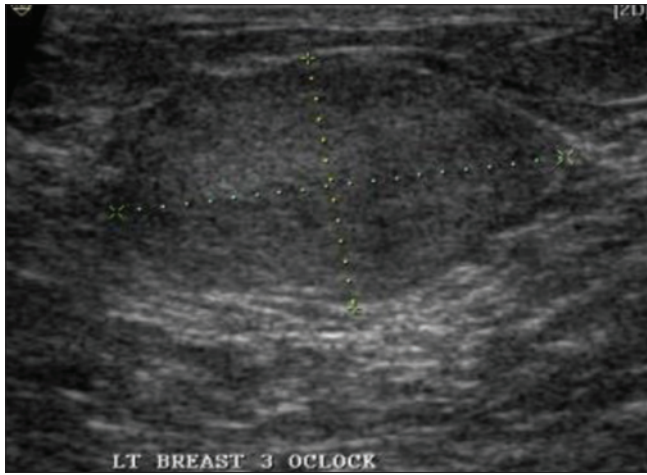


Figure 9: Breast USG in a young woman with a palpable left breast mass who had recently given birth, shows a well defined lesion filled with uniform echoes in left breast at 3 o'clock position. On aspiration, this yielded a milky substance

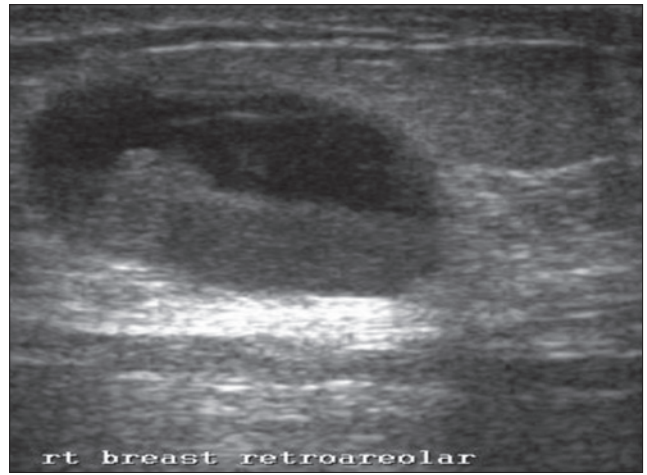


Figure (11c): Breast sonogram obtained in 45-year-old female shows mobile debris with a fluid-debris level in a symptomatic cyst in right breast retroareolar region

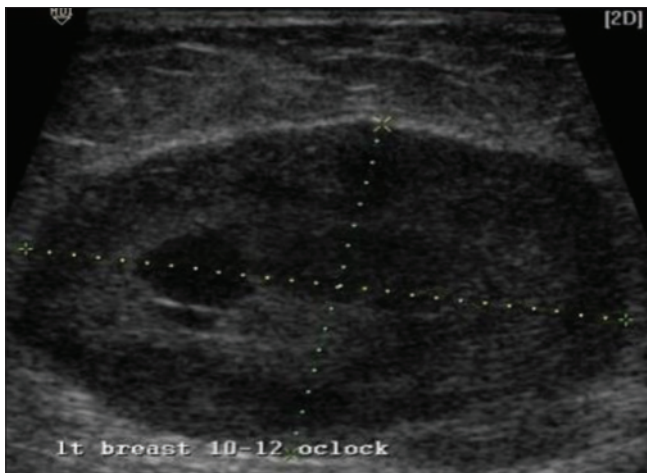


Figure10: Breast USG in a 38 years old female with complaint of rapidly growing lump in the left breast, shows a well-defined, lobulated, hypoechoic, encapsulated, moderately vascular mass with multiple internal linear, anechoic "clefts" and cystic spaces

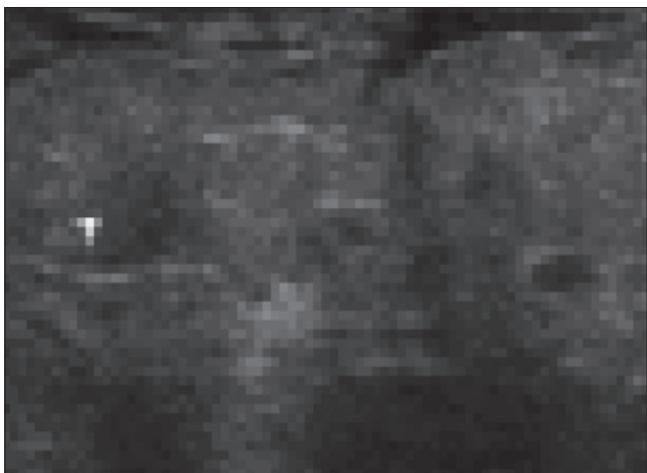


Figure 12: Breast edema: USG shows skin thickening and subcutaneous edema with a generalized increased echogenicity of the breast parenchyma

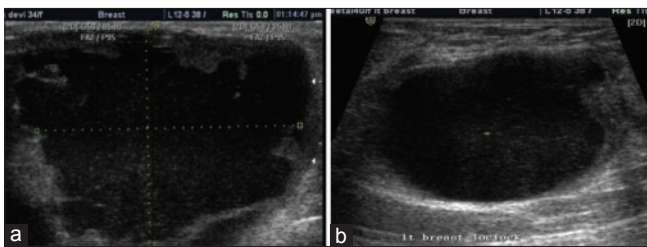


Figure (11a, 11b): Abscesses. Breast USG (Fig.11a) in a 34-years old lactating woman with high-grade fever, present with a painful breast lump, skin erythema and edema, shows a large heterogeneously anechoic, predominantly cystic lesion with mobile internal debris and adjacent inflammatory breast tissue with increased vascularity on Doppler. Another 40 years old, non- lactating female with similar complaints and USG findings (Fig.11b)

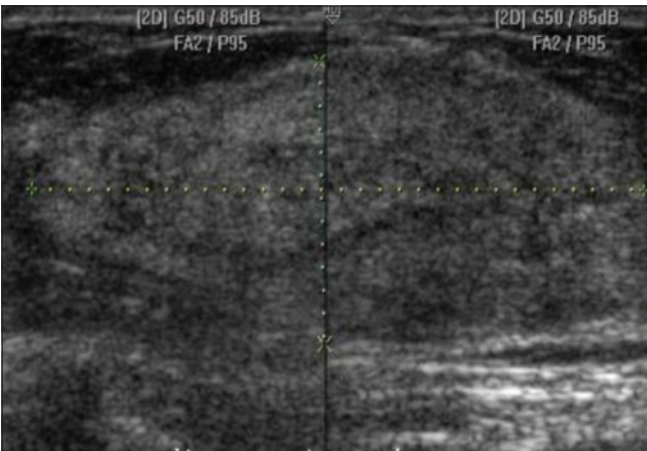


Figure 13: Lipomas: Breast USG shows a well-defined, ellipsoid, predominantly echogenic mass lesion seen superficially in the left breast parenchyma, suggestive of a lipoma

of fibrosis in lesion. It may present as a solid echogenic mass, a complex mass with mural nodules or internal echogenic bands, an anechoic mass with posterior enhancement or shadowing, as an isoechoic mass.¹⁴ The margins range

from well circumscribed to indistinct to spiculated. A mass with echogenic internal bands that shift in orientation with

changes in patient position has been described as a specific sonographic indicator of fat necrosis. It is thought that these echogenic bands represent the interface between the fat and the serous-hemorrhagic components of fat necrosis.

Invasive ductal carcinoma [Figure 16]

These are usually irregular, ill-defined, microlobulated heterogeneous lesions with infiltrative, spiculated margins. They may be taller than wide in dimensions. Microcalcifications may be usually seen as echogenic foci within the lesion.

Invasive lobular carcinoma [Figure 17]

Invasive lobular carcinoma is the second most common breast malignancy and may be seen in elderly females. Lesions have variable appearances on X-ray mammography and sonomammography so can be missed on X-ray mammography. On USG, tumor appearances are ranging from findings similar to ductal carcinomas to areas of

architectural distortion. Some of these tumors may even not be visualized on USG.¹⁵

Medullary carcinoma [Figure 18]

These are uncommon breast malignancy. On sonography, it shows benign feature like homogenous, hypochoic lesion with well-circumscribed margins with/without posterior acoustic enhancement.

Mucinous carcinoma [Figure 19]

It is also uncommon breast malignancy. The mucin contents of the tumor may be echogenic on USG.

Recurrent breast cancer [Figure 20]

Recurrence of tumor may occur even years after treatment of the primary breast malignancy. So follow up is required in all the cases. It may occur in the residual breast tissue or even in the chest wall in cases of complete mastectomy. It may metastasize even after primary surgical resection of the tumor.

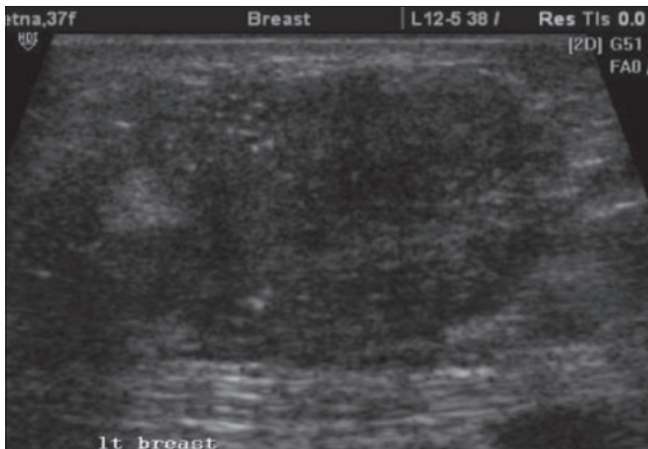


Figure 14: Hamartoma/ fibroadenolipoma: Breast USG in a 37 years old patient shows a soft, well-circumscribed tumor with mixed internal echogenic and hypochoic areas and focal calcifications

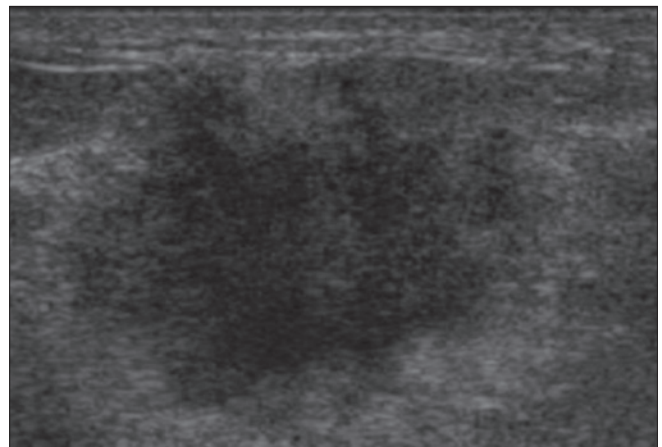


Figure 16: Invasive ductal carcinoma. Breast USG shows an ill-defined, irregular, microlobulated heterogeneously hypochoic lesion with infiltrative and spiculated margins

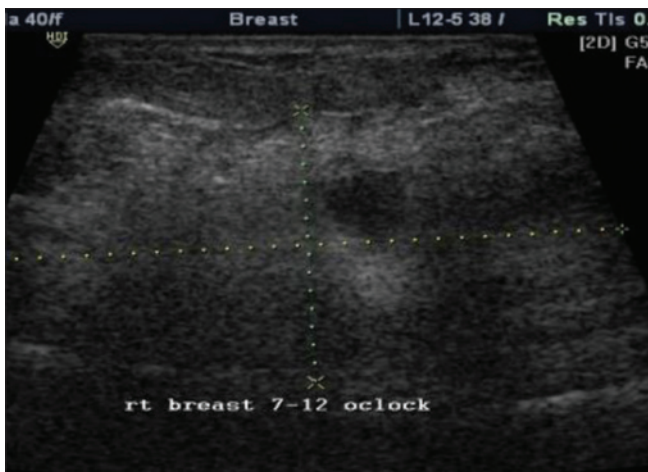


Figure 15: Fat necrosis in breast: An ill defined echogenic mass lesion with internal hypochoic areas, in a patient presented with a history of right breast trauma

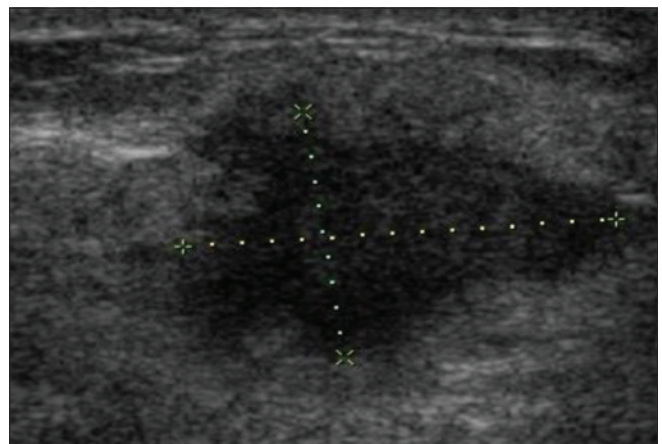


Figure 17: Invasive lobular carcinoma. 71 years old female presented with a complaint of a palpable lump in the right breast. USG shows a large, ill-defined, heterogeneous, hypochoic lesion with area of architectural distortion

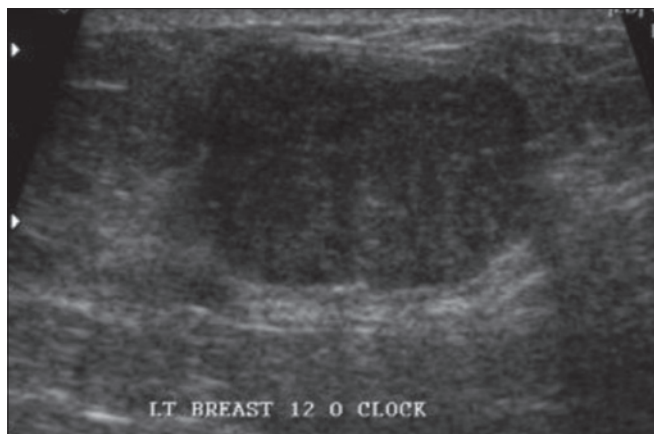

Figure 18: Medullary carcinoma. Breast USG shows a hypoechoic, well-circumscribed mass with posterior enhancement in left breast at 12 o'clock position

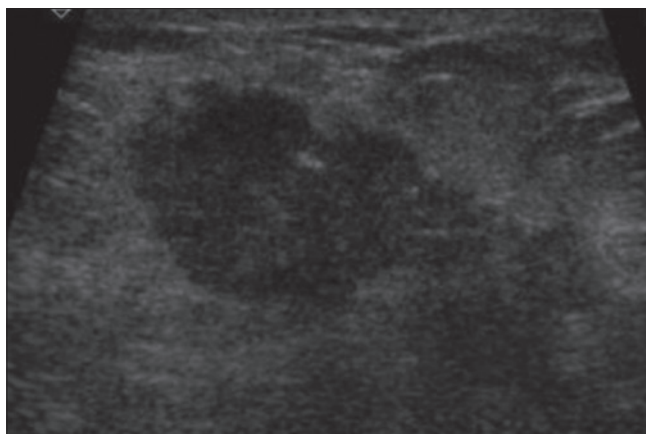


Figure 20: Recurrent breast carcinoma. 48 years old patient with a history of left mastectomy for a malignant mass, present with a palpable lump on the left chest wall after 3 years of surgery, USG reveals an irregular, microlobulated, taller-than-wide mass lesion on chest wall suggestive of tumor recurrence

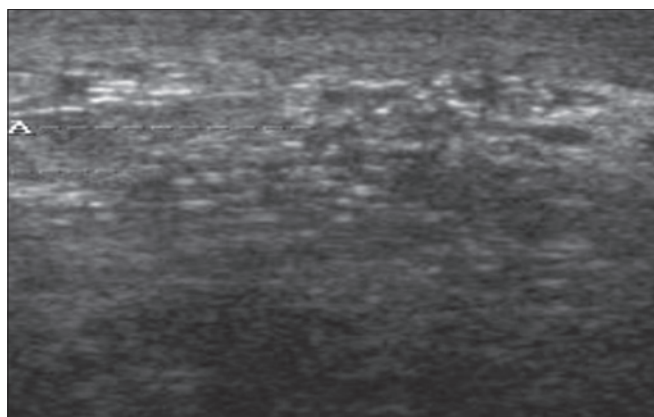


Figure 19: Mucinous carcinoma. Breast USG shows an ill defined lesion with echogenic internal contents

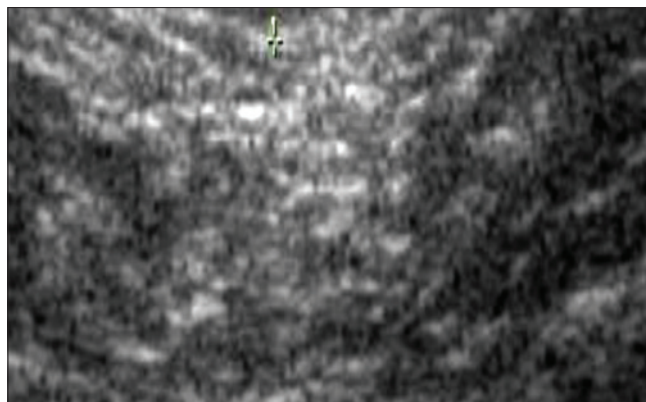


Figure 21: Gynecomastia. In this male patient, breast USG shows an ill-defined, hypoechoic area of fibroglandular parenchyma with fatty tissues

Gynecomastia [Figure 21]

Gynecomastia is more common in the male breast than malignancy. Usually it presents as palpable lump or asymmetry in the breast region. It is seen as a hypoechoic lesion in retroareolar region, similar to fibroglandular breast tissue of the female breast.

Male breast cancer [Figure 22]

About 1% of all breast cancers occur in the male patient. If there is the presence of any lesion within male breast tissue on USG, histopathology is must as incidence of malignancy is high in male breast lesions. Sonography findings are similar as of female breast cancer.

CONCLUSION

Breast sonography considerably improves the visualization and evaluation of lumps in mammographically radiodense breasts and helpful in the characterization of it, either as solid or cystic lesion. It also improves the specificity of X-ray mammography when used as an adjunct to it.

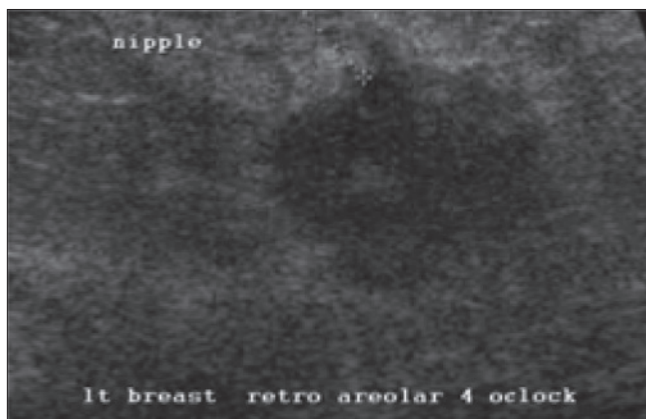


Figure 22: Male breast cancer. In a 60-year-old male patient with a palpable hard lump in the left breast USG reveals an irregular, hypoechoic mass lesion with multiple spiculations in retroareolar region

REFERENCES

1. Bassett LW. Imaging of breast masses. *Radiol Clin North Am* 2000; 38:669-691.
2. Parker SH, Jobe WE, Dennis MA, et al. US-guided automated large-core breast biopsy. *Radiology* 1993; 187:507-511.

3. Liberman L, Feng TL, Dershaw DD, et al. US-guided core breast biopsy: Use and cost- effectiveness. *Radiology* 1998;208: 717-723.
4. Pisano ED, Fajardo LL, Caudry DJ, et al. Fine-needle aspiration biopsy of nonpalpable breast lesions in a multicenter clinical trial: Results from the radiologic diagnostic oncology group V. *Radiology* 2001;219:785-792.
5. Stavros AT, Thickman D, Rapp CL, et al. Solid breast nodules: Use of sonography to distinguish between benign and malignant lesions. *Radiology* 1995;196:123-134.
6. Baker JA, Kornguth PJ, Soo MS, et al. Sonography of solid breast lesions: Observer variability of lesion description and assessment. *AJR Am J Roentgenol* 1999;172:1621-1625.
7. Rahbar G, Sie AC, Hansen GC, et al. Benign versus malignant solid breast masses: US differentiation. *Radiology* 1999;213: 889-894.
8. Mendelson EB, Berg WA, Merritt CR. Toward a standardized breast ultrasound lexicon, BI-RADS: Ultrasound. *Semin Roentgenol* 2001; 36:217-225.
9. Berg WA, Campassi CI, Ioffe OB. Cystic lesions of the breast: Sonographic-pathologic correlation. *Radiology* 2003;227:183-91.
10. Sklair-Levy M, Sella T, Alweiss T, et al. Incidence and management of complex fibroadenomas. *AJR Am J Roentgenol* 2008;190:214-8.
11. Davis S, Wallace A. A 19 year old with complete androgen insensitivity syndrome and juvenile fibroadenoma of the breast. *Breast J* 2001;7:430-3.
12. Wechselberger G, Schoeller T, Piza-Katzer H. Juvenile fibroadenoma of the breast Surgery 2002;132:106-7.
13. Bassett LW. Imaging of breast masses. *Radiol Clin North Am* 2000;38:669-91.
14. Hogge JP, Robinson RE, Magnant CM, et al. The mammographic spectrum of fat necrosis of the breast. *RadioGraphics* 1995; 15:1347-1356.
15. Butler RS, Venta LA, Wiley EL, et al. Sonographic evaluation of infiltrating lobular carcinoma. *AJR Am J Roentgenol* 1999; 172:325-30.

How to cite this article: Saraswat S, Kumar A. The study of different presentations of breast lumps in radiographic imaging. *Acta Medica International* 2014;1(1):45-51.

Source of Support: Nil, **Conflict of Interest:** None declared.